

Bilateral sternalis muscles

Ahmed F. Ibrahim, MSc, MD, Saeed A. Makarem, MSc, PhD, Hassem H. Darwish, MBBCh.

ABSTRACT

Bilateral sternalis muscles were observed during dissection of the thoraco-abdominal region of a male cadaver. A full description of the muscles, as well as their attachments and innervations were reported. A brief review of the existing literature, regarding the nomenclature, incidence, attachments, innervations and clinical relevance of the sternalis muscle, is also presented.

Neurosciences 2005; Vol. 10 (2): 171-173

The importance of continuing to record and discuss anatomical anomalies was addressed recently¹ in light of technical advances and interventional methods of diagnosis and treatment. The sternalis muscle is a small supernumerary muscle located in the anterior thoracic region, superficial to the sternum and the sternocostal fascicles of the pectoralis major muscle.² In the literature, sternalis muscle is called "a normal anatomic variant"³ and "a well-known variation",⁴ although in most textbooks of anatomy, it is insufficiently mentioned. Yet, clinicians are surprisingly unaware of this common variation. As a result of uncertainties in interpreting the images, Bradley et al⁵ performed exploratory surgery of a female case who presented with an irregular mass on mammography. The mass was found to be the sternalis muscle. A radiographic report⁶ highlighted the diagnostic dilemma posed by a sternalis muscle in the detection of breast cancer and directed the attention of radiologists to be familiar with the muscle and its variety of appearances to avoid confusion with malignant lesions.

The present study reported a new appearance of bilateral asymmetric sternalis. The information available concerning the muscle is also reviewed.

Case Report. A well defined sternalis muscle (**Figures 1 & 2**) was found, bilaterally, during dissection of the thoraco-abdominal region of a male cadaver in the Department of Anatomy, College of Medicine, King Saud University, Riyadh, Kingdom of Saudi Arabia. Both muscles were covered by superficial fascia, located superficial to the corresponding sternocostal portion of pectoralis major and separated from it by pectoral fascia. The left sternalis was 19 cm long and 3 cm wide at its broadest part. Its upper end formed a tendon continuous with that of the sternal head of left sternocleidomastoid muscle. The muscle is fusiform in shape. Its fibers were arranged superficially and nearly perpendicular to the fibers of pectoralis major. It extended medially to cover the left half of the sternum. Its lower end formed a small aponeurosis, 4 cm long, attached to the left external oblique muscle. The right muscle was formed of 2 fusiform bellies. The medial belly was 7 cm long and 0.6 cm wide. Its upper end was tendinous and originated together with the fibers of the sternocostal portion of the right pectoralis major muscle, at the level of the third costal cartilage. The lateral belly was 7 cm long and 0.4 cm wide. It was a fleshy belly that merged upward with the fibers of

From the Department of Anatomy, College of Medicine, King Saud University, Riyadh, Kingdom of Saudi Arabia.

Received 25th August 2004. Accepted for publication in final form 31st October 2004.

Address correspondence and reprint request to: Dr. Ahmed F. Ibrahim, Assistant Professor of Anatomy, College of Medicine, King Saud University, PO Box 2925, Riyadh 11461, Kingdom of Saudi Arabia. Tel. +966 (1) 4671307. Fax +966 (1) 4671300. E-mail: ahmedfathala@hotmail.com

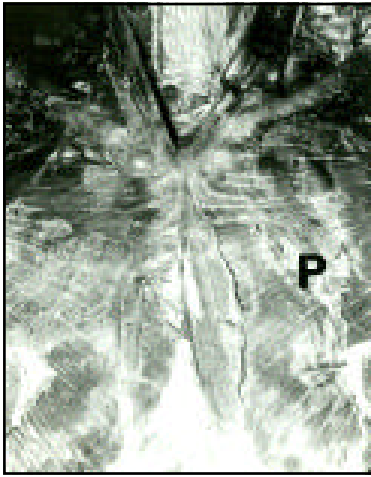


Figure 1 - Bilateral sternalis muscles. P - pectoralis major muscle.

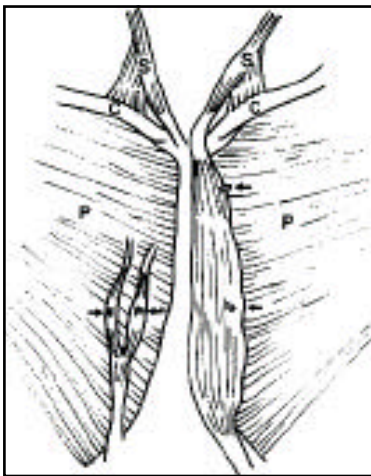


Figure 2 - A diagrammatic representation of bilateral sternalis muscles. The arrows point to the sites of innervation. C - clavicle, P - pectoralis major muscle, S - sternocleidomastoid muscle.

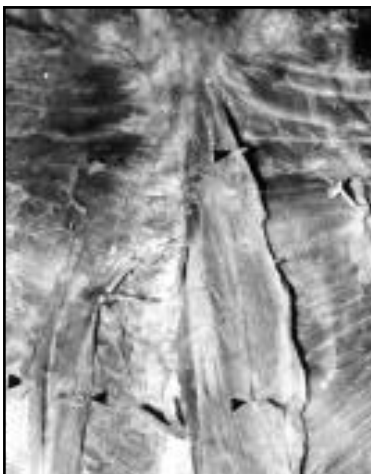

Figure 3 - Bilateral sternalis muscles. Note the sites of innervation of the muscles (arrows).

pectoralis major muscle, at the level of the third rib. The fibers of both bellies descended perpendicularly superficial to those of the right pectoralis major, 2 cm from midline. The 2 bellies fused to form a small aponeurosis, 5 cm long. Such aponeurosis was attached to the right external oblique muscle. The left muscle was innervated by the anterior cutaneous branches of the left second and fourth intercostal nerves. Both nerves penetrated the muscle close to its lateral border (Figure 3). The right muscle was innervated by the anterior cutaneous branch of the right fourth intercostal nerve that penetrated the middle of the medial belly. The lateral belly was innervated by a small branch arising from the right fourth intercostal nerve (Figure 3).

Discussion. The sternalis muscle (musculus sternalis) is the name usually given to the common anatomical variant, but the terms "episternalis, presternalis, sternalis brutorum, rectalis thoracis, rectus sterni, superficial rectus abdominis" have also been used in the literature.⁷ The sternalis has been reported in both males and females, and with a variable frequency in different ethnic groups. However, its incidence, in the literature available, ranged between 3-5% of the populations studied. Although it may be bilateral, the sternalis has, more commonly, a unilateral occurrence.³ It is located between the superficial fascia of the anterior thoracic region and the pectoral fascia. It may exist in the form of a small belly⁸ or may achieve a significant size, especially when it is accompanied by a partial or complete congenital absence of the pectoralis major muscle.⁹ Its upper end is either in direct continuity with the sternal head of the sternocleidomastoid muscle¹⁰ or pectoralis major muscle.² It may be also attached to the manubrium⁷ or to the body of the sternum.³ Its lower end is either attached to the pectoral fascia,^{2,7} to the costal cartilages¹⁰ or to the aponeurosis of the external oblique muscle.¹⁰ According to the literature, a well developed sternalis would resemble the left muscle reported in the present case.

A debate has ranged since the 17th century, particularly about the homology of sternalis. The muscle has been classified by various authors under 4 main headings; as being derived from pectoralis major muscle,¹¹ from rectus abdominis muscle,¹² from sternocleidomastoid muscle¹³ and from the panniculus carnosus.¹⁴ Since a nerve will supply the muscle to which it was originally destined at the beginning of its development,² an examination of the innervation patterns reported in the literature has narrowed the debate. Sternalis is either pectoralis major-derived with an innervation from pectoral nerves,^{11,15} or rectus-derived with an innervation from the intercostal nerves.^{2,7,9,10,16} The present report supported an origin from rectus abdominis muscle. Because of its particular location, it has been

suggested that contraction of the sternalis muscle can elevate the lower part of the chest wall,⁸ an action achieved by other muscles in those having no sternalis. Finally, sternalis muscle may be used as a pedicle flap or a flap with microvascular anastomosis in the plastic and reconstructive surgery of the head and neck.⁷

References

- Hicks J, Newell R. Supernumerary muscles in the pectoral and axillary region, and the nature of the axillary arches. *Clin Anat* 1997; 10: 211-212.
- Arraez-Aybar LA, Sobrado-Perez J, Merida-Velasco JR. Left muscular sternalis. *Clin Anat* 2003; 16: 350-354.
- Bailey PM, Tzarnas CD. The sternalis muscle: a normal finding encountered during breast surgery. *Plast Reconstr Surg* 1999; 103: 1189-1190.
- Kida MY, Izumi A, Tanaka S. Sternalis muscle: topic for debate. *Clin Anat* 2000; 13: 138-140.
- Bradley FM, Hoover HC, Hulka CA, Whitman GJ, McCarthy KA, Hall DA, et al. The sternalis muscle: an unusual normal finding seen on mammography. *AJR Am J Roentgenol* 1996; 166: 33-36.
- Murphy JS, Nokes SR. Radiological case of the month. Sternalis muscle. *J Ark Med Soc* 1996; 93: 55-56.
- Jelev L, Georgiev G, Surchev L. The sternalis muscle in the Bulgarian population: classification of sternales. *J Anat* 2001; 199: 359-363.
- Jeng H, Su SJ. The sternalis muscle: an uncommon anatomical variant among Taiwanese. *J Anat* 1998; 193: 287-288.
- Kitamura S, Yoshioka T, Kaneda M, Matsuoka K, Chen KL, Sakai A. [A case of the congenital partial defect of the pectoralis major--accompanied by the sternalis with enormous size] *Kaibogaku Zasshi* 1985; 60: 728-732.
- O'Neill MN, Folan-Curran J. Case report: bilateral sternalis with a bilateral pectoralis major anomaly. *J Anat* 1998; 193: 289-292.
- Kida MY, Kudoh H. Innervation of the sternalis muscle accompanied by congenital absence of the pectoralis major muscle. *Okajimas Folia Anat Jpn* 1991; 67: 449-455.
- Larsen WJ. *Human Embryology*. New York: Churchill Livingstone; 1997.
- Rao VS, Rao GRKH. The sternalis muscle. *J Anat Soc Ind* 1954; 3: 49-51.
- Shen CL, Chien CH, Lee SH. A Taiwanese with a pair of sternalis muscles. *Kaibogaku Zasshi* 1992; 67: 652-654.
- Gray H. *Anatomy of the Human Body*. 30th ed. Clemente CD, editor. Philadelphia: Lea and Febiger; 1985. p. 520.
- Saeed M, Murshid, KR, Rufai AA, Elsayed SE, Sadiq MS. Sternalis. An anatomic variant of chest wall musculature. *Saudi Med J* 2002; 23: 1214-1221.