

Neurogenic stunned myocardium following hemorrhagic cerebral contusion

Dirk Deleu, MD, FRCP, Marie-Anne Kettern, MD, Yolande Hanssens, PharmD, Suresh Kumar, MD, Khalid Salim, MD, Francisco Miyares, MD.

ABSTRACT

Neurogenic stunned myocardium (NSM) is a well-known complication of subarachnoid hemorrhage, but has been reported rarely in association with other central nervous system disorders. A case of NSM is described in a patient with hemorrhagic brain contusion associated with cerebral edema. An 18-year-old man was admitted with severe cranial trauma following a car roll-over. Six days after admission, he developed findings suggestive for NSM. The troponin T and creatine kinase-MB level were elevated and echocardiogram showed apical and inferoposterior hypokinesia and diffuse left ventricular akinesia with severely reduced ejection fraction (18%). Invasive measurements confirmed low cardiac output. His cardiac function resolved completely within 6 days after decompressive craniotomy. This case supports the presumed unifying role of the increased intracranial pressure, probably triggering a vigorous sympathetic outflow hyperactivity leading to NSM.

Neurosciences 2007; Vol. 12 (1): 65-67

From the Departments of Neurology (Deleu, Miyares), Anesthesiology and Intensive Care (Kettern, Kumar), Clinical Pharmacy (Hanssens), and Radiology (Salim), Hamad Medical Corporation, Doha, State of Qatar.

Received 22nd April 2006. Accepted 28th June 2006.

Address correspondence and reprint request to: Dr. Dirk Deleu, Senior Consultant of Neurology and Professor of Clinical Neurology and Neurosciences, Department of Neurology (Medicine), Hamad Medical Corporation, PO Box 3050, Doha, State of Qatar. Tel. +974 4392773. Fax. + 974 4391826 E-mail: doc_deleu@hotmail.com

Neurogenic left ventricular dysfunction (LVD) or neurogenic stunned myocardium (NSM) is characterized by symmetric, deep T-wave inversions on electrocardiography (ECG) associated with elevated serum troponin T or creatine kinase myocardial isoenzyme (CK-MB) levels, or both, and totally reversible multifocal LVD in a nonvascular pattern on echocardiography in a patient with acute severe neurologic illness without any identifiable cardiac risk factors.¹ Hypotension, supraventricular and ventricular arrhythmia, reduction of cardiac output with concomitant neurogenic pulmonary edema, and exceptionally sudden death may complicate the syndrome.¹ Neurogenic stunned myocardium is found in 3-5% of cases with severe aneurysmal subarachnoid hemorrhage (SAH), and is associated with poor clinical grade (Hunt/Hess grades III-V).^{1,2} In addition, one study revealed that 19% of patients with acute neurologic disease (hemorrhagic stroke, head injuries, and intracranial space-occupying lesions), had increased cardiac troponin I levels indicating concomitant cardiac injury.³ Occasionally, NSM has been reported in cerebral infarction, Guillain-Barré syndrome, acute myelitis, and following seizures.⁴ We describe a patient who developed NSM, 6 days after hemorrhagic brain contusion associated with cerebral edema.

Case Report. An 18-year-old athletic man (professional football player), was admitted with major cranial injuries including fractures of the right temporoparietal, and base of the sphenoid bones following a car roll-over. Being a passenger, he was thrown out of the car. Prior to this trauma, he had no history of cardiac disease, epilepsy or any cardiovascular risk factor. On admission, his Glasgow coma scale was 6/15 (only showing flexion withdrawal to painful stimuli). Pupils were in midposition and bilateral light reactive. His blood pressure was 137/77 mm Hg and respiratory rate was 14/min. The ECG showed a sinus rhythm (56/min). The brain CT scan revealed a hemorrhagic contusion of the right temporal lobe, an adjacent extradural hematoma (EDH), and small contre-coup hemorrhagic contusions. He was intubated, and mechanically ventilation, sedation, and analgesics were started. In addition, antiepileptic prophylaxis with phenytoin was started. Cardiopulmonary variables and intracranial pressure (ICP) were continuously monitored. The brain MRI (day 5) revealed right temporal lobe contusion with edema compressing

the lateral ventricle (Figure 1). There was no difference in the size of the EDH. On day 6, an attempt at extubation failed and resulted in acute hemodynamic instability with severe hypotension and bradycardia. In addition, he started developing 8-10 minutes lasting episodes of bilateral mydriasis (non-reactive to light), associated with severe hypertension (202/118 mm Hg), and supraventricular tachycardia (SVT) (158/min) spontaneously reverting to sinus rhythm. The following investigations were immediately performed; 1. ECG, which revealed diffuse, symmetric T-wave inversions, sinus tachycardia (124/min), and signs of the left ventricular hypertrophy; 2. Serum creatine kinase was 311 U/L (39-238 U/L) with CK-MB 4.5% (<2.0%) and troponin T 0.08 ng/ml (<0.03 ng/ml); 3. Electroencephalogram revealed bursts of paroxysmal generalized epileptiform discharges, which did not coincide with these episodes of SVT, hypertension, and mydriasis; 4. Echocardiogram showing apical, inferoposterior hypokinesis and diffuse left ventricular akinesis with severely reduced ejection fraction (18%), and left ventricular enlargement; 5. Chest CT scan, which was normal, particularly, no pleural effusion or cardiac contusion was observed. Despite the initiation of hyperventilation and a mannitol infusion, his ICP increased steadily over the following 8 hours to reach values of 51 mm Hg. Hence, decompressive craniotomy was performed, followed by thiopental coma. Although, the ICP returned to normal (9-12 mm Hg) within the first 12 hours postoperative, his hemodynamic condition (monitored by pulse-integrated continuous cardiac output monitor [PiCCO[®], Pulsion Medical System, Munich, Germany]) showed persistent low cardiac output values, and required intensive inotropic support with adrenaline (up to 180 µg/h) in combination with noradrenaline. Four days after the decompression, he gradually improved and inotropics could be tapered. On day 12, his ECG was normal and repeat echocardiogram revealed an ejection fraction of 50% with no regional or global wall motion abnormalities. An invasive cardiac evaluation was deferred. He was extubated on day 15 and made an excellent recovery.

Discussion. We report a case of NSM, following hemorrhagic brain contusion in a young previously healthy individual. Although the timing of NSM is generally not well-studied, most reported cases describe the onset of NSM (and associated ECG/cardiac enzyme abnormalities) as being closer to the acute neurologic event, usually within the first 2-3 days. Our patient developed NSM 6 days following the acute event. The likely explanation for this was, either the gradual increase in ICP related to the hemorrhagic

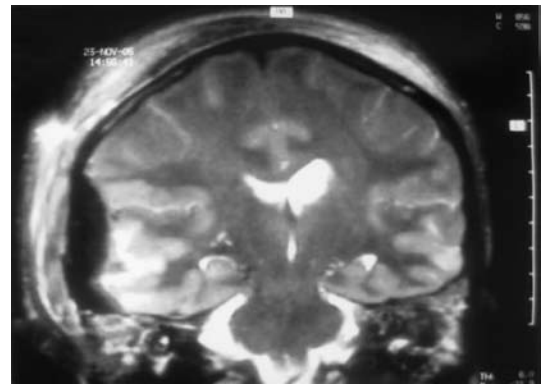


Figure 1 - T2-weighted MRI image of the brain showing left temporal hemorrhagic contusion and adjacent extradural hemorrhage, and contralateral contre-coup contusion.

brain contusion or the possibility of the NSM being associated with seizures and not the trauma itself. One potential minor flaw in the interpretation of the clinical data is that, our patient was not subjected to a coronary angiogram after the cardiac event. However, as professional football player, he was known to have an excellent general condition with no history of cardiac disease. Furthermore, there were no echocardiographic features suggestive of (hypertrophic) cardiomyopathy and chest CT scan did not show any evidence of cardiac contusion. Although, seizures particularly autonomic seizures of temporal lobe epilepsy, should be considered in the differential diagnosis, the presence of sympathetic hyperactivity and low cardiac output and segmental ventricular wall motion abnormalities favors the diagnosis of NSM. Furthermore, the presence of paroxysmal activity on EEG without clinical features of sympathetic outflow hyperactivity (hypertension, SVT, mydriasis), lets us assume that these episodes were unlikely autonomic seizures of the temporal lobe. However, whether the NSM was related to ictal phenomena or to the increased ICP secondary to the hemorrhagic contusion remains unclear. Postictal NSM has been reported,⁴ however, in both these patients, the trauma and seizures with its subsequent NSM were separated by more than 8-10 years.

The LVD in this patient was severe and necessitated high dose of inotropics. The levels of circulating catecholamines were not measured, for 2 reasons: first, the patient was receiving high doses of adrenaline and noradrenaline shortly after the onset of NSM to support his cardiac output, and secondly, there is evidence from the studies in SAH that direct neural stimulation rather than systemic adrenergic secretion is implicated in NSM.¹ The pathogenesis of NSM is still contentious. The elevation of ICP, with subsequent reduction in cerebral perfusion

pressure probably triggers a vigorous cerebroprotective sympathetic system activation leading to NSM. Pathologically, half of the patients with SAH, showed myocardial contraction band necrosis on autopsy.¹ Other conditions, in which reversible LVD has been associated with contraction band necrosis include fatal status asthmaticus, pheochromocytoma, sudden death associated with violent assault, and brain death.³ These clinical associations with experimental studies, support the presumed unifying role of sympathetic outflow hyperactivity and catecholamine toxicity in the pathogenesis of NSM.^{1,5}

Neurogenic stunned myocardium in trauma intensive care units is rarely described and probably underestimated; hence, we hope that this report stimulates more systematic investigation of cardiac dysfunction in these and similar conditions.

References

1. Mayer SA, Lin J, Homma N, Solomon RA, Lennihan L, Sherman D, et al. Myocardial injury and left ventricular performance after subarachnoid hemorrhage. *Stroke* 1999; 30: 780-786.
2. Bulsara KR, McGirt MJ, Liao L, Villavicencio AT, Borel C, Alexander MJ, et al. Use of the peak troponin value to differentiate myocardial infarction from reversible neurogenic left ventricular dysfunction associated with aneurysmal subarachnoid hemorrhage. *J Neurosurg* 2003; 98: 524-528.
3. Dixit S, Castle M, Velu RP, Swisher L, Hodge C, Jaffe AS. Cardiac involvement in patients with acute neurologic disease. *Arch Intern Med* 2000; 160: 3153-3158.
4. Chin PS, Branch KR, Becker KJ. Postictal neurogenic stunned myocardium. *Neurology* 2005; 64: 1977-1978.
5. Samuels MA. "Voodoo" death revisited: the modern lessons of neuro cardiology. *Neurologist* 1997; 3: 293-304.

REFERENCES

- * References should be primary source and numbered in the order in which they appear in the text. At the end of the article the full list of references should follow the Vancouver style.
- * Unpublished data and personal communications should be cited only in the text, not as a formal reference.
- * The author is responsible for the accuracy and completeness of references and for their correct textual citation.
- * When a citation is referred to in the text by name, the accompanying reference must be from the original source.
- * Upon acceptance of a paper all authors must be able to provide the full paper for each reference cited upon request at any time up to publication.
- * Only 1-2 up to date references should be used for each particular point in the text.

Sample references are available from:
http://www.nlm.nih.gov/bsd/uniform_requirements.html