

Neurosurgical gossypiboma radiologically mimicking a lumbar abscess

H. Selim Karabekir, MD, Ahmet Yildizhan, MD, Elmas K. Atar, MD.

ABSTRACT

Lumbar discectomy is the most common operative technique at neurosurgery clinics around the world. The complications of lumbar disc operation include infections, dural tear, bleeding, vascular, and intestinal injuries. Infectious complications of lumbar disc surgery are superficial and profound tissue infections, meningitides, and epidural abscess. Although retained surgical sponges (gossypiboma) are well known intraoperative complications in other surgical branches, they have not been widely reported in neurosurgery. In this report, we present a case of retained surgical sponge at the operation site and discuss with the literature.

Neurosciences 2007; Vol. 12 (2): 163-165

From the Neurosurgery Department (Karabekir), School of Medicine, Ayfon Kocatepe University and the Neurosurgery Department (Yildizhan, Atar), School of Medicine, Yeditepe University, Afyonkarahisar, Turkey.

Received 8th January 2006. Accepted 9th April 2006.

Address correspondence and reprint request to: Dr. H. Selim Karabekir, Assistant Professor, Neurosurgery Department, School of Medicine, Ayfon Kocatepe University, Afyonkarahisar 03100, Turkey. Tel. +90 (272) 2142065. Fax. +90 (272) 2133066. E-mail: hskarabekir@hotmail.com, hskarabekir@aku.edu.tr

Three classes of resorbable hemostatic agents are currently in widespread use: gelatin foam (Gelfoam), oxidized cellulosa (Surgicel), and microfibrillar collagen (Avitene),¹ and sometimes, for hemostatic control, surgical sponges are used. Retained surgical sponges after spinal operations have rarely been reported.¹⁻⁵ Ramirez et al³ reported the number of incidences of retained surgical sponge as 0.007%. Textiloma (from Latin textile, a woven fabric, plus suffix oma, meaning swelling or tumor) or gossypiboma (from Latin Gossypium, the genus of cotton plants, plus boma, a Kiswahili term meaning place of concealment) or muslinoma

(from muslin, a woven cotton fabric) are historical terms that have been given to foreign body-related inflammatory masses arising from retaining non-absorbable cotton matrix that is either inadvertently or deliberately left behind after surgery, together with the inflammatory reaction.¹ In our report, we encountered a retained surgical sponge 13 years after the operation.

Case Report. A 57-year-old woman presented with complaints of low back and right leg pain. She had previous right hemilaminectomy, and discectomy operation for L4-L5 herniated disc at a special medical center. Her pain continued after operation. After 13 years from the first operation, she was admitted to our clinic with low back pain. She was afebrile and appeared to be in a good physical examination. The only symptom that we could find was painful low back motions. There was no neurological deficit. A T1 and T2 weighted MRI revealed hypointensity at the center and hyperintense circumference of a mass lesion, at the right L4-S1 paravertebral region like an abscess (Figures 1-2), and she underwent surgery. The lesion was adherent to the circumferential tissue. During the operation necrotic tissues were removed and the lesion, which was like a granulomatous abscess was totally excised. A surgical sponge was seen at the center of the granulomatous mass. After excision, the cavity was washed with saline, and the layers were closed as usual. Postoperatively she was pain-free. After 3 months, a control MRI was taken showing improvement at the cavity (Figures 3-4).

Discussion. A review of the literature on retained surgical sponge and gossypiboma, covering the years between 1965 and 2004, revealed only 10 reports pertaining to neurosurgical operations, either cranial,^{6,7} or spinal.^{2,5,8-10} Cotton-based and similar materials are widely used in neurosurgery for subperiosteal muscle dissection and hemostatic control. Cottonoids are more commonly lost than sponges, which is well known, though not readily reported.¹⁰ Being an incidence for medical malpractice, cases of retained surgical sponges are rarely reported by authors. Ford described 2 patients with retained cottonoids after lumbar spinal operations,¹ and Gifford² reported a retained sponge after laminectomy. Retained surgical sponges may produce serious complications;¹⁰ abscesses, delayed wound healing, adhesion,

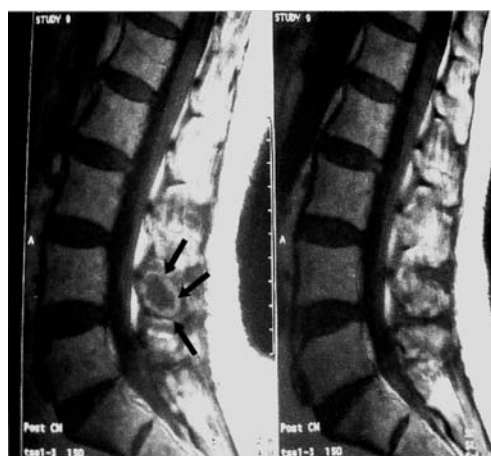

Figure 1 - Lesion signed with arrows. This appearance mimics an abscess.

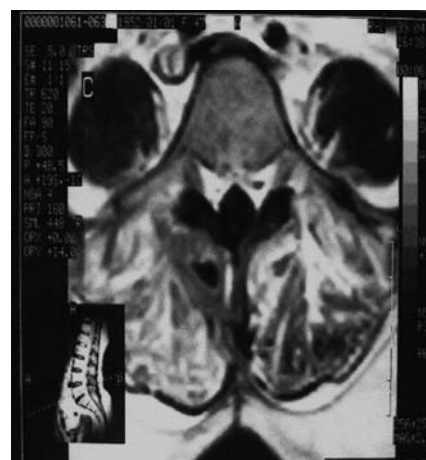


Figure 3 - The postoperative cavity of the gossypiboma, 3 months after total removal.

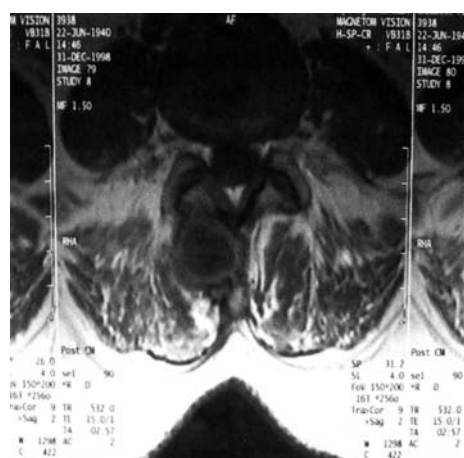


Figure 2 - Axial MR images of the lesion.

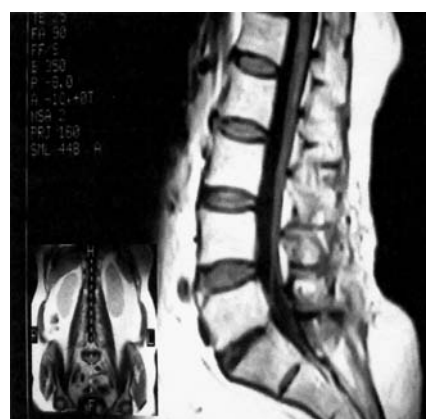

Figure 4 - Postoperative 3rd month, sagittal images of the cavity.

erosions into the intestinal tract, and even pathological fractures.⁹ Stoll¹⁰ reported a granulomatous abscess due to a retained sponge that caused low back pain 40 years after laminectomy was performed. The risk factors which predispose to infection after lumbar operations include inadequate sterilization of the operation region and surgical instruments, previous cutaneous infection at the operation region, perioperative contamination, forgotten foreign bodies (needle, lancet, sponge, cotton, and so on), instrumentation, inadequate immune response in patients, corticosteroid usage after operation and pseudomeningocele formation.

Paraspinal abscess has no distinguishing features; most of them are hypointense on T1-weighted images and hyperintense on T2-weighted images. Rim enhancement around intrasosseous and paraspinal soft tissue abscess is more common than in other spinal

infections. T1-weighted MR image analyses could not clearly show the characteristic structure of the surgical sponge, but in a reported case, T2-weighted MR imaging showed a folded fabric appearance within the cystic mass. The paraspinal abscess in our case was hypointense on T1-weighted and T2-weighted images and we could observe a thin hypertense image at the circumference of the mass on T1-weighted images.

Early diagnosis is important for preventing chronic infections, loss of work and money. Abscess drainage with appropriate intravenous antibiotics and removal of the necrotic tissue and retained sponge are important in the treatment of spinal abscess caused by retained surgical sponges. As in our patient, if the event is old and there is a granulomatous mass, total removal of the mass and affected tissue is the appropriate treatment. In cases of long-lasting wound infections that do not respond to antibiotherapy, and continuing pain or

symptoms after operation, the possibility of retained foreign materials such as surgical sponges and paddies should be considered.

References

1. Ribalta T, McCutcheon IE, Neto AG, Gupta D, Kumar AJ, Biddle DA, et al. Textiloma (gossypiboma) mimicking recurrent intracranial tumor. *Arch Pathol Lab Med* 2004; 128: 749-758.
2. Gifford RR, Plaut MR, McLeary RD. Retained surgical sponge following laminectomy. *JAMA* 1973; 223: 1040.
3. Ramirez LF, Thisted R. Complications and demographic characteristics of the patients undergoing lumbar discectomy in community hospitals. *Neurosurgery* 1989; 25: 235-236.
4. Usul H, Kuzeyli K, Yazar U, Cakir E, Arslan E. Retained surgical sponge after hemilaminectomy: Report of two cases. *Turkish Neurosurgery* 2003; 13: 36-41.
5. Williams RG, Bragg DG, Nelson JA. Gossypiboma-the problem of the retained surgical sponge. *Radiology* 1978; 129: 323-326.
6. Mathew JM, Rajshekhar V, Chandry MJ. MRI features of neurological gossypiboma: report of two cases. *Neuroradiology* 1996; 38: 468-469.
7. Ziyal IM, Aydin Y, Bejjani GK. Suture granuloma mimicking a lumbar disc recurrence : case illustration. *J Neurosurg* 1997; 87: 473.
8. Ford LT. Complications of lumbar disc surgery, prevention and treatment: local complications. *J Bone Joint Surg (Am)* 1968; 50: 418-428.
9. Marquardt G, Retting J, Lang J, Seiert V. Retained surgical sponges, a denied neurosurgical reality? Cautionary note. *Neurosurg Rev* 2001; 24: 41-43.
10. Stoll A. Retained surgical sponge 40 years after laminectomy. *Surg Neurol* 1988; 30: 235-236.

SUPPLEMENTS

- * Supplements will be considered for work including proceedings of conferences or subject matter covering an important topic
- * Material can be in the form of original work or abstracts.
- * Material in supplements will be for the purpose of teaching rather than research.
- * The Guest Editor will ensure that the financial cost of production of the supplement is covered.
- * Supplements will be distributed with the regular issue of the journal but further copies can be ordered upon request.
- * Material will be made available on the Neurosciences website