

# Comparison of unilateral posterior lumbar interbody fusion and bilateral posterior interbody fusion with simple discectomy at degenerative disc herniations

Hamit S. Karabekir, MD, Elmas K. Atar, MD, Soner Yaycioglu, MD, Ahmet Yildizhan, MD.

## ABSTRACT

**الأهداف:** تقييم النتائج المبكرة لتقنية الدمج للجسم الداخلي القطني الخلفي وحيد الجانب في حالات قطع القرص، مقارنة مع حالات قطع القرص البسيط والدمج الخلفي على الجانبين باستخدام نقاط انالوق المرئية (VAS) ونتائج أجهزة أوسويستري والفحوصات الإشعاعية والبدنية.

**الطريقة:** خضعت مجموعة التحكم وعددها 40 مريضاً لعملية قطع القرص البسيطة. في المجموعة الأولى ثمانية مرضى تعرضوا لتفتحات متكررة في القرص وتضخم سطح المفصل. واحد وعشرون مريضاً يعانون من تفتحات في القرص وتضخم سطح المفصل. في هذه المجموعة تم استعمال تقنية بوليثيريثركتون (PEEK) لحماية ارتفاع القرص والتكرار. في المجموعة الثانية وعددها 15 مريضاً يعانون من تفتحات تنكسية في القرص القطني وتضخم في سطح المفصل. خضع جميع المرضى لعملية جراحية في الفترة ما بين أكتوبر 2002م وحتى فبراير 2004م، في قسم جراحة المخ والأعصاب - كلية الطب - جامعة كوستايب الطبية - تركيا. تمت متابعة حالتهم بالفحوصات الإشعاعية، ونقاط انالوق المرئية (VAS)، ونقاط أوسويستري، والفحوصات السريرية، وقورنت المجموعات مع بعضها البعض بشكل إحصائي.

**النتائج:** في مجموعة التحكم (عدد=40) هنالك تكرار وفقدان لعلو القرص. لم يكن هناك تكرار في المجموعة الأولى (عدد=29) وكان فقدان علو القرص محدوداً. أما المجموعة الثانية (عدد=15) فلم يكن هنالك تكرار ولكن فقدان علو القرص كان أكثر من المجموعة الأولى.

**خاتمة:** إذا كان المريض يعاني من مرض القرص التنكسي بعد إجراء قطع القرص باستعمال تقنية قفص (PEEK) الخلفي على الجانبين وترقيع الجسم الداخلي، وتعد هذه طريقة آمنة لعلاج هذا النوع من المرضى.

**Objectives:** To evaluate the early results of unilateral posterior lumbar interbody fusion technique in lumbar discectomy cases compared with simple discectomy and bilateral posterior interbody fusion cases using visual analog scale (VAS) and Oswestry

outcomes instruments and radiological and physical examinations.

**Methods:** The control group had 40 patients who underwent simple discectomy. In group one, 8 patients had recurrent disc herniations and facet joint hypertrophy, 21 patients had degenerative disc disease and facet joint hypertrophy. In this group polyetheretherketone (PEEK) cage was used for protecting the disc height and recurrence. In group 2, 15 patients had degenerative lumbar disc herniations and bilateral facet joint hypertrophy. All patients were operated upon between October 2002 between February 2004 at the Neurosurgery Department of Kocatepe University Medical School, and were followed by the help of radiological exams, VAS and Oswestry scores, and clinical exams. The groups were compared to each other statistically.

**Results:** In the control group (n=40) there were recurrences and disc height loss. In group one (n=29) there were no recurrences and the height lost was limited. In group 2, (n=15) there was no recurrence, however, the lost disc height was more than group one.

**Conclusion:** If the patient has degenerative disc disease, the use of unilateral posterior PEEK cage and interbody grafting is a safer mode of treatment after discectomy.

*Neurosciences 2008; Vol. 13 (3): 248-252*

*From the Department of Neurosurgery (Karabekir), Afyon Kocatepe University, Afyon, Department of Neurosurgery (Atar), Istanbul Spinal Surgery Center, Department of Neurosurgery (Yildizhan), School Of Medicine, Yeditepe University, Istanbul, and the Department of Neurosurgery (Yaycioglu), School Of Medicine, Adnan Menderes University, Aydin, Turkey.*

*Received 11th September 2007. Accepted 23rd February 2008.*

*Address correspondence and reprint request to: Dr. Hamit S. Karabekir, Department of Neurosurgery, School of Medicine, Afyon Kocatepe University, Ali Cetinkaya Kampusu, Afyonkarahisar, Turkey. Tel. +90 (272) 2142065. Fax. +90 (272) 2133066. E-mail: hskarabekir@hotmail.com / hskarabekir@aku.edu.tr*

From the biomechanical respect, posterior lumbar interbody fusion (PLIF), introduced by Dr. Ralph Cloward in the 1940's<sup>1</sup> is an optimal fusion. A successful PLIF carries the advantages of restoring disc height, immobilizing the unstable degenerated intervertebral disc area, decompressing the dural sac and nerve roots and restoring load bearing to anterior structures. Degenerative disc disease occurs when the outer ring of the disc, the annulus fibrosus, becomes damaged or worn. The contents of the disc may then protrude and impinge on a spinal nerve root. This will cause pain in the lower back that radiates to the hips and down the backs of the legs. It usually occurs in healthy, active individuals between 30-50 years old. Diagnosis is confirmed by MRI scans. In spite of many fusion techniques, such as autologous iliac crest bone graft, allograft bone, dowel-shaped graft, key stone graft, tricortical graft, and bone chips, the PLIF application is preferred for achieving lumbar fusion by the spine surgeons.<sup>2,3</sup> The PLIF is usually accomplished with implantation of 2 threaded cages.<sup>4</sup> The rate of fusion of bone grafts alone has ranged from 46-90%.<sup>5-9</sup> Because of difficulty in achieving fusion and maintaining spinal stabilization, spinal instrumentation has become an important and popular adjunct to bone grafting in lumbar arthrodesis, further increasing the fusion rates, 80-90%.<sup>10</sup> Interbody fusion techniques have also shown high fusion rates with distinct advantages.<sup>1-14</sup> Some of these advantages include immediate anterior column load sharing, a larger surface area for fusion, bone graft subjected to compressive loads that are advantageous in achieving fusion and the ability to restore normal sagittal contour while indirectly decompressing the neuroforamen.<sup>11</sup> The most effective treatment of discogenic back pain unresponsive to conservative care, is the interbody fusion technique.<sup>15,16</sup> Blume, in 1981, described an unilateral approach for PLIF to address some of the potential complications of the standard PLIF, such as root injuries, and instabilization.<sup>17,18</sup> A surgical technique in which bilateral anterior column support can be achieved through a unilateral posterior approach was popularized by Harms et al.<sup>19</sup> Weatherly et al<sup>16</sup> reported on 5 patients during a 10-year period who had solid posterolateral fusions, but still had positive discography under the fusion and had their back pain relieved by anterior interbody fusion. All 5 patients had positive discograms and had pain relief after interbody fusion.<sup>16</sup> Recently, Derby et al<sup>15</sup> noted that patients with highly sensitive discs, as determined by pressure controlled discography, achieved significantly better long-term outcomes with combined anterior/posterior fusion. Nevertheless, there are some problems followed by degenerative disc disease operations such as recurrence, loss of height, and instability. Therefore,

we planned to use a modified technique to prevent the recurrence of disc herniation and to protect the disc height. This modified technique consists of a unilateral posterior lumbar one interbody PEEK cage, and because of the large surface, this is grafted easily by using demineralized bone matrix (DBM) putty graft. Simultaneously, we compared the unilateral approach with bilateral posterior interbody expandable cages.

**Methods.** This prospective randomized study was performed between October 2002 and February 2004 at the Neurosurgery Department of Afyon Kocatepe University. Patients who were planned for lumbar degenerative disc surgery were included with the written permission of the patients and the Ethics Committee of Afyon Kocatepe University.

**Patients.** Eighteen women and 11 men with a mean age of 45.3 years (range 27-72 years) who underwent a unilateral posterior lumbar interbody fusion (UPLIF) were included in the study. We used this technique to treat 29 patients with degenerative lumbar disc disease (inclusion criteria for study group one), and report the clinical and radiological results of a minimum of 33 months follow-up. During the same period, 40 patients underwent a simple discectomy and formed the control group. The control group's mean age was 43.3 years (22 women and 18 men). If a patient had degenerative disk disease and bilateral facet hypertrophy, bilateral foraminal narrowing and disc (inclusion criteria for study group 2), then they were included in group 2 (10 women, 5 men). The mean age was 44.85 years in group 2, with a mean follow-up period of 24 months. All the patients were operated at the same level, L4-L5. Every patient in study groups one and 2 had more than one year of disabling back pain with leg pain refractory to aggressive conservative treatment. Patients were asked to complete pre and postoperative questionnaires assessing pain (medication use) and ability to perform daily activities including walking, standing, sitting, lifting, social activities, and work status. The questionnaire was based on visual analogue scale (VAS) and Oswestry outcomes instrument. A point system was used to categorize results as excellent (has no pain, unlimited daily activities), good (has pain if tired or with hard activities), fair (has pain if tired or long activities), unchanged (has no change after operation) and poor (worse after operation). Previous lumbar surgery, smoking history, accompanying disease, working compensation, and disability status were also recorded. The follow-up period in group one averaged 37.41 months (range 33-49 months) and in group 2 was 25.5 months (range 24-28). In group one, 29 patients underwent a single level UPLIF. All patients had degenerative disc disease, and 8 had a recurrent disc herniation. In group 2, all of

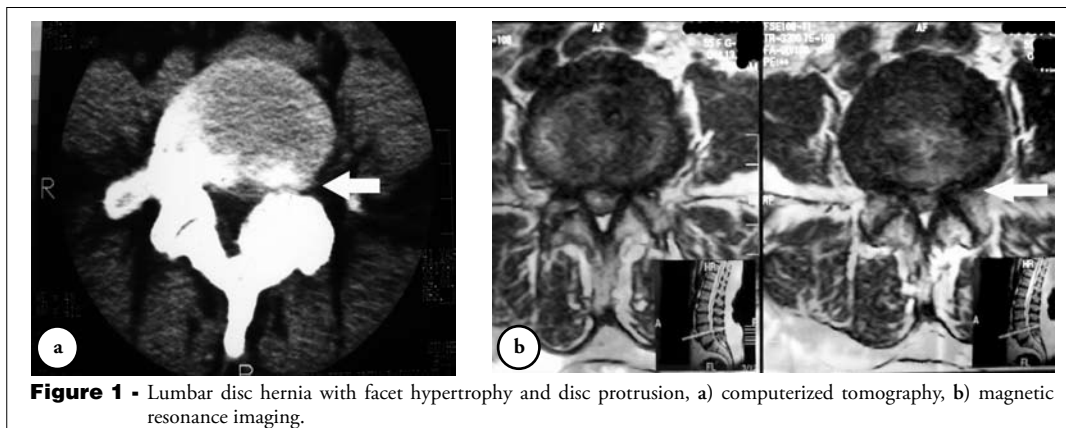
15 patients underwent single level bilateral discectomy and fusion. Postoperative wound infections and discitis were accepted as exclusion criteria.

**Surgical technique.** The patients were placed on a spine frame in prone position with the hips in extension to maintain lumbar lordosis. Through standard midline approach, the side of the spine selected for the UPLIF was based on preoperative symptoms. Once hemostasis was achieved with bipolar electrocautery and thrombin-soaked absorbable gelatin sponges or cottonoids, the underlying disc space, dural sac and nerve root could be readily seen. After retracting the nerve root a 15-blade scalpel was used to create a rectangular window to annulus. The medial border of the window was the lateral margin of the dural sac, and the lateral border was the lateral edge of the visible annulus. The incised annulus and degenerative disc material was removed. Cleaning upper and below end plates by curettes and after irrigating the disc space with gentamicin containing saline, posterior lumbar Fidji PEEK cage (Spinenext, Bordeaux, France) (heights ranging from 8-12 mm) were placed in the disc space. Before fixing, they were filled with DBM putty graft (Osteotech Inc, New Jersey, USA). If there were facet joint hypertrophy, then partial facetectomy was carried out. In group 2, this procedure was applied bilaterally, and then DBM grafts were placed at the intervertebral spaces using 2 long canalized metal pipes followed by posterior B-Twin expandable cages (Disc-O-Tech Medical Technologies Ltd, Herzlia, Israel), with heights ranging from 11.5-13.5 mm. Simple discectomy was carried out on the control group patients. All the patients were mobilized on the first postoperative day, and an external orthosis was used for the first month. At 6 weeks, progressive range of motion and strengthening exercises were initiated, and at 6 months, patients were allowed to perform impact and full activities. Follow up was at regular monthly intervals beginning from the first month until the latest control (>24 months).

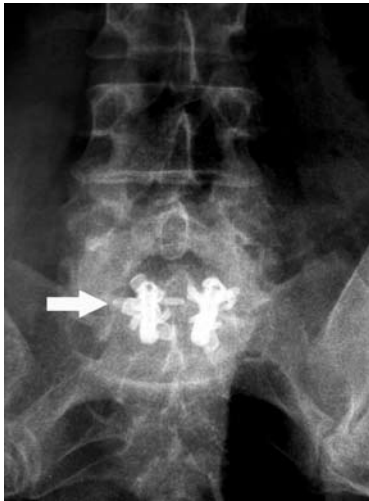**Radiographic assessment.** Plain posterolateral and lateral standing radiographs including flexion-extension lateral views were obtained to evaluate disc height, segmental instability, sagittal profile, and balance. An MRI and CT scan were obtained for each patient to document levels of degenerative disc disease and site of neural compression (Figures 1a & b). Postoperatively, plain radiographs including flexion-extension views were obtained in control visits to assess the progress of the fusion. A fusion was confirmed by progressive increase in interspace bone density and blurring of the adjacent endplates, presence of bridging posterolateral trabecular bone and no evidence of hardware failure, loosening, or motion on flexion-extension radiographs (Figure 2). At the end of 2 years, we reviewed all the plain radiographs, CT, and MRIs of the patients again (Figure 3).

**Statistical analysis.** Statistical evaluation was carried out using the SPSS 10.0 program for Windows. Student t-test for independent cases was used for statistical analysis. Statistical significance was accepted at  $p < 0.05$ . A Bonferroni correction was calculated for each group of comparisons.

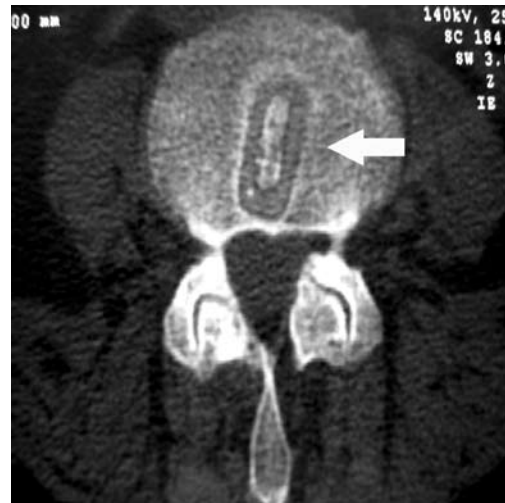
**Results. Clinical outcome.** One patient did not attend after 2 years follow-up in group one. In group one, the pain level on a 10-point VAS improved from a preoperative mean value of 8.6-3.2 (Student t test,  $p = 0.047$ ) at latest follow-up. In group 2, the VAS values improved from 8.7-3.0 ( $p = 0.042$ ). No patients reported postoperative pain greater than their preoperative level in the 2 study groups. Preoperatively, all the patients were taking one or more nonsteroid anti-inflammatory (NSAI) analgesics daily, and postoperatively one patient in group one, and 2 patients in group 2 still required NSAI drugs sometimes for pain. In group one, the average preoperative composite score for activities of



**Figure 1** - Lumbar disc hernia with facet hypertrophy and disc protrusion, a) computerized tomography, b) magnetic resonance imaging.



**Figure 2** - An x-ray of B-TWIN expandable cages.



**Figure 3** - Fusion and polyetheretherketone (PEEK) cage, CT image.

daily living (Oswestry) of 33 (66%, crippled) increased to an average of 9 (18% minimal disability) in the postoperative latest control ( $p=0.038$ ). In group 2, the average preoperative score was 38 (76% crippled). Twenty-seven patients in group one (93.1%), and 14 patients in group 2 (93.3%) were rated excellent or good, based on pre and postoperative questionnaire scores that included combined pain and daily activity scores (Table 1). The remaining 2 had a complaint of pricking sense at lumbar region while sitting down and standing up. In group 2, 3 patients had pricking sense. Though only 6 patients in group one, and 4 patients in group 2 could work before treatment, postoperatively all the patients returned to work. Radiographic fusion was thought to be present in 22 (75.9%) patients based on the presence of the disc obliteration of the disc space anterior to the cages as well as continuous trabecular bone throughout the intervertebral fusion mass in group one. This rate was 73.3% (11 fusion) in group 2. Two patients had subsidence of the cage, and no patient needed reoperation in the follow-up period in group one. In group 2, subsidence of the cages was seen in 4 patients. The pseudoarthrosis rate in group one was 24.1% (7 of 29 patients), and in group 2 was 26.7% (4 of 15 patients). In the control group, there were 5

recurrences (12.5%) and disc height loss of the operated levels with foraminal narrowing was common. Pain level on a 10-point VAS improved from a preoperative mean value of 8.76-4.21 (student t test,  $p=0.048$ ) at latest follow-up. Five patients reported postoperative pain greater than their preoperative level. Only 5 patients in the control group taking NSAID drugs daily in the preoperative period needed to take drugs in the postoperative period. The preoperative composite score for activities of daily living (Oswestry) preoperatively averaged 36 (72% crippled) and postoperatively increased to 12 (24% minimal disability) ( $p=0.045$ ) in group one. In our series, there was no recurrence, or listhesis and only 2 cases of subsidence in group one (6.9%), and 4 in group 2 (26.7%) in the follow up period. The rate of disc height loss was greater in the control group, 95% (38 of 40 patients). This rate was 62.1% (18 of 29 patients) in group one and 86.6% (13 of 15 patients) in group 2 ( $p=0.044$ ). Complications other than pseudoarthrosis (group one = 7/29, group 2 = 4/15) included one dural tear intraoperatively in each group. There was no evidence of clinical arachnoiditis or cage-related complications in any of the groups. There was only one discitis in the control group.

**Table 1** - Postoperative questionnaire score that included combined pain and daily activity scores.

| Groups         | Excellent | Good | Fair | Unchanged | Poor |
|----------------|-----------|------|------|-----------|------|
| Control (n=40) | 19        | 12   | 5    | 2         | 1    |
| Group 1 (n=29) | 20        | 7    | 2    | 0         | 0    |
| Group 2 (n=15) | 12        | 2    | 1    | 0         | 0    |

**Discussion.** From the first reports of spinal arthrodesis 88 years ago, many techniques for lumbar spine have been developed for the management of a wide range of conditions.<sup>1</sup> The rate of bone grafts alone have ranged from 46-90%.<sup>5-9</sup> Because of difficulty in achieving fusion and maintaining spinal stabilization, spinal instrumentation has become an important and popular adjunct to bone grafting in lumbar arthrodesis, further increasing the fusion rates, 80-90%.<sup>10</sup> Posterior interbody techniques allow the



surgeons to simultaneously address all the pathological lesions through a single approach. Shorter incisions and careful muscle stripping have resulted in less soft tissue dissection. When combined with pedicle screwing, anterior and posterior column stabilization can be achieved. Interbody fusion and a posterolateral fusion together provide 360° circumferential fusion bed, and may be associated with improved fusion rates.

Bilateral posterior lumbar interbody fusion without additional posterior instrumentation has suggested that significant destabilization of the fused segment may occur in some biomechanical studies.<sup>20</sup> In bilateral interbody fusion, significant bilateral bony and ligamentous removal is often required to allow accurate placement of properly sized implants. However, in our study we used unilateral PEEK cages with anatomic shapes and made limited laminectomy and partial facetectomy. Therefore, we could place the PEEK cage full of DBM putty graft into the intervertebral space to preserve the disc height, prevent recurrence, and provide additional support to the facet joint. In our series, there was no recurrence or listhesis and only 2 instances of subsidence in group one, and 4 in group 2 in the follow up period. The rate of disc height loss was greater in the control group (95%), with a rate of 62.1% in group one, and 86.6% in group 2 ( $p=0.044$ ). Our radiographic fusion rate and objective clinical excellent/good rate in groups one and 2 compared well with other fusion techniques. This may be partly because of an overall favorable patient population. Our patients had no multiple comorbidities potentially affecting the success of operation and fusion (heavy smoking, diabetes, previous failed fusion).

Unilateral posterior cage application can be easily mastered and there is no serious learning curve if a surgeon can operate on a lumbar disc patient, they can also do this. After a meticulous disc removal and as our patients' partial facetectomy, unilateral posterior approach is used to place the cage. The UPLIF is indicated for chronic mechanical pain related to degenerative disc disease and recurrent disc herniation. With this technique, recurrence of disc and the possibility of foraminal narrowing and loss of height can also be reduced. The greatest advantage of the PEEK cage to the B-twin expandable cage is to preserve the disc space height.

In conclusion, unilateral posterior PEEK cage application and fusion is a safe and reproducible technique to provide unilateral posterior column support. The ideal patient for this procedure is one with long standing mechanical back pain with a significant radicular component, unresponsive to aggressive nonoperative treatment with radiologic evidence of same side facet joint hypertrophy. We do not recommend this

procedure for more than 2 levels, and the ideal indication is one level. Proper patient selection continues to be the most important factor in good clinical outcome with this procedure as well as others.

## References

1. Cloward RB. The treatment of ruptured lumbar intervertebral discs by vertebral body fusion: indications, operative technique, after care. *J Neurosurg* 1953; 10: 154-168.
2. Albee FH. Transplantation of a portion of the tibia into the spine for Pott's disease. A preliminary report. *JAMA* 1911; 57: 885-886.
3. Hibbs RH. An operation for progressive spinal deformities. *NY J Med* 1911; 93: 1013-1016.
4. Bagby GW. Arthrodesis by the distraction-compression method using a stainless steel implant. *Orthopedics* 1988; 11: 931-934.
5. Boucher HH. A method of spinal fusion. *J Bone Joint Surg Br* 1959; 41: 248-259.
6. Stauffer RN, Coventry MB. Posterolateral lumbar spine fusion. *J Bone Joint Surg Am* 1972; 54: 1195-2004.
7. Thompson WA, Ralston EL. Pseudoarthrosis following spine fusion. *J Bone Joint Surg Am* 1949; 31A: 400-405.
8. Watkins MB. Posterior lateral fusion in pseudoarthrosis and posterior element defects of the lumbosacral spine. *Clin Orthop* 1964; 35: 80-85.
9. Herkowitz HN, Sidhu KS. Lumbar spine fusion in the treatment of degenerative conditions. Current indication and recommendations. *J Am Acad Orthop Surg* 1995; 3: 125-135.
10. Yashiro K, Homma T, Hokari Y, Katsumi Y, Okumura H, Hirano A. The Steffee variable screw placement system using different methods of bone grafting. *Spine* 1991; 16: 1329-1334.
11. Lin PM, Cautilli RA, Joyce MF. Posterior lumbar interbody fusion. *Clin Orthop Relat Res* 1983; 180: 154-167.
12. Newman MH, Grinstead GL. Anterior lumbar interbody fusion for internal disc disruption. *Spine* 1992; 17: 831-833.
13. Ray CD. Threaded titanium cages for lumbar interbody fusions. *Spine* 1997; 22: 667-680.
14. Steffee A, Sitkowski D. Posterior lumbar interbody fusion and plates. *Clin Orthop Relat Res* 1988; 227: 99-102.
15. Derby R, Howard MW, Grant JM, Lettice JJ, Van Peteghem PK, Ryan DP. The ability of pressure-controlled discography to predict surgical and nonsurgical outcomes. *Spine* 1999; 24: 364-372.
16. Weatherly CR, Prickett CF, O'Brien JP. Discogenic pain persisting despite solid posterior fusion. *J Bone Joint Surg Br* 1986; 68: 142-143.
17. Blume HG, Rojas CH. Unilateral lumbar interbody fusion (posterior approach) utilizing dowel graft. *J Neurol Orthop Surg* 1981; 2: 171-175.
18. Cho KJ, Suk SI, Park SR, Kim JH, Kim SS, Choi WK, et al. Complications in posterior fusion and instrumentation for degenerative lumbar scoliosis. *Spine* 2007; 32: 2232-2237.
19. Harms J. True spondylolisthesis reduction and more segmental fusion in spondylolisthesis. In: Bridwell KH, Dewald R, editors. *The Textbook of Spinal Surgery*. 2nd ed. Philadelphia (PA): Lippincott-Raven, 1997. p. 1337-147.
20. Shirado O, Zdeblick T, McAfee P, Warden KE. Biomechanical evaluation of methods of posterior stabilization of the spine and posterior lumbar interbody arthrodesis for lumbosacral isthmic spondylolisthesis. A calf-spine model. *J Bone Joint Surg Am* 1991; 73: 518-526.