

Cerebral abscess caused by *Aggregatibacter aphrophilus*

Sudheer P. Ahamed, MD, MRCP (UK), Sanjiv Lath, MD, FRACP, Gerald J. DeGabriele, FRACP, Vivin T. Mathew, MBBS.

ABSTRACT

بكتيريا *Aggregatibacter aphrophilus* كانت تعرف سابقا بـ *Haemophilus aphrophilus*، وهي من المسببات النادرة للأمراض لدى الإنسان. والتصنيف الأخير لهذه الكائنات وضعها كأحد أصناف بكتيريا *Aggregatibacter*. ويبدو هذا الكائن أنه أحد المكونات الطبيعية للبكتيريا الموجودة في الفم، وقد أفادت التقارير بأنه يتسبب في التهاب الشعاف البطانة الداخلية للقلب، التهاب الجيوب الأنفية، الالتهاب الرئوي، انتفاخ الرئة، خراج أنسجة الجسم الرقيقة، التهاب السحايا، التهاب المفاصل التعفني، والتهاب الفقرات. يعتبر الخراج الدماغى الناتج عن بكتيريا *Aggregatibacter* نادر الحدوث. إن هذا التقرير لمناقشة حالة الخراج الدماغى بسبب بكتيريا *Aggregatibacter aphrophilus* ومناقشة خصائص هذا الكائن.

Aggregatibacter aphrophilus was previously known as *Haemophilus aphrophilus* and is a rare cause of disease in humans. A recent reclassification of these organisms has placed them in the new genus of *Aggregatibacter* species. The organism seems to be a normal component of oral flora and has been reported to cause endocarditis, sinusitis, pneumonia, empyema, soft tissue abscess, meningitis, vertebral discitis, and septic arthritis. Brain abscess due to *Aggregatibacter* is rare. We report a case of cerebral abscess due to *Aggregatibacter aphrophilus* and discuss the characteristics of this organism.

Neurosciences 2010; Vol. 15 (1): 40-42

From the Department of Medicine, Armidale Rural Referral Hospital, Armidale, New South Wales, Australia.

Received 1st August 2009. Accepted 8th September 2009.

Address correspondence and reprint request to: Dr. Sudheer Ahamed, Locked Bag 4, Armidale Rural Referral Hospital, Armidale, New South Wales 2350, Australia. Tel. +61 (2) 67769736. Fax. +61 (2) 67764704. E-mail: Sudheer.ahamed@hnehealth.nsw.gov.au

A bacterial brain abscess is a relatively uncommon infection with an incidence of 0.3-1.3/100,000 persons per year.¹ Most of these cases occur associated with predisposing conditions such as otitis media, sinusitis, or presence of pyogenic infections in other parts of the body. Dental infections are associated with around 2% of the brain abscesses. The etiological organisms

associated with brain abscesses vary depending on the associated features and presence of immune deficiency. In the following case report, we present a case of brain abscess caused by a relatively non-pathogenic organism called *Aggregatibacter aphrophilus* (*A. aphrophilus*). The predisposing conditions for infection with this organism have been reported as dental infections, procedures, and contact with pet animals especially dogs.² This case is being presented to highlight the importance of these organisms as a cause of infection, such as brain abscess.

Case Report. A 73-year-old male patient of Italian descent presented to the emergency service of our hospital with tonic-clonic seizures. He was apparently healthy until one month previously when he had a first seizure. There was a significant history of contact with pet animals, especially dogs and horses. He reported to his local doctor and underwent investigations including a CT scan of the brain and carotid Doppler, which were reported as normal. His wife reported that he had become progressively disoriented and confused since then, and was bumping into things especially on the left side while walking. Clinical examination in the emergency department revealed an afebrile confused patient. There was no evidence of periodontal disease. The chest was clear to auscultation and cardiac sounds were dual with no murmurs. A limited neurological examination showed equal and reactive pupils along with weakness of the left side of the body with a grade 2 power. The reflexes were found to be exaggerated on the left side with an extensor plantar reflex on the same side. He was admitted for further evaluation and loaded with Phenytoin to prevent further seizures. Routine blood tests were normal with a total white cell count of 10.9 cells/mm³ and hemoglobin of 15.4 gram/deciliter. Electrolytes were within normal limits with sodium of 134 millimol/liter (mmol/l) and potassium of 5.2

Disclosure. The authors hereby declare that this work is original, with no conflicts of interest and has not received any external financial support.

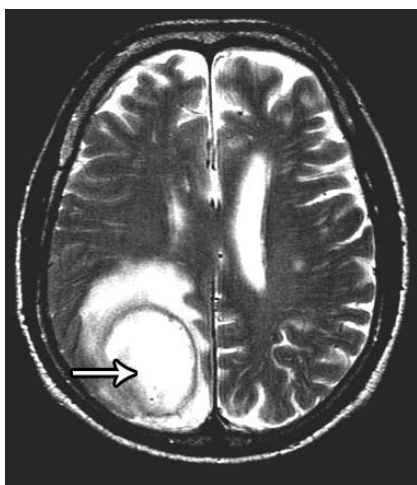


Figure 1 - Axial T2 flair MRI showing the abscess in the right posterior parietal lobe.

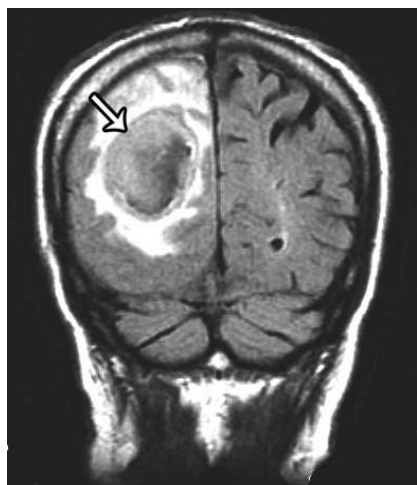


Figure 2 - Coronal T2 flair image showing the abscess.

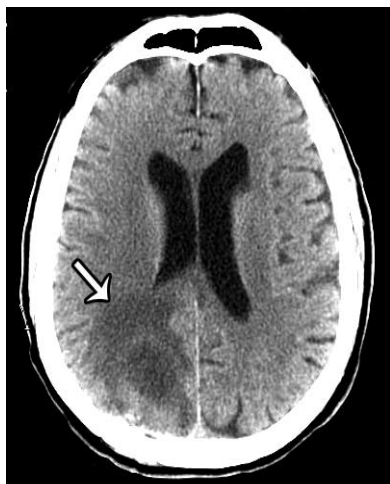


Figure 3 - The CT scan of brain 12 days after drainage.

mmol/L. Inflammatory markers were also within normal limits with an erythrocyte sedimentation rate of 17 mm/hour and C-reactive protein of 7 milligram/litre (mg/L). An arrangement was made for an MRI of the brain on an urgent basis. He continued to be confused and disoriented overnight and required sedation with midazolam. An MRI of the brain was reported to show a peripherally enhancing mass in the right posterior parietal lobe with maximum diameter of 4 x 5.5 cms and 4.9 cms in cranio-caudal length (Figures 1 & 2). The peripheral rim of enhancement measured up to 5 mm in diameter. The central portion of the mass showed a slightly lower signal than the surrounding area suggesting possible necrosis. There was a moderate amount of vasogenic edema surrounding the mass without causing a midline shift. The differential diagnosis at this point based on clinical and radiological features rested between a brain tumor and cerebral abscess. He was transferred to the neurosurgery department of a tertiary hospital where he underwent a posterior craniotomy, which revealed a cerebral abscess. The culture from the pus grew a *Haemophilus* species, which was further identified as *A. aphrophilus* using polymerase chain reaction (PCR). He was started on meropenem 2 grams 3 times a day, and metronidazole 500 mg 3 times daily. He underwent a transesophageal echocardiogram, which demonstrated only trivial aortic regurgitation without evidence of infective endocarditis. A CT of abdomen and chest performed to look for any other source of the abscess was reported as normal. He had a steady improvement clinically and underwent a CT scan after 10 days, which showed involution of the abscess cavity (Figure 3). The antibiotic regime was reduced to ceftriaxone 2 grams daily after 3 weeks and continued for a total of 6 weeks.

Discussion. *Aggregatibacter aphrophilus* (*A. aphrophilus*) is a small pleomorphic, non-motile, facultatively anaerobic gram-negative coccobacillus, which was previously classed under the *Haemophilus* species. *Haemophilus* require factor X, V factor, or both for their growth. These organisms are currently classified under the species of the genus *Aggregatibacter* as they are independent of factor X and variably dependent on factor V for their growth in vitro.³ In nutrient rich media such as chocolate agar, the bacteria forms characteristic star shaped colonies.⁴ The first description of *H. aphrophilus* as a pathogen appeared in 1940 when Khairat⁵ isolated the organism from a fatal case of endocarditis. This was followed by infrequent reports of the organism causing a variety of human infections including periodontal disease, brain abscess, vertebral osteomyelitis, and endocarditis. Congenital heart disease, dental procedures, and canine contacts

were considered as potential predisposing factors for infection with this organism. In a previous report, Page and King⁶ described a series of 9 cases of brain abscess caused by *H. aphrophilus*, most of which were associated with congenital heart disease. Huang et al⁷ reviewed 28 cases of *A. aphrophilus* infections and found that 39% had a recent dental procedure before the infection. Canine transmission has always aroused interest with these bacteria and there are reports of endocarditis and brain abscess linked with pet dogs.⁸ In a report on brain abscess caused by *A. aphrophilus*, Abla et al⁹ reported the isolation of the same organism from the mouth of the pet poodle of the patient.

Our patient was a previously healthy 73-year-old male. Retrospective questioning revealed that he had close contact with pet dogs and horses. However, attempts to isolate the organism from the pets were not successful. In addition, retrospective enquiry revealed that he had an intense flossing of his teeth a week before the onset of symptoms. It may well be possible that blood stream invasion happened from this procedure ultimately resulting in cerebral abscess. The culture of the aspirate from the brain abscess of our patient grew star shaped colonies suggesting *A. aphrophilus*. The organism was further identified using PCR restriction enzyme analysis. This method has been shown to be a reliable and rapid alternative to conventional methods for identification of this species.¹⁰

Clinical isolates of *Aggregatibacter* species have been quite sensitive to a variety of antibiotics including penicillin, ampicillin, ciprofloxacin, and cephalosporins. The in vitro activities of these drugs against clinical isolates of *A. aphrophilus* has been excellent, whereas those of oxacillin, erythromycin, and aminoglycosides are poor. Our patient responded well to meropenem and metronidazole and was subsequently de-escalated to ceftriaxone.

In conclusion, *H. aphrophilus* has been recently reclassified into *Aggregatibacter* species. *Aggregatibacter aphrophilus* is a rare cause for human disease. However, more and more cases of infections with these organisms are being recognized. Canine contact and dental

procedures seem to be risk factors for these infections. Prompt recognition and treatment leads to excellent outcomes in these patients.

Acknowledgment. The authors would like to thank Dr. Abe Matheu, Registrar in Medicine for his contribution to this article. The authors would also like to thank Dr. S. Khandelwal for reviewing the MRI pictures.

References

1. Tunkel AR. Brain abscess. In: Mandell GL, Bennett JE, Dolin R. Mandell, Douglas, and Bennett's Principles and Practice of Infectious diseases. 6th ed. Philadelphia (PA): Churchill Livingstone; 2006. p. 1150-1163.
2. Hand WL. Haemophilus Infections: In: Mandell GL, Bennett JE, Dolin R. Mandell, Douglas, and Bennett's Principles and Practice of Infectious diseases. 6th ed. Philadelphia (PA): Churchill Livingstone; 2006. p. 2661-2668.
3. Nørskov-Lauritsen N, Kilian M. Reclassification of *Actinobacillus actinomycetemcomitans*, *Haemophilus aphrophilus*, *Haemophilus paraphrophilus* and *Haemophilus segnis* as *Aggregatibacter actinomycetemcomitans* gen. nov., comb. nov., *Aggregatibacter aphrophilus* comb. nov. and *Aggregatibacter segnis* comb. nov., and emended description of *Aggregatibacter aphrophilus* to include V factor-dependent and V factor-independent isolates. *Int J Syst Evol Microbiol* 2006; 56: 2135-2146.
4. Lampe AS, Schroijen MA, Smith SJ. [Endocarditis due to *Aggregatibacter* (formerly: *Actinobacillus*) *actinomycetemcomitans*, a bacterium that grows in characteristic star shaped colonies] *Ned Tijdschr Geneesk* 2008; 152: 827-830. Dutch.
5. Khairat O. Endocarditis due to a new species of *Haemophilus*. *J Pathol Bacteriol* 1940; 50: 497-505.
6. Page MI, King EO. Infection due to *Actinobacillus actinomycetemcomitans* and *Haemophilus aphrophilus*. *N Engl J Med* 1966; 275: 181-188.
7. Huang ST, Lee HC, Lee NY, Liu KH, Ko WC. Clinical characteristics of invasive *Haemophilus aphrophilus* infections. *J Microbiol Immunol Infect* 2005; 38: 271-276.
8. Varghese R, Melo JC, Barnwell P, Chun CH, Raff MJ. Endocarditis due to *Haemophilus aphrophilus*: report of a case with possible transmission from dog to man. *Chest* 1977; 72: 680-682.
9. Abla AA, Maroon JC, Slifkin M. Brain abscess due to *Haemophilus aphrophilus*: possible canine transmission. *Neurosurgery* 1986; 19: 123-124.
10. Riggio MP, Lennon A. Rapid identification of *Actinobacillus actinomycetemcomitans*, *Haemophilus aphrophilus*, and *Haemophilus paraphrophilus* by restriction enzyme analysis of PCR-amplified 16S rRNA genes. *J Clin Microbiol* 1997; 35: 1630-1632.