

Zoster myelitis in sickle cell anemia

Yahya M. Mousali, MD, SBN, Ennam M. Sobhi, MRCPI, MRCPath, Seraj O. Makkawi, MBBS.

ABSTRACT

لقد دخلت المريضة التي تبلغ من العمر 17 عاماً والتي كانت مصابة بمرض أنيميا الخلية المنجلية إلى المستشفى وهي تشكو من ارتفاع في درجة الحرارة، والقيء، وآلام بضم المعدة لمدة 10 أيام، وقد وصلت درجة حرارتها إلى 38 درجة مئوية. كانت المريضة تعاني من الطفح الجلدي من النوع الحويصلي أسفل حلمة الثدي، وأعلى جانب الصدر الأيسر ويمتد إلى الظهر أيضاً. تم تشخيص حالتها على أنها مصابة بالحزام الناري، وبدأت بأخذ عقار (Acyclovir)، مع التروية الجيدة والمسكنات. وبعد مرور 3 أيام بدأت المريضة تشعر بضعف وتناقص بالإحساس بالساق اليمنى، وعند فحصها في اليوم 5 كانت درجة القوة 1/5 بالساق اليمنى و4/5 بالساق اليسرى، بالإضافة إلى زيادة توتر العضلة، وكان اتجاه أصبع القدم بالرجل اليمنى إلى الأعلى، والمستوى الحسي الحركي على مستوى الفقرة الصدرية الرابعة والفقرة الصدرية السادسة. أظهرت الأشعة باستخدام الرنين المغناطيسي وجود إشارة زائدة عند مستوى الفقرة الصدرية الرابعة والفقرة الصدرية السادسة. وقد أسفر تحليل السائل الشوكي عن ظهور الحمض النووي للفيروس النطاقي الحمائي. وعولجت المريضة باستخدام عقار (Dexamethasone) بمعدل 4 ملجم 4 مرات يومياً بالوريد. وبعد ثلاثة أيام من العلاج أصيبت المريضة بضعف بالساق اليسرى وسلس بولي، وكانت قوة الساق اليسرى 3/5، وأصبعي القدمين متجهة إلى الأعلى، مع مستوى حسي حركي عند مستوى حلمة الثدي (T4)، ولهذا أعطيت جرام واحد من عقار (methylprednisolone) لمدة 3 أيام، وأصبحت بعد أسبوع واحد قادرة على السير. ترجع حالة التهاب النخاع الشوكي المستعرض إلى الفيروس النطاقي الحمائي مع الإصابة بأنيميا الخلية المنجلية. ولقد تم علاجها باستخدام جرعة عالية من عقار (Methylprednisolone)، و (Acyclovir) عن طريق الوريد بالإضافة إلى العلاج الطبيعي.

A 17-year-old female patient, known case of sickle cell anemia was admitted to our hospital with 10 days history of fever, vomiting, and epigastric pain. On examination, her temperature was 38°C. There was a vesicular type of rash below the nipple and over the left chest involving the back. She was diagnosed as herpes zoster and was started on acyclovir with good hydration and analgesia. Three days later, she developed weakness and decreased sensation of the right leg. On the fifth day, examination revealed power of 1/5 on the right leg, and 4/5 on the left leg, there was proximal and distal increased tone and brisk reflexes and up going toe on the right side with sensory level at T4-T6. An MRI of the thoracolumbar spine showed high signal intensity at T4-T6. The CSF

analysis revealed positive polymerase chain reaction for varicella zoster. She was treated with intravenous (IV) dexamethasone 4 mg, 4 times per day. After 3 days she developed left leg weakness, urine incontinence, and power in the left leg was 3/5. Reflex plantar was up going bilaterally with sensory level at the nipple, T4-T6. She was then started on IV methylprednisolone one gm for 3 days followed by a tapering dose of prednisolone 50 mg for 2 weeks, after a week of starting medication she was able to walk. This case of transverse myelitis is related to varicella zoster infection, with sickle cell anemia, and was successfully treated with high dose IV methylprednisolone, IV acyclovir, and physiotherapy.

Neurosciences 2011; Vol. 16 (3): 273-275

From the Departments of Neurology (Mousali, Makkawi), and Hematology/Oncology (Sobhi), King Khalid National Guard Hospital, Jeddah, Kingdom of Saudi Arabia.

Received 8th November 2010. Accepted 7th March 2011.

Address correspondence and reprint request to: Dr. Yahya M. Mousali, Department of Neurology, King Khalid National Guard Hospital, PO Box 40923, Jeddah 21511, Kingdom of Saudi Arabia. Tel. +966 505682241. E-mail: ymousali@hotmail.com

Varicella zoster infection (VZI) is a mild viral disease in immuno-competent patients. It leads to neurological complications in approximately 2 of 10,000 cases.¹ It invades through the mucus membrane of the upper respiratory tract and the conjunctiva, and replication occurs at the primary inoculation site. Viremia may occur within 4-5 days after the spread of the virus in the body.² It involves the entire thickness of the cord and leads to loss of motor and sensory function below the injury. It could be acute lasting 4 hours to 2 days, or sub-acute lasting for 1-2 weeks.³ Although it is described as self-limiting, immuno-compromised individuals often suffer fatal myelopathy, encephalitis, cerebellitis, myelitis, meningitis cerebral ataxia, and radiculoneuropathy.⁴ Both the pathology and virology indicate the direct invasion of the spinal cord.⁵ We report a case of transverse myelitis (TM) as a complication of VZI in a patient with a compromised immune system due to sickle cell disease (SCD) who recovered completely. Our objective in presenting this particular case is to document the very rare association as

prompt treatment is of paramount importance in such situations.

Case Report. A 17-year-old lady, a known case of sickle cell anemia since childhood on hydroxyurea, was admitted to the hospital with 10 days history of fever, vomiting, epigastric pain, body aches, and skin rash over the middle part of the left side of the chest. On examination, she was ill looking with a temperature of 38°C, respiratory rate of 20/min, heart rate of 112/min, and blood pressure 97/56 mm Hg with mild jaundice and pallor. Her chest, cardiovascular including abdomen, and neurological examination were unremarkable, with no meningeal signs. There was a vesicular type of rash below the nipple and over the left chest involving the back as well (Figure 1). She was diagnosed as herpes zoster and was started on acyclovir with good hydration and analgesia. On the third day of admission, she started to develop weakness and decreased sensation of the right leg. The possibility of CNS sickle cell crises was suspected

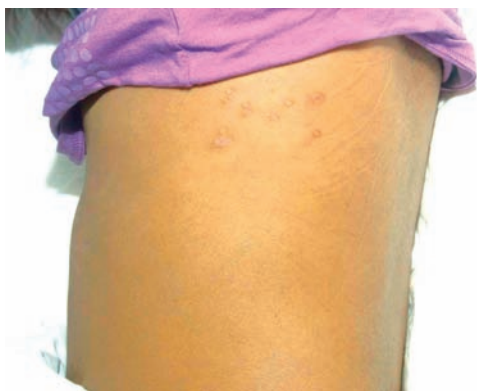

Figure 1 - Post inflammatory maculopapular lesions below the nipple on the left side at the T6 dermatome.

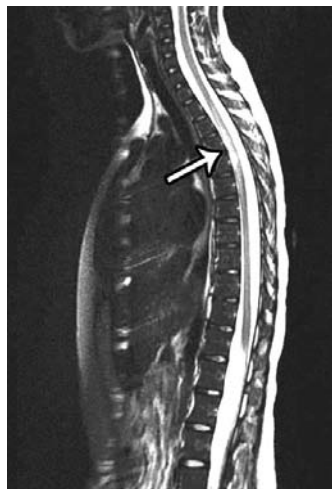


Figure 2 - Patient MRI sagittal T2 of dorsal spine showing high signal intensity of the cord at the T4 to T6 level.

by the hematologist and immediate total blood exchange was carried out once by an automated machine. However, her symptoms progressed over the next 2 days and she was referred to Neurology. On examination, she revealed power of 1/5 on the right leg, and 4/5 on the left leg, proximal and distal, brisk reflexes and up going toe on the right side with sensory level at T4-T6. An MRI of the thoracolumbar spine showed high signal intensity at T4-T6 (Figure 2). The CSF opening pressure was 19 cm, white blood cells (WBC) 4/mm³, protein one g/L, and glucose was normal. A polymerase chain reaction (PCR) for varicella zoster in the CSF was positive (Bioscientia, Ingelheim, Germany) and the oligoclonal band was negative. The blood test for brucella antibody was negative, serology for cytomegalovirus, Epstein Barr virus, and HIV in the blood were also negative. She was treated with intravenous (IV) dexamethasone 4 mg, 4 times per day. After 3 days of treatment, she developed weakness in the left leg and urine incontinence, with power in the left leg of 3/5. Reflex plantar was up going bilaterally, with sensory level at the nipple, T4. The dexamethasone was stopped, and she was switched to IV methylprednisolone one gm for 3 days followed by a tapering dose of prednisolone 50 mg for the next 10 days. After a week, she could walk with minimal assistance.

Discussion. We present a report of TM due to VZI in a patient with SCD. The diagnosis was made based on skin vesicular lesions and PCR for VZI. The antibody for VZI, which is highly specific, but less sensitive was positive.^{5,6} This case emphasizes the importance of looking for VZI as a cause of myelopathy. Transverse myelitis in immuno-compromised patients can be associated with paraparesis and sensory level, and sphincter dysfunction.³ The pathology that caused the neurological complication post-infection was TM presumed due to invasion of the virus directly, or due to vasculitis.⁷ In the case of an immune-compromised patient, the typical course of the disease is protracted, progressive, and fatal.⁸ These patients develop central and root pain as well as often segmented, bilateral motor and sensory signs, indicating spinothalamic and post-column involvement.³ Sickle cell anemia is inherited, characterized as a single amino acid change in the beta chain of the hemoglobin molecule resulting in red cell rigidity and causing poor micro-vesicular blood flow as well as tissue infarction.⁹ Patients with SCD are more susceptible to infections due to their lowered immunity as a result of an acquired functional asplenia, associated with inefficient phagocytosis of opsonized bacteria outside of the spleen.¹⁰ However, whether other components of the immune system, including cellular immunity, are also compromised has been debated.¹¹ Long term use of hydroxyurea also may have a role in lowering the cellular immunity causing opportunistic infection.¹² Finally, multiple transfusions

for patients with SCD, or long term hydroxyurea might induce a dysfunction of cell-mediated immunity.¹² She was initially treated with (IV) dexamethasone and IV acyclovir, then the dexamethasone was stopped when the left leg became weaker and urinary incontinence developed. Methylprednisolone (IV) was added as it has better penetration than dexamethasone with more mineralocorticoid, this led to rapid recovery.¹³

In conclusion, immuno-compromised patients generally have a different course of disease with usually poorer overall prognosis. This is a case of TM, related to VZI, with SCD-associated immuno-suppression successfully treated with high dose IV methylprednisolone, IV acyclovir, and physiotherapy. Moreover, we further recommend a booster dose of varicella zoster vaccine in sickle cell patients.

References

1. Guess HA, Broughton DD, Melton LJ 3rd, Kurland LT. Population-based studies of varicella complications. *Paediatrics* 1986; 78: 723-727.
2. Amlie-Lefond C, Jubelt B. Neurologic manifestations of varicella zoster virus infections. *Curr Neurol Neurosci Rep* 2009; 9: 430-434.
3. Yılmaz S, Köseolu HK, Yücel E. Transverse myelitis caused by varicella zoster: case reports. *Braz J Infect Dis* 2007; 11: 179-181.
4. Gildeen DH, Kleinschmidt-DeMasters BK, LaGuardia JJ, Mahalingam R, Cohrs RJ. Neurologic complications of the reactivation of varicella-zoster virus. *N Engl J Med* 2000; 342: 635-645.
5. Stránská R, Schuurman R, de Vos M, van Loon AM. Routine use of a highly automated and internally controlled real-time PCR assay for the diagnosis of herpes simplex and varicella-zoster virus infections. *J Clin Virol* 2003; 30: 39-44.
6. Mayo DR, Booss J. Varicella zoster-associated neurologic disease without skin lesions. *Arch Neurol* 1989; 46: 313-315.
7. Gildeen DH, Beinlich BR, Rubinstien EM, Stommel E, Swenson R, Rubinstein D, et al. Varicella-zoster virus myelitis: an expanding spectrum. *Neurology* 1994; 44: 1818-1823.
8. de Silva SM, Mark AS, Gildeen DH, Mahalingam R, Balish M, Sandbrink F, et al. Zoster myelitis: improvement with antiviral therapy in two cases. *Neurology* 1996; 47: 929-931.
9. Kato GJ, Hebbel RP, Steinberg MH, Gladwin MT. Vasculopathy in sickle cell disease: Biology, pathophysiology, genetics, translational medicine, and new research directions. *Am J Hematol* 2009; 84: 618-625.
10. Bjornson AB, Lobel JS, Harr KS. Relation between serum opsonic activity for *Streptococcus pneumoniae* and complement function in sickle cell disease. *J Infect Dis* 1985; 152: 701-709.
11. Wong WY, Overturf GD, Powars DR. Infection caused by *Streptococcus pneumoniae* in children with sickle cell disease: epidemiology, immunologic mechanisms, prophylaxis, and vaccination. *Clin Infect Dis* 1992; 14: 1124-1136.
12. Venigalla P, Motwani B, Allen S, Agarwal M, Alva M, Westerman M, et al. A patient on hydroxyurea for sickle cell disease who developed an opportunistic infection. *Blood* 2002; 100: 363.
13. Hari P, Srivastava RN. Pulse corticosteroid therapy with methylprednisolone or dexamethasone. *Indian J Pediatr* 1998; 65: 557-560.

COPYRIGHT

Whenever a manuscript contains material (tables, figures, etc.) which is protected by copyright (previously published), it is the obligation of the author to obtain written permission from the holder of the copyright (usually the publisher) to reproduce the material in Neurosciences. This also applies if the material is the authors own work. Please submit copies of the material from the source in which it was first published.