

Giant occipital osteoid osteoma mimicking calcified meningioma

Fuat Erten, MD, Askin E. Hasturk, MD, Isin Pak, MD, Omer Sokmen, MD.

ABSTRACT

بعد العظموم التعاظمي من أورام العظام الحميدة التي يندر ظهورها في الجمجمة، وغالباً ما تسبب ألماً يزداد شدته أثناء الليل ويمكن تخفيفه بتناول الأسبرين. ويعد ظهور العظموم التعاظمي الكبير الحجم في العظم القذالي من الأمور النادرة الحدوث. نستعرض في هذا المقال حالة نادرة لمريضة تبلغ من العمر 42 عاماً، وكانت تعاني من العظموم التعاظمي في منطقة العظم القذالي والذي تم استئصاله كلياً. لقد قمنا في هذا المقال بمراجعة المظاهر السريرية، ونتائج صور الأشعة، واختلاف تشخيص العظموم التعاظمي في العظم القذالي.

Osteoid osteoma is a benign bone tumor, which rarely occurs in the skull, and often causes local pain that is worse at night, characteristically relieved by aspirin. Giant osteoid osteoma in the occipital bone is uncommon. We present a case of a 42-year-old female with an osteoid osteoma of the occipital bone that was totally resected. We discuss the clinical presentation, radiographic findings, and differential diagnosis of occipital osteoid osteoma.

Neurosciences 2011; Vol. 16 (4): 363-365

From the Department of Neurosurgery (Erten, Hasturk, Sokmen) and the Department of Pathology (Pak), Dr. Abdurrahman Yurtaslan Oncology Training and Research Hospital, Ankara, Turkey.

Received 16th March 2011. Accepted 25th May 2011.

Address correspondence and reprint request to: Dr. Askin E. Hasturk, Department of Neurosurgery, Dr. Abdurrahman Yurtaslan Oncology Training and Research Hospital, Ankara, Turkey. Tel. +90 5337282904. Fax. +90 (312) 3363439. E-mail: aehasturk@yahoo.com

Osteoid osteoma is a rarely seen benign osteoblastic bone lesion especially involving the long bones of the lower extremities.^{1,2} Although cranial involvement is rare, osteoid osteoma is frequently seen at the base of the skull. They may be misdiagnosed as osseous meningiomas. However, osteomas do not have a soft tissue component, do not enhance, and demonstrate signal void on all MRI sequences. Osteomas are solid

nodular sclerotic lesions usually arising from the outer table and are usually <1 cm.³⁻⁵ In this report, we present a case with giant osteoid osteoma of the occipital bones, compressing the cerebellum and infiltrating the venous sinuses. Our objective in presenting this particular case is to highlight the imaging features and emphasize the importance of imaging in the diagnosis of unusual locations.

Case Report. A 42-year-old female patient presented to our clinic with the complaint of dizziness and imbalance. The patient's complaints gradually increased over the last 5 years. A palpable swelling was detected under the scalp in the left occipital region. She presented with the clinical signs of raised intracranial pressure, dysmetria, and dysdiadochokinesia were detected on the left side during neurological examination. A giant calcified mass extending into and out of a 7.5 x 7 cm sized calvarium on the left occipital bone was revealed with a CT scan of the brain. The mass was observed to be applying pressure on the left cerebellar hemisphere (Figures 1a & 1b). On cranial MRI, the lesion did not have a soft tissue component and showed a non-contrast enhancing mass spreading into and out of the cranium (Figure 2). The tumor in the left occipital bone was totally resected by surgery. The rupture in the left sigmoid sinus wall where the bone was attached was repaired. Histopathologic examination confirmed the diagnosis of an osteoma (Figure 3). Postoperative MRI did not show residual disease (Figures 4a & 4b). The patient's vertigo improved in the postoperative period.

Discussion. Osteoid osteoma is a benign osteoblastic bone lesion. It generates 1% of all bone tumors and 11% of benign bone lesions.^{1,3,4,6} The most common age groups are the second and third decades. It is more common in males.^{2,3,5} The long bones of the lower limbs and vertebrae are often involved. It usually presents in the epiphyseal region. The most common locations are cortex (85%), spongiosa (13%), and subperiosteal region (2%). Although cranial cases usually spread along the base of the skull, it is quite rare.^{1,2,6,7} Frontal and ethmoidal sinus involvement have been reported.^{2,3}

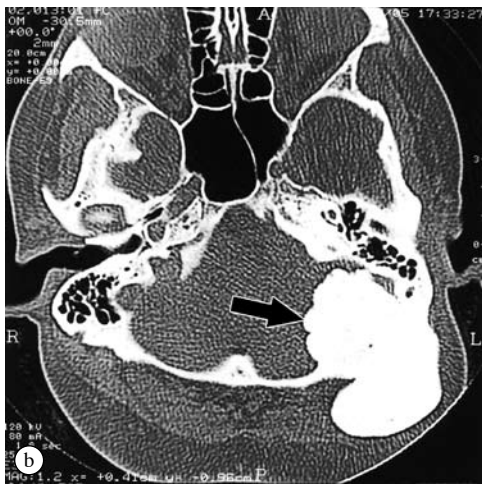
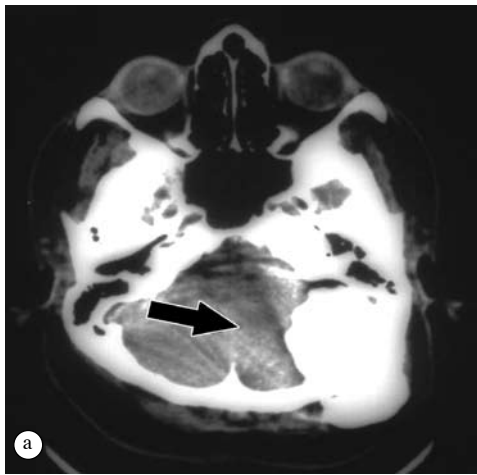

Figure 1 - Non-contrast axial CT shows a) a calcified mass that is pressing on the cerebellum and, b) spreading out of the calvarium.

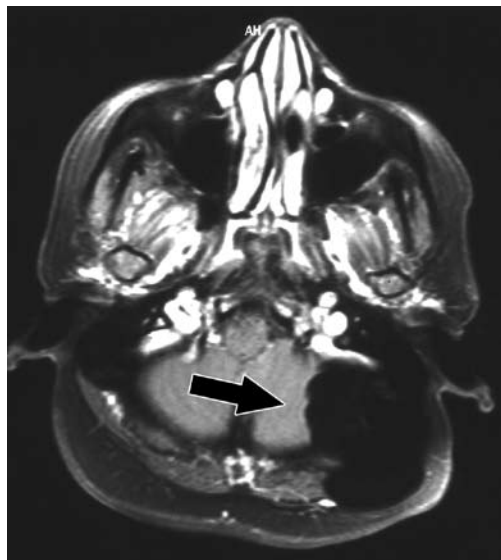

Figure 2 - A contrast-enhanced axial cranial MRI shows a non-enhancing mass spreading into and out of the cranium.

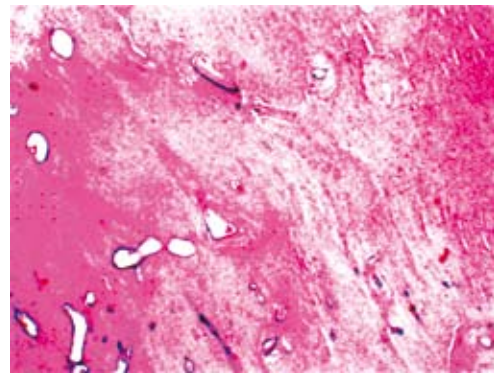


Figure 3 - The appearance of osteocytes in bone matrix (Hematoxylin & Eosin x 40).

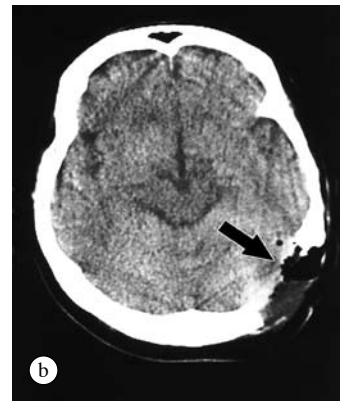
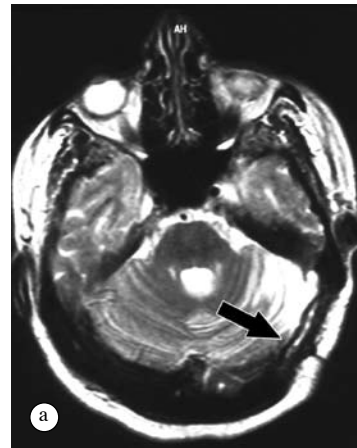


Figure 4 - A postoperative a) contrast-enhanced cranial MRI and b) CT shows that the mass was totally excised.

Osteoid osteoma can present with neurological deficits due to mass effect and involvement of nervous structures.^{1,3,5} Patients typically complain of localized, sharp pain especially at night. The radiological diagnosis is established by tomography and isotope bone scan.^{2,4,5} The differential diagnosis is made and the affects of pressure on surrounding tissues can be seen with MRI. A radiopaque lesion and nidus can be seen with direct

radiography.¹⁻³ The size of the lesion depends on the age of onset and the diagnosis period of the disease. A 10x9x5 cm sized giant occipital osteoma was reported in the literature.² In our case, it is a rare osteoma tumor localized in the occipital region. Differential diagnosis of the calvarial lesions is important in order to decide whether biopsy, surgical intervention, or follow-up is essential for further management.^{2,5,7} Meningiomas are most often located near the coronal suture. Meningiomas usually present in middle-aged women and lead to irregularity in the inner table, whereas in fibrous dysplasia, the inner table is not affected. The first step in radiological evaluation of the calvarium is plain radiography, where lesions might be evaluated as lytic or sclerotic.^{1,4,8} Calvarial lesions, lytic or sclerotic patterns, contours of the lesions, calcifications, soft tissue components, inner and outer table localizations were evaluated with CT. On MRI, signal characteristics and contrast enhancement of the lesion, relation to brain parenchyma, and soft tissue were evaluated.^{3,4,6,7} Well defined borders and sclerotic margins are characteristic of osteoid osteoma. Slow-growing tumors lead to thinning in the neighboring calvarium, whereas aggressive tumors lead to dramatic destruction.^{1,3,4} On MRI, the inner and outer tables are seen as signal void. Lesions are hypointense on T1-weighted images and hyperintense on T2-weighted images, and they enhance with contrast. Histologically, the nidus is separated from the thick layer of the surrounding bone with sharp boundaries. This structure is formed by osteoids that are a little or largely calcified and surrounded by osteoids within connective tissue stroma that is rich in blood vessels. They usually do not spread into surrounding tissues and transform into malignancy.^{1,3,4} Treatment usually involves excision of the total tumor. Osteoid osteoma can present with neurological deficit due to mass effect and involvement

of vital structures. Radical excision can be performed for evaluation of symptoms and pain. Incompletely excised tumors have a recurrence rate of 10%.^{2,3,5} If asymptomatic, the patient is managed conservatively with periodic follow-up.²⁻⁴

In conclusion, giant osteoid osteoma is rarely seen in the literature. The adhesion of the surrounding brain tissue and vascular structures should be taken into consideration during the radical excision of the large sized tumors. In the differential diagnosis, it may be confused with meningioma due to the radiological similarities and its location. Unlike meningiomas, osteomas do not have a soft tissue component, do not enhance, and demonstrate signal void on all MRI sequences.

References

1. Cayli SR, Beşkonaklı E, Günçe S, Güç T. Osteoid osteoma of the frontal bone. Case report. *Zentralbl Neurochir* 1998; 59: 132-134.
2. Grayeli AB, Redondo A, Sterkers O. Anterior skull base osteoid osteoma: case report. *Br J Neurosurg* 1998; 12: 173-175.
3. Layadi F, Aniba K, Lmejjati M, Ait Elqadi A, Ait Benali S. Giant osteoid osteoma of the posterior skull base. A case report and literature review. *Neurochirurgie* 2006; 52: 128-132.
4. Pai SB, Harish K, Venkatesh MS, Udayshankar, Jermely D. Ethmoidal osteoid osteoma with orbital and intracranial extension - a case report. *BMC Ear Nose Throat Disord* 2005; 5: 2.
5. Neff S, Hansen K, Domanowski GF, Wu JL. Cryptic osteoid osteoma of the cranium: case report. *Neurosurgery* 1990; 27: 820-821.
6. Arana E, Martí-Bonmatí L. CT and MR imaging of focal calvarial lesions. *AJR Am J Roentgenol* 1999; 172: 1683-1688.
7. Amaral L, Chiurciu M, Almeida JR, Ferreira NF, Mendonça R, Lima SS. MR imaging for evaluation of lesions of the cranial vault: a pictorial essay. *Arq Neuropsiquiatr* 2003; 61: 521-532.
8. Tokgoz N, Oner YA, Kaymaz M, Ucar M, Yilmaz G, Tali TE. Primary intraosseous meningioma: CT and MRI appearance. *AJNR Am J Neuroradiol* 2005; 26: 2053-2056.

CASE REPORTS

Case reports will only be considered for unusual topics that add something new to the literature. All Case Reports should include at least one figure. Written informed consent for publication must accompany any photograph in which the subject can be identified. Figures should be submitted with a 300 dpi resolution when submitting electronically or printed on high-contrast glossy paper when submitting print copies. The abstract should be unstructured, and the introductory section should always include the objective and reason why the author is presenting this particular case. References should be up to date, preferably not exceeding 15.