

Endovascular treatment of an intracranial aneurysm with a ruptured bleb

Jin-Lu Yu, MD, Hong-Lei Wang, MD, Kan Xu, MD, Bai Wang, MD, Qi Luo, MD.

ABSTRACT

الأهداف: دراسة خصائص العلاج من داخل الشرايين لأم الدم داخل القحف والمصابة بتمزق الفقاعة.

الطريقة: أُجريت هذه الدراسة الاسترجاعية في جامعة جيلين، جيلين، الصين وذلك خلال الفترة من يونيو 2007م إلى يونيو 2009م. شملت الدراسة 30 مريض مصاب بأم الدم داخل القحف مع تمزق في الفقاعة. لقد قمنا بتشخيص أم الدم من خلال تصوير القنوات الصفراء بالطرح الرقمي، فيما قمنا بتخطيط العلاج من داخل الشرايين اعتماداً على العلاقة بين حجم أم الدم والفقاعة المتمزقة. وقمنا بتصنيف أم الدم إلى 4 أنواع (نوع 1، ونوع 2، ونوع 3، ونوع 4) وذلك اعتماداً على كل من: حجم العنق الواصل بين أم الدم والشريان الأم، وحجم جسم أم الدم، وحجم الوصلة بين أم الدم والفقاعة. وبعد ذلك قمنا بإجراء العلاج من داخل الشرايين لكل نوع من أنواع أم الدم.

النتائج: أشارت نتائج الدراسة إلى أن العملية التي أُجريت لأم الدم من النوع 4 كانت من أصعب العمليات والتي أدت إلى نزيف وتمزق، فيما كانت عملية إصمام أم الدم من النوع 3 بسيطة. وقد كانت نتائج العمليات الجراحية لأم الدم من النوع 1 و 2 أفضل بكثير من الأنواع الأخرى. وأظهرت نتائج التحليل الإحصائي بأن نتائج العلاج لأم الدم من النوع 1 و 2 قد كانت أفضل من نتائج علاج أم الدم من النوعين 3 و 4، كما كانت نتائج علاج أم الدم من النوع 1 و 2 و 3 أفضل من أم الدم من النوع 4.

خاتمة: أثبتت الدراسة اعتماد نتائج العلاج من داخل الشرايين لأم الدم داخل القحف مع تمزق الفقاعة على نوع أم الدم. ولهذا فإننا ننصح بتحديد العلاج اعتماداً على نوع أم الدم.

Objective: To study the features and approaches of endovascular treatment for intracranial aneurysms with a ruptured bleb.

Methods: This retrospective study was carried out from June 2007 to June 2009 in Jilin University, Jilin, China. Thirty patients with intracranial aneurysms with ruptured blebs were included. The aneurysms were diagnosed by digital subtraction angiography (DSA), and the endovascular treatment was planned according

to the relationship between the aneurysm body and the ruptured bleb. The aneurysms were classified into 4 types (type I, II, III, IV) based on the size of the neck of the aneurysm connected with the parent artery, the size of the body of the aneurysm, and the size of the junction formed between the aneurysm and bleb. Endovascular treatment for each type of aneurysm was performed.

Results: Type IV aneurysms were the most difficult operation performed, easily resulting in rupture and bleeding during surgery, whereas embolization of a type III aneurysm was relatively simple. Type I and II aneurysms resulted in better prognosis. Statistical analysis showed that the outcome of the treatment of type I and II aneurysms was better than that in type III and IV aneurysms, the outcome of type I, II, and III was better than that in type IV.

Conclusion: The outcome of the endovascular treatment of an intracranial aneurysm with a ruptured bleb was related to the aneurysm type. Treatment in a type-dependent manner is therefore recommended.

Neurosciences 2012; Vol. 17 (2): 127-132

From the Departments of Neurosurgery (Yu, Wang, Xu, Luo), and Radiology (Wang), The First Hospital of Jilin University, Changchun, China.

Received 1st May 2011. Accepted 26th December 2011.

Address correspondence and reprint request to: Dr. Qi Luo, Department of Neurosurgery, The First Hospital of Jilin University, 71 Xin Min Street, Changchun, Jilin 130021, China. Tel/Fax: +86 043188782331. E-mail: luoqi@jlu.edu.cn

Intracranial aneurysms often become bigger and bigger under the impact of blood flow. During the enlargement of aneurysms, their shape becomes irregular, with blebs often appearing on the top of the aneurysms. These blebs are fragile and easily bleed, and

Disclosure. The authors declare no conflicting interests, support or funding from any drug company.

once they rupture, an aneurysm with ruptured blebs is formed.^{1,2} An intracranial aneurysm with ruptured blebs is difficult to treat due to its irregular shape and fragility. Moreover, the bleb often adheres to the surrounding blood clot, which makes clipping of the aneurysm difficult during surgery and usually results in a higher risk and more complications. Recently, endovascular treatment has been gradually adopted due to its low risk, minor invasion, and fewer complications, and it has the tendency to replace surgical treatment.³ However, coil embolization of this type of aneurysm is difficult as the coiling can result in intraoperative rupture due to the fragility of the bleb.⁴ It is known that an aneurysm with a ruptured bleb is composed of a body connected with the parent artery and a bleb on the top of the body.^{1,5} As the body of the aneurysm is stable, coil embolization can be controlled in the body of the aneurysm, and such a structure provides an anatomical basis for safe endovascular treatment. Since the size of the junction between the body of the aneurysm and the bleb determines whether the coils go into the bleb or not, for intracranial aneurysm with ruptured bleb the junction also plays a critical role in endovascular treatment. Recently, there have been a lot of reports of ruptured intracranial aneurysms, and in these studies, some new techniques, and products have been applied to the ruptured intracranial aneurysms. However, these studies often emphasize the prognosis and some complications, for example, Sakai et al⁶ retrospectively surveyed the endovascular treatment of ruptured intracranial aneurysm in Japan. To date, the features and approaches of endovascular treatment for this type of aneurysm have not been thoroughly reported, and thus, the purpose of this study is to summarize our experience in endovascular treatment of aneurysms with a ruptured bleb, and to investigate factors associated with the prognoses following treatment.

Methods. The present study was conducted in accordance with international guidelines and the Helsinki Declaration. The Ethics Committee of the First Hospital of Jilin University, Jilin, China, approved the study, and patient consents were obtained.

Thirty patients were recruited between June 2007 and June 2009. They included 6 male, and 24 females, with an age range of 34-74 years (average 53.5). All patients had a subarachnoid hemorrhage (SAH), and the duration from onset to treatment was 1-45 days (average, 9.5 days). We used 2 classifications: the Hunt-Hess classification,⁷ of which there were 23 class II patients, 5 class III patients, and 2 class IV patients, and the Fisher classification,⁸ of which there were 23 class II

patients, 4 class III patients, and 3 class IV patients. The locations of the aneurysms were included as follows: anterior communication artery (AcomA) aneurysm (10 cases); posterior communication artery (PcomA) aneurysm (17 cases); posterior inferior cerebellar artery (PICA) aneurysm (one case); ophthalmic artery (OphA) aneurysm (one case); and a basilar artery bifurcation (BAB) aneurysm (one case).

Digital subtraction angiography (DSA) features. The following inclusion criteria were used for aneurysms with a ruptured bleb. (1) Computed tomography (CT): the bleeding site of SAH focused on the location of the aneurysms. (2) Morphology of the aneurysms: DSA revealed that the body of the aneurysm appeared either round or oval with a single cavity, connecting with a ruptured bleb, which made the aneurysm appear irregular. (3) Hemodynamics of the aneurysms: DSA examination revealed that turbulence and eddy currents coexisted within the aneurysms. Blood flow within the body of the aneurysm was classified as turbulent, whereas blood flow within the bleb was known as an eddy current.⁹ Exclusion criteria included regular-shaped aneurysms without blebs, although these aneurysms were ruptured and presented with SAH.

Classification. The diagnosis of the aneurysm with a ruptured bleb was confirmed using DSA, and a measurement was made to detect the size of the body of an aneurysm (D), the size at the neck of an aneurysm connected with a parent artery (N), and the size of the junction formed between the aneurysm and bleb (J). Based on the ratio of D, N, and J, aneurysms were divided into 4 types: type I, II, III, and IV (Figure 1). We devised the method of classification based on the method of classification of intracranial wide-necked aneurysms as previously described (Table 1).¹⁰

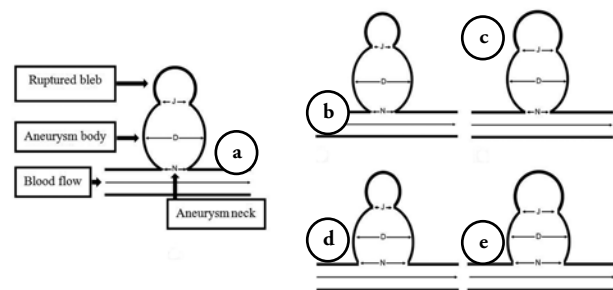


Figure 1 - Schematic drawing showing the classifications of the cranial aneurysms with a ruptured bleb. a) structures of a cranial aneurysms with a bleb formation, the size of the body of an aneurysm (D), the size at the neck of an aneurysm connected with a parent artery (N), and the size of the junction formed between an aneurysm and bleb (J). b) type I, c) type II, d) type III, and e) type IV.

Table 1 - Classification of the 4 types of aneurysm with a ruptured bleb based on the ratio of N/D and J/D.

Classification	N/D	J/D
Type I	$\leq 1/2$	$< 1/2$
Type II	$\leq 1/2$	$> 1/2$
Type III	$> 1/2$	$< 1/2$
Type IV	$> 1/2$	$> 1/2$

D is the size of the body of an aneurysm, N is the size at the neck of an aneurysm connected with a parent artery, and J is the size of the junction formed between the aneurysm and bleb

Treatment procedure. Patients were treated immediately using coil embolization once the diagnosis was made. During the time between onset of symptoms and coil embolization, intravenous infusion of Nimotop (4 mL/h, Bayer, Leverkusen, Germany) was performed to prevent vasospasm.¹¹ The patients with type III and type IV aneurysms needed stent-assisted embolization during surgery, and they were administered aspirin (325 mg once per rectum) at the beginning of the operation. The DSA was performed under the assistance of 3 dimensional (D) reconstruction. Endovascular embolization was performed based on the best results of the 3D reconstruction. Two-D, 3D, electrolytic, and hydrolytic coils with varied softness were utilized. For the treatment of type III and type IV aneurysms, the application of the Neuroform3TM-assisted stent or HyperglideTM- or HyperformTM-assisted balloons was dependent on the intraoperative conditions.

Strategies of coil embolization. Application of a 3D coil was the first choice to make a loop for the embolization of the aneurysm with a ruptured bleb. The loop was made in the body of the aneurysm. In type III and type IV aneurysms containing a wide neck, if the coil was unstable in the body of the aneurysm during embolization and went into the parent artery, a stent or balloon was advanced to the parent aneurysm to assist embolization. For embolization of type II and type IV aneurysms, coils could not make a loop in the body of the aneurysm since the junction connecting with the bleb was relatively wider. Instead, coils protruded into the bleb; therefore, the bleb should be carefully filled with the coils to prevent its rupture and bleeding. Moreover, once the coils gained enough support, they should be immediately pulled into the body of the aneurysm.

Statistical analysis. The Statistical Package for Social Sciences (SPSS Inc., Chicago, IL, US) version 10.0 was used to run statistical analyses. A fisher exact probability test was used to analyze the data and to make comparisons among different groups. The confidence Interval (CI) was set at 95%. The limit of statistical significance was set at $p < 0.05$.

Results. Prognosis of the endovascular treatment was determined using the Glasgow outcome scale (GOS).¹² The 5 categories of the scale were as follows: 5: good recovery; 4: moderate disability; 3: severe disability; 2: vegetative status; and one: death.

Type I and II aneurysm. Of the 10 cases presenting with type I aneurysm, 6 cases were PcomA aneurysms, and 4 cases were AcomA aneurysms. Embolization was all performed in the body of the aneurysm, and blebs were untreated in 6 cases. The embolization of the bleb was performed in 4 cases due to a clear visualization of the bleb by angiography (Figure 2). Of the 9 cases of type II aneurysms, 4 cases were PcomA aneurysms, 4 cases were AcomA aneurysms, and one case was a PICA aneurysm. In type II aneurysms, the first 3D coil was advanced to the bleb, followed by sequential embolization in the body of the aneurysm. The embolization in the type I II aneurysms was successful. The follow-up period was from half a year to one year. The final prognosis was found to be good (18 cases with GOS score 5; one case with GOS score 4). The follow-up DSA did not show recurrence of these aneurysms.

Type III aneurysm. Of the 7 cases of type III aneurysms, 4 cases were PcomA aneurysms, one case was an AcomA aneurysm, one case was an OphA aneurysm, and one case was a BAB aneurysm. Neuroform3TM stent-assisted embolization was performed in 6 cases, and HyperglideTM balloon-assisted embolization was used in one case. Embolization was all performed in the body of the aneurysm. Blebs were untreated in 5 cases. Due to a clear visualization of the blebs by angiography, the embolization of the bleb was performed in 2 cases. The rupture of an aneurysm and death following surgery occurred in one case. The surgeries in the rest of the 6 cases went well. The follow-up period lasted from a half year to one year, and the prognosis was good (GOS score: 5). The follow-up DSA did not show the recurrence of these aneurysms.

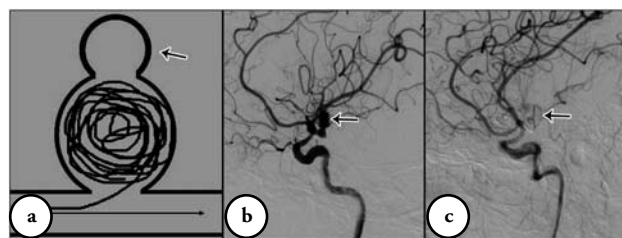


Figure 2 - Type I aneurysm with a bleb. a) schematic drawing showing type I aneurysm coiled, and the coils did not go into the bleb (arrow). b) Digital subtraction angiography showing a posterior communicating aneurysm with a bleb (arrow). c) Digital subtraction angiography showing the coil in the body of the aneurysm without coiling the bleb (arrow).

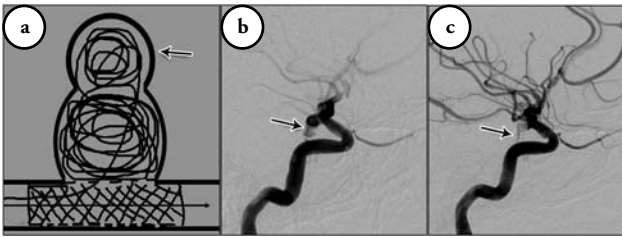


Figure 3 - Type IV aneurysm with a bleb. a) Schematic drawing showing that the body of type IV aneurysm was coiled with the assistance of the stent, and the coils went into the bleb (arrow). b) Digital subtraction angiography showed a wide-necked posterior communicating aneurysm with a big bleb (arrow). c) Digital subtraction angiography showed the bleb (arrow) was embolized, then the body of the aneurysm was embolized with the advanced stent.

Type IV aneurysm. Of the 4 cases with type IV aneurysms, 3 cases were PcomA aneurysms, and one case was an AcomA aneurysm. Neuroform3™ stent-assisted embolization was performed in 3 cases, and Hyperform™ balloon-assisted embolization was used in one case. Embolization by coils was firstly performed in the bleb in all 4 cases, then within the body of the aneurysms. Rupture during embolization and death after operation occurred in 2 cases (GOS score: one). In one of the remaining 2 cases, during embolization when the coil was pulled into the neck of the aneurysm, one loop of the coil entered the parent artery. After surgery, the patient was given an oral anticoagulant (Figure 3). The prognosis was good (GOS score 5). The follow-up period was from half a year to one year. Moreover, in all types of aneurysms examined, DSA revealed that no recanalization of aneurysms occurred.

Table 2 - Prognosis of endovascular treatment of 4 types of aneurysm between type I+II and type III+IV.

GOS score	Type I+II	Type III+IV
4 and 5	19	8
1	0	3

Fisher exact probability test showed that the prognosis of type I+II is better than type III+IV ($p=0.041$), GOS - Glasgow outcome scale

Table 3 - Prognosis of endovascular treatment of 4 types of aneurysm between type I+II+III and type IV.

GOS score	Type I+II+III	Type IV
4 and 5	25	2
1	1	2

Fisher exact probability test showed that the prognosis of type I+II+III is better than type IV ($p=0.039$), GOS - Glasgow outcome scale

Statistical analysis by a fisher exact probability test showed that the outcome of the treatment of type I and II aneurysms was better than that in type III and IV aneurysms ($p=0.041$), the outcome of type I, II, and III was better than that in type IV ($p=0.039$) (Tables 2 & 3). please double check results - different from table legends.

Discussion. Rebleeding easily occurs in a bleb, with treatment becoming necessary.^{1,4,5} As the aneurysm with a ruptured bleb contains part of the solid aneurysm wall in the body that should be enough for coiling, which provides the anatomic basis for endovascular treatments. Therefore, it is reasonable and also safe to embolize the aneurysm if coiling can be performed within the body of the aneurysm, and the coils do not slide into the blebs.

The embolization of aneurysms is influenced by many factors, with the width of the neck of an aneurysm being an important factor. Wide-necked aneurysms are often defined when the ratio of the body to the neck of the aneurysm is larger than half.¹³⁻¹⁵ For intracranial aneurysm with a ruptured bleb, in addition to the size of the neck of the aneurysm, the junction formed between the aneurysm and bleb also plays an important role.^{13,16} Regarding the endovascular treatment of this type of aneurysm, how to manipulate the junction is a key factor. When the junction is relatively wide, it is very hard to restrict the coil within the cavity of the body of the aneurysm and it can easily protrude into the blebs, leading to intraoperative rupture. In the present study, we referred to the same classification methods for the junction as that used for a wide-necked aneurysm; namely, the ratio of the size of the junction and the size of aneurysm body. We divided aneurysms into 4 types (type I, II, III, and IV). This type of aneurysm is common in clinical patients. Within the 2-year study period at our hospital, we retrospectively summarized 30 cases using endovascular treatment based on this classification.

In type I and II aneurysms, stent- or balloon-assisted embolization is not used due to the narrow neck of the aneurysm (N/D less than 1/2).¹⁷ Thus, the size of the junction formed between the aneurysm and bleb becomes the key to embolization treatment. In type I, due to the J/D being less than half, embolization was performed within the cavity of the body of the aneurysm, and the coil did not protrude into the bleb, making embolization of this type of aneurysm relatively easy. However, in this study, 4 out of 10 cases showed clear images of a bleb, and the body of the aneurysm was occluded, therefore, it was safe to embolize the ruptured

bleb together with the body of the aneurysm. In type II, it is very difficult to keep coils within the cavity of the body of the aneurysm during embolization due to the J/D being greater than half. In most cases, the first coil protruded into the bleb, if this occurs repetitively pulling the coils should be avoided, since the coils might extrude through the fragile wall of the bleb. Repetitive manipulation results in the rupture of an aneurysm and bleeding.¹⁸ Because the neck of the aneurysm from this type II is intact and narrow, coils should be pulled into the cavity of the body of the aneurysm. Once the coil enters the bleb, care should be taken during embolization of the bleb. To prevent rupture of a bleb, coils should be pulled into the cavity of the true aneurysm as quickly as possible once it gains enough support. Due to the N/D being less than half, the endovascular treatment of type I and type II aneurysms should be the only factor for consideration on how to manipulate the bleb to reduce the difficulty of endovascular treatment. There were a total of 19 cases of type I and II aneurysms, and all of the operations went well; moreover, postoperative recovery was satisfactory. The DSA revealed that no recannulation of the aneurysm occurred during follow-up.

In type III and IV aneurysms, complex techniques were used during embolization due to a wide neck of the aneurysm (N/D greater than 1/2).¹⁹ However, it is known that the application of complex techniques usually increases surgical risks and postoperative complications.²⁰⁻²² Compared to the treatment of type I and II aneurysms, during the embolization of type III and IV aneurysms, the neck of the aneurysm also needs to be treated. Consequently, these treatments increase the difficulty of endovascular treatment and increase the risk of complications. Out of 11 cases from the 2 types of aneurysms, the rupture of aneurysms and death occurred in 3 cases; whereas in type I and II, prognosis was good for 18 cases (out of 19 cases). The risk of complications in the patients with type III and IV classification is much higher than that from a non-wide-necked aneurysm. When considering the causes of complications during the embolization of the 2 types of aneurysms, the complications are not associated with stent-or balloon-assisted coils, but related to intraoperative rupture and bleeding. We believe that apart from the effect of the release of the stent or balloon on controlling the insertion of the catheter and guide wire,^{20,23,24} the causes of rupture might be from the effect of pre-operative and intraoperative anticoagulation on the wall of a bleb. For type III aneurysms, coils are easy to stabilize within the body of aneurysm when making a loop due to the small size of the junction formed between the aneurysm

and bleb. The only factor that needs to be considered is the release of the stent or balloon around the aneurysm neck. The embolization of this type of aneurysm is made relatively simple. Since the stent or balloon placed on the neck of the true aneurysm has mechanical stimulation on the microcatheter and guide wire, patients with a type IV aneurysm are able to have the force controlling the tips of the microcatheter and guidewire reduced. The reduction makes them easily enter into the bleb and extrude through the fragile aneurysm wall, leading to rupture and bleeding.²⁵ Meanwhile, due to a wider junction formed between the aneurysm and bleb (J/D greater than 1/2), coils are very difficult to be retained within the body of the aneurysm. Once they enter into the bleb, it is easy to make the aneurysm rupture. These factors result in a higher risk and poor prognosis of type IV when compared to type III. Therefore, intraoperative bleeding occurred in 2 of the 4 cases of type IV aneurysms, whereas, bleeding occurred in one out of 7 cases of type III aneurysm.

Although the type-dependent manner can help the endovascular treatment, not all ruptured aneurysms can be divided into these 4 types, for example, some ruptured aneurysms often had a regular shape without apparent blebs, and the direction of the ruptured bleb should be considered. Although this is a limitation, the study is still meaningful, as we have proposed a new approach for endovascular treatment of intracranial aneurysm with a ruptured bleb. The cases in the study only numbered 30, so the experience is limited and future research is needed.

In summary, we conclude that the outcome of the endovascular treatment of an intracranial aneurysm with a ruptured bleb is related to the aneurysm type, and therefore, treatment in a type-dependent manner is recommended.

Acknowledgments. *The authors thank Medjaden Bioscience Limited for assistance in the preparation of this manuscript.*

References

1. Nomura M, Kida S, Uchiyama N, Yamashita T, Yoshikawa J, Yamashita J, et al. Ruptured irregularly shaped aneurysms: pseudoaneurysm formation in a thrombus located at the rupture site. *J Neurosurg* 2000; 93: 998-1002.
2. Naggara ON, White PM, Guilbert F, Roy D, Weill A, Raymond J. Endovascular treatment of intracranial unruptured aneurysms: systematic review and meta-analysis of the literature on safety and efficacy. *Radiology* 2010; 256: 887-897.
3. Molyneux AJ, Kerr RS, Yu LM, Clarke M, Sneade M, Yarnold JA, et al. International subarachnoid aneurysm trial (ISAT) of neurosurgical clipping versus endovascular coiling in 2143 patients with ruptured intracranial aneurysms: a randomised comparison of effects on survival, dependency, seizures, rebleeding, subgroups, and aneurysm occlusion. *Lancet* 2005; 366: 809-817.

4. Li MH, Gao BL, Wang YL, Fang C, Li YD. Management of pseudo aneurysms in the intracranial segment of the internal carotid artery with covered stents specially designed for use in the intracranial vasculature: technical notes. *Neuroradiol* 2006; 48: 841-846.
5. D'Urso PI, Loumiotis I, Milligan BD, Cloft H, Lanzino G. "Real time" angiographic evidence of "pseudoaneurysm" formation after aneurysm rebleeding. *Neurocrit Care* 2011; 14: 459-462.
6. Sakai N, Taki W, Yoshimura S, Hyogo T, Ezura M, Matsumoto Y, et al. Retrospective survey of endovascular treatment for ruptured intracranial aneurysm in Japan: Retrospective Endovascular Subarachnoid Aneurysm Treatment (RESAT) study. *Neurol Med Chir (Tokyo)* 2010; 50: 961-965.
7. Alaraj A, Wallace A, Mander N, Aletich V, Charbel FT, Amin-Hanjani S. Effect of acute cocaine use on vasospasm and outcome in aneurysmal subarachnoid hemorrhage. *World Neurosurg* 2010; 73: 357-360.
8. Rosen DS, Macdonald RL. Subarachnoid hemorrhage grading scales: a systematic review. *Neurocrit Care* 2005; 2: 110-118. Review.
9. Tanoue S, Kiyosue H, Matsumoto S, Yamashita M, Nagatomi H, Mori H. Ruptured "blisterlike" aneurysm with a pseudo aneurysm formation requiring delayed intervention with endovascular coil embolization. Case report. *J Neurosurg* 2004; 101: 159-162.
10. Lubicz B. Linear stent-assisted coiling: another way to treat very wide-necked intracranial aneurysms. *Neuroradiology* 2011; 53: 457-459.
11. Cho WS, Kang HS, Kim JE, Kwon OK, Oh CW, Son YJ, et al. Intra-arterial nimodipine infusion for cerebral vasospasm in patients with aneurysmal subarachnoid hemorrhage. *Interv Neuroradiol* 2011; 17: 169-178.
12. Mahaney KB, Todd MM, Torner JC; IHASt Investigators. Variation of patient characteristics, management, and outcome with timing of surgery for aneurysmal subarachnoid hemorrhage. *J Neurosurg* 2011; 114: 1045-1053.
13. Siddiqui MA, J Bhattacharya J, Lindsay KW, Jenkins S. Horizontal stent-assisted coil embolisation of wide-necked intracranial aneurysms with the Enterprise stent--a case series with early angiographic follow-up. *Neuroradiol* 2009; 51: 411-418.
14. Lavine SD, Meyers PM, Connolly ES, Solomon RS. Spontaneous delayed proximal migration of enterprise stent after staged treatment of wide-necked basilar aneurysm: technical case report. *Neurosurg* 2009; 64: E1012.
15. Wanke I, Forsting M. Stents for intracranial wide-necked aneurysms: more than mechanical protection. *Neuroradiol* 2008; 50: 991-998. Review.
16. Birknes JK, Hwang SK, Pandey AS, Cockroft K, Dyer AM, Benitez RP, et al. Feasibility and limitations of endovascular coil embolization of anterior communicating artery aneurysms: morphological considerations. *Neurosurg* 2006; 59: 43-45.
17. Huang Q, Xu Y, Hong B, Zhao R, Zhao W, Liu J. Stent-assisted embolization of wide-neck anterior communicating artery aneurysms: review of 21 consecutive cases. *AJNR Am J Neuroradiol* 2009; 30: 1502-1506.
18. Gupta R, Thomas AJ, Masih A, Horowitz MB. Treatment of extracranial carotid artery pseudo aneurysms with stent grafts: case series. *J Neuroimaging* 2008; 18: 180-183.
19. Sedat J, Chau Y, Mondot L, Vargas J, Szapiro J, Lonjon M. Endovascular occlusion of intracranial wide-necked aneurysms with stenting (Neuroform) and coiling: mid-term and long-term results. *Neuroradiol* 2009; 51: 401-409.
20. Riedel CH, Tietke M, Alfke K, Stिंगel R, Jansen O. Subacute stent thrombosis in intracranial stenting. *Stroke* 2009; 40: 1310-1314.
21. Yahia AM, Gordon V, Whapham J, Malek A, Steel J, Fessler RD. Complications of Neuroform stent in endovascular treatment of intracranial aneurysms. *Neurocrit Care* 2008; 8: 19-30.
22. Tumialán LM, Zhang YJ, Cawley CM, Dion JE, Tong FC, Barrow DL. Intracranial hemorrhage associated with stent-assisted coil embolization of cerebral aneurysms: a cautionary report. *J Neurosurg* 2008; 108: 1122-1129.
23. Sugiu K, Takahashi K, Muneta K, Ohmoto T. Rebleeding of a vertebral artery dissecting aneurysm during stent-assisted coil embolization: a pitfall of the "stent and coil" technique. *Surg Neurol* 2004; 61: 365-370.
24. Kim M, Levy EI, Meng H, Hopkins LN. Quantification of hemodynamic changes induced by virtual placement of multiple stents across a wide-necked basilar trunk aneurysm. *Neurosurg* 2007; 61: 1305-1312.
25. Mocco J, Snyder KV, Albuquerque FC, Bendok BR, Alan S B, Carpenter JS, et al. Treatment of intracranial aneurysms with the Enterprise stent: a multicenter registry. *J Neurosurg* 2009; 110: 35-39.

Related articles

Yurt A, Ozer F, Selçuki M, Ertürk AR, Görgülü O. Effect of systemic parameters following experimental subarachnoid hemorrhage and cerebral vasospasm in rabbits by injection of blood into the subarachnoidal space. *Neurosciences (Riyadh)* 2010; 15: 15-20.

Taha MS, Patel UJ. Clipping versus coiling for ruptured intracranial aneurysms after the international subarachnoid aneurysm trial. *United Kingdom experience. Neurosciences (Riyadh)* 2009; 14: 118-123.

Jamil SA, Khan AS, Akturk Z. Predictors of outcome for non-traumatic intracerebral hemorrhage. *Neurosciences (Riyadh)* 2008; 13: 263-267.