

Ulnar neuropathy caused by traumatic arterio-venous fistula following gunshot wound

Bassam M. Addas, MChB, FRCSC.

ABSTRACT

نستعرض في هذا المقال حالة ناصور شرياني وريدي على العصب الزندي الأيمن لشاب يبلغ من العمر 32 عاماً وذلك نتيجة إصابته بطلق ناري أدى إلى آلام شديدة في منطقة العصب الزندي في الساعد واليد. وقد تحسنت حالة المريض بشكل كبير بعد استئصال هذا الناصور. تعد هذه الحالة من الحالات النادرة جداً حيث لم يتم وصف حالة مماثلة من قبل. وهذا يجعل الناصور الشرياني الوريدي للعصب الزندي أحد الأسباب النادرة لاعتلال العصب الزندي في حالات الإصابة بالطلقات النارية.

This report concerns a case of a 32-year-old male with right ulnar neuropathy caused by arterio-venous fistula due to gunshot wound injury presenting with severe neuropathic pain along the ulnar nerve distribution. Intra-operative exploration and ligation of the fistula relieved the patient's neuropathic pain. A review of the recent English literature did not reveal any reports of arterio-venous fistula of the ulnar nerve.

Neurosciences 2012; Vol. 17 (2): 165-166

From the Division of Neurosurgery, Department of Surgery, Faculty of Medicine, King Abdul-Aziz University Hospital, Jeddah, Kingdom of Saudi Arabia.

Received 31st August 2011. Accepted 11th December 2011.

Address correspondence and reprint request to: Prof. Bassam M. Addas, Assistant Professor of Neurosurgery, Division of Neurosurgery, Department of Surgery, Faculty of Medicine, King Abdul-Aziz University Hospital, PO Box 80215, Jeddah 21589, Kingdom of Saudi Arabia. Tel. +966 (2) 6401000 Ext. 18230. Fax. +966 (2) 6408347. E-mail: addasneuro@yahoo.ca

Most of our knowledge of gunshot wound injuries to the peripheral nerves is derived from military conflicts and major world war reports. Civilians can be injured accidentally by their own guns or in recreational sports. Most reports of gunshot wounds to the peripheral nerves focus on the outcome of the injured nerves, with less emphasis on the details of the associated vascular or soft tissues injuries. Vascular injuries and pseudo-aneurysms are very well-known entities,¹ but no explicit

reports on arterio-venous fistula are available in major recent reports. Arterio-venous fistula related neuropathy is a well-known entity, commonly related to fistulas surgically created for renal dialysis purposes.^{2,3} The pathophysiology of nerve injury due to gunshot wounds includes direct nerve trauma, associated fractures, soft tissue injury, and pseudo-aneurysms. Traumatic arterio-venous fistula can be another, although rare, mechanism of nerve injury due to gunshot wounds. On review of the English literature, no cases of arterio-venous fistula of the peripheral nerves due to gunshot wounds were found. This case report will add arterio-venous as one of the etiological factors of peripheral nerve injury due to gunshot wounds.

Case Report. This is a case of a 32-year-old Somali male with a gunshot wound injury to the right arm nearly 8 months before his presentation. The bullet scratched the anterior chest wall before entering the medial aspect of the right arm (Figure 1). He presented with a healed right comminuted humerus fracture and complete right radial nerve injury, partial median nerve injury, and severe neuropathic pain along the ulnar nerve distribution. He did not show any spontaneous recovery and was therefore explored. Through a posterior arm incision, the radial nerve was graft repaired. Medial arm exposure revealed a neuroma-in-continuity of the median nerve that was neurolysed and a tortuous arterio-venous fistula of the ulnar nerve that was isolated over a 7 cm segment of the nerve and ligated (Figure 2). Striking improvement of his neuropathic pain, probably related to the ligation of the ulnar nerve arterio-venous fistula was evident in the first post-operative week. On 2-year follow-up, his complaint associated with the ulnar nerve was negligible. He, however, continues to have "tolerable" neuropathic pain related to his median nerve injury.

Discussion. The ulnar nerve has a unique external blood supply along its course from the axilla down to the wrist. Branches from the axillary and the brachial artery form a continuous arterial chain around the nerve. At the level of the arm, this chain is derived from

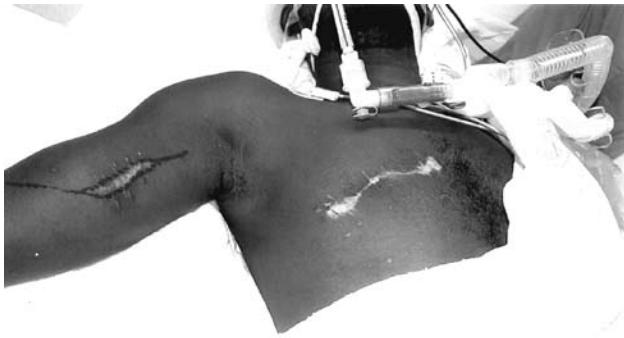

Figure 1 - Pre-operative photograph illustrating the path of the gunshot across the patient's chest with the entry wound in the medial arm.

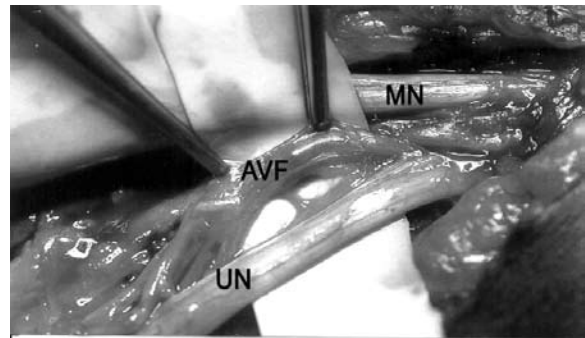


Figure 2 - Intra-operative photograph of the right arm depicting the ulnar nerve (UN) with the separated arterio-venous fistula held by 2 forceps (AVF) before ligation. The median nerve (MN) is shown above the ulnar nerve.

the brachial artery with its main branches. Before its division to ulnar and radial branches, the brachial artery gives off the superior and the inferior ulnar collateral arteries. From the ulnar division arise the anterior and the posterior ulnar recurrent arteries.⁴ The entire length of the ulnar nerve can survive based on the superior ulnar collateral artery and its venae comitantes.⁵ This extensive blood supply is not seen with other upper limb peripheral nerves.

Pseudoaneurysm causing nerve injury following missile injury has been reported and is a known complication of missile injury.¹ There has been no explicit report of arterio-venous fistula of the ulnar nerve in recent reports of peripheral nerve injuries caused by gunshot wounds. Secer and associates⁶ did not report any case of arterio-venous fistula of the ulnar nerve in their large surgical series of 407 missile injuries to the ulnar nerve. Oberlin and Rantissi⁷ did not encounter a case of fistula in their 207 operated cases. Similarly, Roganovic⁸ reported associated vascular injuries in his 128 cases of surgical ulnar nerve repair due to missile injuries, with no mention of arterio-venous fistulas, and the same is true in Kim's⁵ report on the surgical outcome of 654 cases of ulnar nerve lesions.

This case illustrates the rare occurrence of a nerve lesion associated with arterio-venous fistula caused by gunshot wounds. We postulate 3 possible reasons for such a rarity; first, injury to the ulnar nerve can cause

a large defect and soft tissue loss and obscuration of the nearby anatomy making identification of fistulas difficult. Second, arterio-venous fistula of the ulnar nerve can be asymptomatic and therefore under-reported. Third, close relation between and ulnar nerve and its blood supply along its entire course makes it more susceptible, although rarely, to the development of traumatic arterio-venous fistula than any other nerve.

References

1. Roganovic Z, Misovic S, Kronja G, Savic M. Peripheral nerve lesions associated with missile-induced pseudoaneurysms. *J Neurosurg* 2007; 107: 765-775.
2. Corradi M, Paganelli E, Pavesi G. Carpal tunnel syndrome in long-term hemodialyzed patients. *J Reconstr Microsurg* 1989; 5: 103-110.
3. Sawin PD, Loftus CM. Posterior interosseous nerve palsy after brachiocephalic arteriovenous fistula construction: report of two cases. *Neurosurgery* 1995; 37: 537-539; discussion 539-540.
4. Sunderland S. Nerve and Nerve Injuries. Edinburgh (UK): Churchill-Livingstone; 1978.
5. Kim DH, Han K, Tiel RL, Murovic JA, Kline DG. Surgical outcomes of 654 ulnar nerve lesions. *J Neurosurg* 2003; 98: 993-1004.
6. Secer HI, Daneyemez M, Gonul E, Izci Y. Surgical repair of ulnar nerve lesions caused by gunshot and shrapnel: results in 407 lesions. *J Neurosurg* 2007; 107: 776-783.
7. Oberlin C, Rantissi M. Gunshot injuries to the nerves. *Chir Main* 2011; 30: 176-182.
8. Roganovic Z. Missile-caused ulnar nerve injuries: outcomes of 128 repairs. *Neurosurgery* 2004; 55: 1120-1129.