

Morphology and clinical significance of the distribution of the median nerve within the arm of human cadavers

Ashraf Y. Nasr, MD.

ABSTRACT

الأهداف: وصف أنماط تكوين ومستوى البداية وإختلافات المسار والعلاقات للعصب الوسطى بعضد الجثث الأدمية .

الطريقة: استخدم في هذه الدراسة 60 طرف علوي لعشرين جثة ذكور و10 جثث إناث آدمية بالغة . وتم الحصول على تلك الجثث من قسم التشريح، كلية الطب جامعة الملك عبد العزيز، جدة، المملكة العربية السعودية. أجريت الدراسة خلال الفترة من فبراير 2011م إلى 30 ديسمبر 2011م. تم تشريح منطقة الإبط، والعضد، والساعد لكل طرف لتوضيح الأنماط المختلفة لتكوين وإنتشار العصب الوسطى في العضد .

النتائج: لوحظ أن العصب الوسطى تكون من جذرين في 88.3% من الأطراف العلوية ولكن في 11.7% من الأطراف العلوية وجد له 3 جذور . علاوة على ذلك فقد بدأ العصب في مستوى الجزء الثالث للشريان الإبطي في 93.3% من الأطراف العلوية وعند نهاية العضلة الغرابية العضدية في 6.7% أطراف علوية . ولكن بالإرتباط مع الشريان العضدى قد لوحظ أن مسار العصب الوسطى له 6 أنماط . إن العصب الوسطى مر تحت العضلة الغرابية عضدية والعضلة العضدية في 8.3% من الأطراف العلوية . وقد لوحظ غياب العصب العضلى الجلدي في 3.3% من الأطراف العلوية حيث أن العصب الوسطى غذى عضلات العضد الأمامية وقد أعطى العصب العضلى الجلدي فرع رابط للعصب الوسطى في 13.3% من الأطراف العلوية .

خاتمة: إن معرفة الإختلافات فى إنتشار العصب الوسطى فى العضد تساعد الممارسين والجراحيين فى تشخيص الحالات السريرية الغير مشروحة .

Objective: To describe the patterns of formation, level of beginning, variations of course, and relation of the median nerve within the arm of human cadavers.

Methods: Sixty upper limbs of 20 male and 10 female adult human cadavers were used in this study. The cadavers were obtained from the Anatomy Department, Faculty of Medicine, King Abdulaziz

University, Jeddah, Saudi Arabia, and the study was conducted between February and December 2011. The axillary regions, arm, and forearm, of each limb were dissected to clarify the different patterns of median nerve formation and distribution within the arm.

Results: The formation of the median nerve from 2 roots was found in 88.3% of upper limbs, while in 11.7% of upper limbs, it had 3 roots. Moreover, the median nerve began at the level of the third part of the axillary artery in 93.3% of upper limbs, and at the coracobrachialis muscle insertion in 6.7% of upper limbs. However, in correlation to the brachial artery, the median nerve had 6 patterns of relationship. The median nerve passed deep to the coracobrachialis and brachialis muscles in 8.3% of upper limbs. Meanwhile, the median nerve supplied the front arm muscles in 3.3% of upper limbs where the musculocutaneous nerve was absent. In 13.3% of upper limbs, the musculocutaneous nerve gave a communicating branch to the median nerve.

Conclusion: Knowledge of such variants of the median nerve helps clinicians and surgeons in the diagnosis of unexplained clinical cases.

Neurosciences 2012; Vol. 17 (4): 336-344

From the Anatomy Department, Faculty of Medicine, Zagazig University, Egypt, and the Anatomy Department, King Abdulaziz University, Jeddah, Kingdom of Saudi Arabia.

Received 19th March 2012. Accepted 5th August 2012.

Address correspondence and reprint request to: Dr. Ashraf Y. Nasr, Associate Professor, Anatomy Department, King Abdulaziz University, PO Box 80205, Jeddah 21589, Kingdom of Saudi Arabia. Tel. +966 (2) 6401000 Ext. 20477. Fax. +966 (2) 4601000 Ext. 20121. E-mail: ashrafnaem2012@yahoo.com

Disclosure. The author declares no conflicting interests, support or funding from any drug company.

The median nerve, the axillary, and brachial arteries are the main neurovascular structures within the arm. The usual formation of the median nerve is the result of the union of the medial root of the medial cord and the lateral root of the lateral cord. These roots embrace the third part of the axillary artery, and join together anterior or lateral to the axillary artery to form the median nerve. The nerve passes at first lateral to the brachial artery then crosses anterior to the artery, descending medial to it in the cubital fossa where it passes posterior to the bicipital aponeurosis and anterior to the brachialis without giving out any branches.¹ The relation between the axillary artery and median nerve roots reported different variations.^{2,3} The intimate relationship of the axillary artery with the neighboring nerves may lead to its compression, resulting in ischemic pain, or varying degrees of arterial insufficiency during certain postural maneuvers of the shoulder joint.⁴ The anatomy of median nerve entrapments have been studied in the context of anomalous origins of the biceps and brachialis muscles in the distal arm.⁵ The anatomic variations of median nerve distribution within the arm are important to the anatomist, clinicians, and also to the radiologist and surgeon.⁶ Most median nerve variations are observed in sporadic cases, and this study aimed to describe the topography of normal and variant median nerve distribution within the arm including patterns of formation, level of beginning, differences of course, and relation within the arm with correlation to clinical significance.

Methods. Sixty upper limbs of 20 male and 10 female human cadavers were used in this study carried out between February and December 2011. The specimens were obtained from the Anatomy Department, Faculty of Medicine, King Abdulaziz University, Jeddah, Saudi Arabia. Ethical approval for the study protocol was obtained from the Research Ethical Committee of the Faculty of Medicine, King Abdulaziz University.

The pectoral region, axilla, arm and forearm of the upper limbs were carefully dissected. The skin and fasciae of these regions were incised and reflected

to expose the underlying structures. The cords of the brachial plexus and their infra-clavicular branches were carefully dissected and cleaned. The median nerve was exposed throughout its full course from the point of its formation down to the wrist. The patterns of median nerve formation, level of its beginning site, course, and relationship to its neighboring arteries, nerves, and muscles were reported. The data were tabulated into different categories to determine the number and percentage of each item in the limbs regarding the side and gender. Any limb showing median nerve disruption throughout its course or formation was excluded from the study.

Results. Two patterns of median nerve formation were seen in the specimens of the present study (Table 1). The median nerve of the first pattern was formed by the union of the medial root of the medial cord with the lateral root of the lateral cord. This pattern was found in 53 out of 60 (88.3%) upper limbs. In females, it was observed in 18 out of 20 (90%) upper limbs with equal distribution in both right and left sides. While in males, this pattern was noticed in 35 out of 40 upper limbs (87.5%), with slight left predominance (18 left [90%] versus 17 [87.5%] right upper limbs). However, in 7 out of the 60 upper limbs (11.7%), the median nerve was formed of 3 roots, 2 from the lateral cord and one from the medial cord. This pattern was noticed in 5 out of 40 (12.5%) male upper limbs, and 2 out of 20 (10%) female upper limbs. Its prevalence was noticed in 4 out of 30 (13.3%) right upper limbs, and 3 out of 30 (10%) left upper limbs. It was seen bilaterally in one male cadaver only. The medial root of the medial cord crossed the front of the second part of the axillary artery to unite with the proximal lateral root of the lateral cord on the lateral side of the third part of the axillary artery forming the median nerve. A few cms distally, the median nerve received the second (distal) lateral root from the lateral cord.

Different levels of beginning site of the median nerve formation were observed (Table 2). The beginning site of the median nerve was related to the third part of

Table 1 - Patterns of median nerve formation among studied cadavers.

Patterns of median nerve formation	Male limbs (40)		Female limbs (20)		Total (60)	
	Right (20) n (%)	Left (20) n (%)	Right (10) n (%)	Left (10) n (%)	n (%)	n (%)
Pattern I (2 roots)	17 (85)	18 (90)	9 (90)	9 (90)	53 (88.3)	
<i>Pattern II (3 roots) total</i>	3 (15)	2 (10)	1 (10)	1 (10)	7 (11.7)	
Unilateral pattern II - A	2 (10)	1 (5)	1 (10)	1 (10)	5 (8.3)	
Bilateral pattern II- B	1 (5)	1 (5)	0 (0)	0 (0)	2 (3.3)	

Table 2 - Beginning sites of the median nerve among studied cadavers.

Site of median nerve formation	Male limbs (40)		Female limbs (20)		Total (60)	
	Right (20)	Left (20)	Right (10)	Left (10)	Total (60)	
	n (%)	n (%)	n (%)	n (%)	n (%)	n (%)
Lateral to third part of XA	15 (75)	17 (85)	6 (60)	8 (80)	46	(76.7)
Anterior third part of XA	2 (10)	1 (5)	1 (10)	1 (10)	5	(8.3)
Medial to third part of XA	1 (5)	1 (5)	1 (10)	1 (10)	4	(6.7)
Level of CBM insertion	2 (10)	1 (5)	1 (10)	0 (0)	4	(6.7)
Posterior third of XA	0 (0)	0 (0)	1 (10)	0 (0)	1	(1.7)

XA - axillary artery, CBM - coracobrachialis muscle

the axillary artery in 56 out of 60 (93.3%) upper limbs while, in 4 out of 60 (6.7%) upper limbs, the beginning of the median nerve was related to the brachial artery at the level of the coracobrachialis muscle insertion. In 46 out the 60 upper limbs (76.7%), the median nerve began on the lateral side of the third part of axillary artery; 32 upper limbs were those of male cadavers, and the other 14 upper limbs belonged to the female cadavers. Regarding the limb side, the prevalence of this pattern was noticed in 15 out of 20 (75%) right male, 17 out 20 (85%) left male, 6 out of 10 (60%) right female, and 8 out 10 (80%) left female upper limbs. However, the median nerve began on the front of the third part of the axillary artery in 5 out 60 (8.3%) upper limbs. This pattern was noticed in 2 right male upper limbs, one left male upper limb, one right, and one left female upper limbs. Moreover, the level of beginning site of the median nerve was seen on the medial side of the third part of the axillary artery in 4 out of 60 upper limbs (6.7%). This pattern showed symmetrical

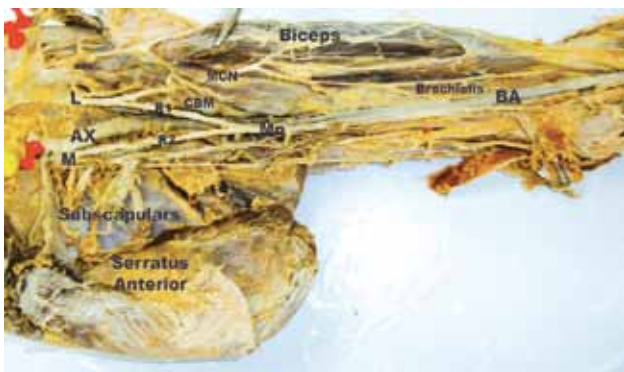

Figure 1 - A photograph of a left male upper limb showing the formation of the median nerve (Mn) in the arm from the long lateral (R1) and medial (R2) roots on the medial aspect of the brachial artery (BA) at the level of coracobrachialis muscle (CBM) insertion. The musculocutaneous nerve (MCN) pierces the coracobrachialis muscle to supply biceps and brachialis muscles. L - lateral cord, M - medial cord, AX - axillary artery

distribution on both side and genders, where it was found in one right male (5%), one left male (5%), one right female (10%), and one left female (10%) upper limb. However, the median nerve began within the arm at the level of the coracobrachialis muscle insertion in 4 (6.7%) upper limbs, 2 right male (10%), one left male (5%), and one right female (10%) upper limb. The median nerve of these limbs showed long medial and lateral roots that originated from their corresponding cords of brachial plexus. The 2 roots passed on the medial and lateral sides of the third part of the axillary artery and the upper half of the brachial artery down to the level of coracobrachialis muscle insertion where the lateral root crossed the front of the brachial artery to unite with the medial root to form the median nerve on the medial side of the brachial artery. Then, the nerve descended on the medial side of the lower half of the brachial artery down to the cubital fossa (Figure 1). Moreover, in one right female upper limb (1.7%), the median nerve was formed of 2 roots as usual. The 2 roots of this median nerve formed clasp-like around an arterial trunk originating from the posteromedial aspect of the third part of the axillary artery. Then, the 2 roots united with each other behind the third part of the axillary artery to form the median nerve. Within the arm, this median nerve passed downward behind the brachial artery. Then, 78 mm proximal to the medial epicondyle of humerus, the median nerve disappeared within the substance of the brachialis muscle for a distance of 67 mm. Thereafter, at 11 mm proximal to the medial epicondyle, the median nerve reappeared again on the medial side of the brachial artery and followed its normal course down to its termination within the cubital fossa (Figure 2).

Different patterns of relationship were observed between the median nerve and the brachial artery course within the arm (Table 3). In the first classic pattern, the median nerve passed on the lateral side of the upper half of the brachial artery down to its middle where it crossed the brachial artery anteriorly to descend on

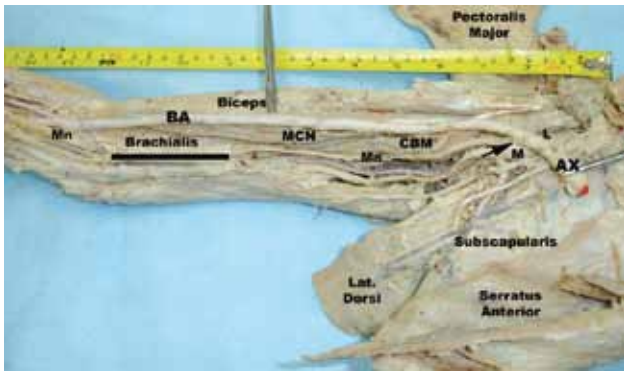


Figure 2 - A photograph of a right female upper limb showing the formation of the median nerve (Mn) posterior to the third part of the axillary artery (AX) by the union of the lateral (L) and medial (M) roots. The median nerve descends posterior to the brachial artery (BA) throughout its course within the arm. The 2 roots form a fork-like around an arterial trunk (black arrow) that originates from the posteromedial aspect of the third part of the axillary artery. The median nerve disappears within the substance of the brachialis muscle (Bar). At the base of the cubital fossa the nerve deviates on the medial aspect of the brachial artery. MCN - musculocutaneous nerve, Lat. Dorsi - latissimus dorsi, CBM - coracobrachialis muscle

its medial side down to the cubital fossa. This pattern was observed in 47 out of 60 (78.3%) upper limbs. Its prevalence was noticed in 32 out of 40 (80%) male upper limbs and 15 out of 20 (75%) female upper limbs. Regarding the limb side, this pattern was predominant in left (25 out of 47) upper limbs. In the second pattern, the median nerve passed on the medial aspect of the brachial artery throughout its course within the arm down to the cubital fossa. This pattern was seen in 4 out of 60 (6.7%) upper limbs. It was found in one right (5%) male, one left (5%) male, one right (10%) female, and one left (10%) female upper limb. The third pattern was the lower formation of the median nerve at the level of the coracobrachialis muscle insertion on the medial side of the brachial artery down to the cubital fossa (Figure 1). This pattern was noticed in 2

right male, one left male, and one right female upper limb. Moreover, there were another 3 rare patterns of median nerve-brachial artery relationship within the upper limbs. The first pattern of them was seen in 2 upper limbs only, one left male and one right female where the median nerve descended at the lateral aspect of the brachial artery throughout its course within the arm down to the cubital fossa. In addition, in 2 upper limbs (3.3%), one right male and one left female, the median nerve crossed the brachial artery from its lateral aspect to its medial side posteriorly at the level of coracobrachialis muscle insertion. In these 2 limbs, the median nerve received a communicating branch from the musculocutaneous nerve (Figure 3).

We observed different variations of the median nerve within the arm (Table 4). The highest incidence was the presence of a communicating branch between the median and musculocutaneous nerves (Figure 3) where it was noticed in 8 out of 60 upper limbs (13.3%), 2 right male, 3 left male, one right female, and 2 left female upper limbs. Normally, the median nerve distributes between the biceps muscle superficially and the brachialis muscle deeply. However, in 4 out of 60 (6.7%) upper limbs, the median nerve passed deep to the brachialis muscle. The prevalence of this variant was found in one right male, one left male, one right female, and one left female upper limb. Three cases of them showed superficial crossing of the median nerve and brachial artery by a muscular band originating from the lateral aspect of the distal part of the brachialis muscle just proximal to the elbow joint to insert into the front of the medial epicondyle of the humerus (Figure 4) while, in the fourth upper limb, the median nerve disappeared within the substances of the brachialis muscle for 6.7 mm length and reappeared again 11 mm distal to the medial epicondyle on the medial aspect of the brachial artery (Figure 2). Moreover, in 3 upper limbs, 2 male (one right and one left) and one left female, the median nerve gave branches within the arm. In 2 of them (one right male and one left female), the musculocutaneous nerve was absent and the median

Table 3 - Patterns of relationship between the median nerve and the brachial artery (BA) among studied cadavers.

Different variations of median nerve distribution within arm	Male limbs (40)		Female limbs (20)		Total (60)	
	Right (20) n (%)	Left (20) n (%)	Right (10) n (%)	Left (10) n (%)	n (%)	n (%)
Upper lateral and lower medial with anterior crossing (classic)	15 (75)	17 (85)	7 (70)	8 (80)	47	(78.3)
Medial to BA throughout its course	2 (10)	1 (5)	0 (0)	1 (10)	4	(6.7)
Medial to BA in lower half only	2 (10)	1 (5)	1 (10)	0 (0)	4	(6.7)
Lateral to BA throughout its course	0 (0)	1 (5)	1 (10)	0 (0)	2	(3.3)
Upper lateral and lower medial with posterior crossing	1 (5)	0 (0)	0 (0)	1 (10)	2	(3.3)
Posterior to BA throughout its course	0 (0)	0 (0)	1 (10)	0 (0)	1	(1.7)




Figure 3 - A photograph of a left female upper limb showing the posterior crossing of the median nerve (Mn) to the brachial artery (BA) distal to the insertion of the coracobrachialis muscle (CBM). The median nerve receives a communicating branch (black arrow) from the musculocutaneous nerve (MCN). A muscular slip (B) originates from the CBM crossing the brachial artery, median nerve, and medial cutaneous nerve of the forearm (MCF) superficially to insert into the medial border of the humerus (arrow head). AX - axillary artery, 3rd - third head of biceps, ME - medial epicondyle

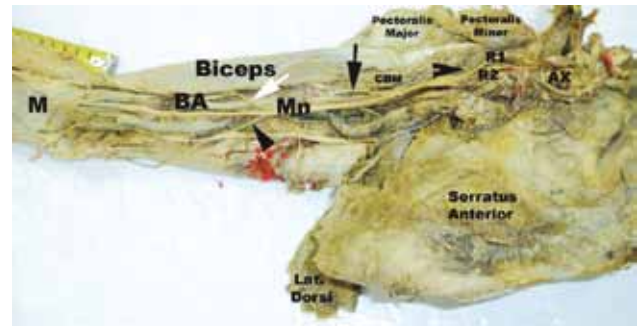


Figure 4 - A photograph of a right male upper limb showing the formation of the median nerve (Mn) by union of the lateral (R1) and medial (R2) roots on the lateral side of the third part of axillary artery (AX). The median nerve crosses the front of the brachial artery (BA) from lateral to medial side. The lower part of brachialis muscle gives a thin broad sheet (M) crossing both median nerve and brachial artery superficially at the cubital fossa. The median nerve gives motor branches to the biceps (black arrow) and brachialis (black arrow head) muscles and sensory branch (white arrow) to the forearm, while, the motor branch of the coracobrachialis muscle (CBM) originates from the lateral root of median nerve (open arrow head). Lat. Dorsi - latissimus dorsi

nerve gave muscular branches to coracobrachialis, biceps, and brachialis muscles (Figure 4) while, in the left male upper limb, the median nerve gave muscular branches to the flexor muscles of forearm proximal to the cubital fossa. Lastly, in one left female upper limb, the insertion of the coracobrachialis muscle sent a sling superficial to the median nerve, brachial artery, ulnar nerve, medial cutaneous nerve of the forearm, and the basilic vein before its termination on the medial border of the middle of the humerus (Figure 3).

Discussion. Knowledge of peripheral nervous system variations is important in clinical and surgical practice because of nerve palsy syndromes and/or because ischemia may occur due to the compression of the nerve to its surrounding vessels or vice versa.⁷ In the present study, the formation of the median nerve by union of the medial and lateral roots of its corresponding cord showed slight differences in its distribution within the male (87.5%) and the female (90%) upper limbs as well as right (87.5%) and left (90%) upper limbs. These findings were in accordance with those of Standing.¹

The prevalence of the 3 roots pattern of median nerve formation reported marked difference, where in male upper limbs it was 8.3%, and was observed in 3.3% of female upper limbs. Moreover, its incidence was higher in the right than those of left upper limbs, and it appeared bilaterally in one male cadaver only. Similar observations were reported by Budhiraja et al⁸ and Sontakke et al.⁹ Agreeing with the results of the present study, Budhiraja et al⁸ stated that in 28 out of 196 (14.2%) upper limbs, the lateral cord gave 2 roots for the median nerve; one united with the medial root of the medial cord in the axilla, while the other one united with the median nerve in the arm. The authors added that in 8.16% (16 out of 196) of upper limbs the median nerve received an additional root from the musculocutaneous nerve. However, in the present study, the median nerve received a communicating branch

Table 4 - Different variations of the median nerve within the arm of studied cadavers.

Different variations of median nerve distribution within arm	Male limbs (40)		Female limbs (20)		Total (60)	
	Right (20) n (%)	Left (20) n (%)	Right (10) n (%)	Left (10) n (%)	n (%)	n (%)
Connection with MCN	2 (10)	3 (15)	1 (10)	2 (20)	8 (13.3)	
Passing deep to brachialis	1 (5)	1 (5)	1 (10)	1 (10)	4 (6.7)	
Branching within the arm	1 (5)	1 (5)	0 (0)	1 (10)	3 (5.0)	
Absence of MCN	1 (5)	0 (0)	0 (0)	1 (10)	2 (3.3)	
Passing deep to CBM	0 (0)	0 (0)	0 (0)	1 (10)	1 (1.7)	

MCN - musculocutaneous nerve, CBM - coracobrachialis muscle

from the musculocutaneous nerve in 13.3% of the upper limbs. In another report,¹⁰ the median nerve was formed by the fusion of 4 roots, 3 of them originated from the lateral cord and one arose from the medial cord. A median nerve of 4 roots was not observed in the limbs of the present study. Budhiraja et al⁸ added that the median nerve was formed of 4 roots in 3.57% (7 out of 196 upper limbs); 2 roots originated from the lateral cord, one root arose from the medial cord, and the fourth one originated from the musculocutaneous nerve. However, Sontakke et al⁹ described a case of a median nerve with 3 roots; 2 from the lateral cord, and one from the medial cord. The authors added that the first lateral root crossed the second part of the axillary artery to unite with the medial root of the medial cord to form the median nerve on the medial side of the third part of the axillary artery. Most of the fibers of this first lateral root, which arose from the lateral cord in the axilla, passed to the ulnar nerve, but the second lateral root joined with the medial root in the arm to form the median nerve. Moreover, Goyal et al,¹¹ found the median nerve to be formed by 3 roots; the additional root originated from the anterior division of the middle trunk. In another study,¹² the median nerve showed an additional root in 52% of the cases. In 4 cases, one of the 2 lateral roots came from the anterior division of the middle trunk, and one from the lateral cord. In 24 cases, they found 2 lateral roots from the lateral cord.¹² No similar case was observed in the limbs of the present study. In a large series of 344 brachial plexus dissection, Pandey and Shukla,¹³ reported that one or 2 communicating branches from the lateral cord joined the medial root of the median nerve in 2.3% of the specimens.

In the present study, in 76.7% upper limbs the median nerve formed on the lateral aspect of the third part of the axillary artery where the medial root crossed the third part of the axillary artery anteriorly to join with the lateral root on its lateral aspect. Similarly, Budhiraja et al⁸ and Standring¹ stated that the most common median nerve was formed on the lateral side of the third part of the axillary artery. In agreement with the results of the present study where the median nerve formed on the medial aspect of the third part of the axillary artery in 6.7% of the specimens; Budhiraja et al⁸ found that the median nerve formed medial to the third part of the axillary artery in 6.12% of the specimens. However, Pandey and Shukla¹³ reported that the median nerve formation to the third part of the axillary artery was found in 4.7% of upper limbs. The authors added that both roots of the median nerve were joined on the medial side of the axillary artery to form

the median nerve. In these cases, the lateral root crossed the axillary artery anteriorly to join with the medial to third part of the axillary artery. In addition, there were reports where the median nerve was formed medial to axillary artery.^{6,14}

In the present study, the median nerve formed on the front of the axillary artery in 8.3% of the specimens, in disagreement with Budhiraja et al⁸ who stated that in 1.53% of upper limbs the median nerve formed anterior to the axillary artery. The authors added that knowledge of such variation had clinical importance especially in post traumatic evaluations and peripheral nerve repair. The passage of the median nerve anterior to the axillary artery might compress it with production of ischemic manifestation. A variant of median nerve formation was noted in one right female upper limb (1.7% of the specimens). In this variant, the median nerve was formed behind the third part of the axillary artery and its course in the arm was entirely behind the brachial artery. In addition, in the lower third of the arm, this median nerve disappeared within the substance of the brachialis muscle and reappeared again on the front of the elbow joint medial to the brachial artery. With exception to the brachialis muscle relation, a similar case was noted in the left upper limb of a male cadaver,¹⁵ and in a right male upper limb.¹⁶ The authors added that the compression of the axillary artery might occur due to the roots of the nerve passing around the artery. Moreover, the median nerve might be compressed between the fork of the axillary artery and its branch. Thus, such a variation has great clinical importance to differentiate between the symptoms of radiculopathy and carpal tunnel syndrome. This agrees with Chitra¹⁷ who found compression of the medial root of the median nerve between the axillary and anterior circumflex humeral arteries. Moreover, a rare variation of entrapment of the medial root of the median nerve between the axillary artery and its variant branch was reported by Vijaya et al.¹⁸ In agreement with the results of the present study, no bilateral compression of the median nerve was reported in dissections of 172 cadavers.¹³

In the present study, the median nerve began at the level of the coracobrachialis muscle insertion in 4 upper limbs (6.7%), 3 male and one female. Seventy-five percent of this pattern appeared in the right upper limbs. In disagreement with the results of the present study, a higher incidence (17.3%) of this variation was reported by Budhiraja et al.⁸ The authors added that such cases of lower origin of the median nerve might lead to confusion in surgical procedures and nerve block anesthesia. Uysal et al¹⁹ observed the 2 roots of the median nerve joining in the distal part of the arm in

8.5% cases, while Pandey and Shukla¹³ found the low fusion of the 2 roots of the median nerve in 6 out of 172 (3.5%) cadavers. The authors added that the 2 roots of the median nerve did not join to form the median nerve in the axilla, but, both traveled separately anteromedial to the axillary and brachial arteries (bifid median nerve) in 3 out of 172 (1.7%) cadavers. No similar findings were observed in the cadavers of the present study.

The different variations of the course of the median nerve in relation to the brachial artery were not studied in the previous literature. Thus, we focused on this point in our research to determine the patterns and the clinical significance of this relationship. In the present study, most median nerves were formed on the lateral aspect of the third part of the axillary artery, it then passed on the lateral side of the upper half of the brachial artery down to the level of the coracobrachialis muscle insertion where it crossed the artery anteriorly to descend on the medial side of its lower half down to the cubital fossa. These results were in agreement with those of Standring¹ and Budhiraja et al.⁸

In the present study, passage of the median nerve along the medial aspect of the brachial artery was found in 8 (13.3%) upper limbs, 5 (8.3%) right, and 3 (5%) left. Its prevalence in males was triple those of the female upper limbs. In this pattern, the beginning of the median nerve in the axilla and arm was equally distributed, 50% each. Similar cases were previously reported, but in a sporadic manner.^{15,16} Moreover, the median nerve was formed on the lateral side of the third part of the axillary artery, it then passed on the lateral aspect of the brachial artery throughout its course down to the cubital fossa in 2 upper limbs (3.3%), one left male and one right female. A similar case was reported by Chita.¹⁷ In such cases, the median nerve might be compressed by the biceps tendon or the brachial artery at the cubital fossa.

In the present study, the median nerve crossed the brachial artery posteriorly at the level of the mid arm in 2 limbs (3.3%), one right male and one left female. In these 2 limbs, the musculocutaneous nerve gave a communicating branch to the median nerve. A similar case was reported by Nayak²⁰ who stated that the median nerve began in the upper part of the arm by union of its medial and lateral roots anterior to the brachial artery. It then passed downward lateral to the artery until the lower part of the arm where it crossed the artery from lateral to medial, deep to it. The author added that the musculocutaneous nerve was absent and the median nerve supplied the front arm muscles. In this case, the neurovascular symptoms might occur

where the brachial artery could compress the median nerve or vice versa.

Despite the numerous reports on the variations of the median nerve and brachial artery, few studies have described the compression of the median nerve and brachial artery with anomalous muscles.²¹ In the present study, the median nerve was seen undercover of the substance of the brachialis muscle in 4 limbs (6.7%). The prevalence of this variation was equally distributed in the upper limbs of both male and female cadavers. In 3 limbs (5%), a thin fleshy sheet originated from the distal part of the brachialis muscle (on the front of the elbow joint) and diverged medially superficial to the brachial artery and median nerve to merge with the common flexor origin of the superficial muscles of the forearm. A similar variation was reported by George and Nayak²² in the right female limb. The authors added that these fibers might be used to reconstruct the annular ligament or medial collateral ligament of the elbow joint. However, in our fourth case, the median nerve was hidden within the substance of the lower third of the brachialis muscle instead of passing superficial to it. Thereafter, it reappeared again on the medial aspect of the brachial artery in the cubital fossa. No similar case was previously described in the literature. Neurovascular symptoms might occur in these cases due to the compression of both the median nerve and the brachial artery by the brachialis muscle, especially during flexion of the elbow joint. Median nerve entrapment has been mentioned in 3 main sites, namely, carpal tunnel syndrome, pronator teres syndrome, and anterior interosseous syndrome. The entrapment of the median nerve by the third head of the biceps muscle was previously reported in a few case reports.²³ Rarely, high median nerve compression could occur due to bicipital aponeurosis, along with the brachial artery.²⁴

In the present study, the insertion of the coracobrachialis muscle showed an unusual accessory slip in one left female upper limb (1.7%). This slip extended from the superficial fibers of the coracobrachialis muscle insertion downward and medially in front of the median nerve, brachial artery, and basilic vein to insert into the medial border of the humerus. A similar case was reported by Potu et al,²⁵ in one right male upper limb. The authors added that the existence of such an abnormal insertion of the coracobrachialis muscle should be kept in mind in a patient presenting with high median nerve palsy together with symptoms of brachial artery compression. It might lead to wasting or ischemic contraction of flexors of the forearm. This variation should be remembered during the active

use of the coracobrachialis as a transposition flap in deformities of infra-clavicular and axillary areas and in post-mastectomy reconstruction.²⁶ Also during surgical intervention of the anterior compartment of the arm, such as in trauma, tumor, or neurovascular disease, or while using the coracobrachialis as a vascularized muscle for transfer for the treatment of long standing facial paralysis.²⁷ The morphological variations of the coracobrachialis muscle might be due to failure of the muscle primordial to disappear during embryological development.²⁵ Aydin et al²⁸ and Budhiraja et al⁸ reported an absence of the musculocutaneous nerve. The authors added that, in these cases, the anterior flexor muscles of the arm and the sensation of the lateral surface of the forearm were normal and the motor and sensory branches arose from other nerves. In the present study, the musculocutaneous nerve was not seen in 2 limbs (3.3%), one right male and one left female. The median nerve of these 2 limbs innervated all the muscles of the anterior compartment of the arm except the coracobrachialis muscle of one limb where it was innervated by a direct branch from the lateral cord of the brachial plexus. The incidence rate of the absence of the musculocutaneous nerve was variable. It was noted in a frequency of 6%,¹⁷ 1.7%,²⁹ 3.6%,³⁰ and 11.2%.⁸ In such variations, injury of the median nerve produced unexpected paralysis of the flexor muscles of the arm and hypoesthesia of the lateral surface of forearm. To avoid the accidental injury of these nerves, surgeons should have previous knowledge of such variations before any surgical interference within the arm. These variations might also explain weakness in arm flexion in patients with thoracic outlet syndrome.⁸ Communication between the median and musculocutaneous nerves was previously reported.^{8,30,31} In the present study, the musculocutaneous nerve provided a communicating branch to the median nerve in 13.3% of the specimens. Its prevalence was found in 8.3% of male limbs and 5% of female limbs, and it was noticed in 5% of right limbs and 8.3% of left limbs. The incidence of a similar communication was reported as 16% by Krishnamurthy et al,³² 53.6% by Guerri-Guttenberg and Ingolotti,³⁰ and 20.7% by Budhiraja et al.⁸ This connection was described by different names, such as third root of median nerve,³² abnormal lateral root of median nerve,⁴ and additional lateral root.⁹ The main cause of such communication may be due to the common origin of both musculocutaneous and median nerve from the ventral rami of the spinal nerves.³² The formation of limb muscles and peripheral nerves during embryonic life is influenced by random factors. Any disturbance of one of these factors might be

attributed to such communications. Altered signaling between mesenchymal cells and neuronal growth cones or circulatory factors at the time of fusion of brachial plexus cords may produce significant variations in nerve patterns.⁶ Variations in formation pattern, site of beginning, course, relations, and distribution of the median nerve within the arm might increase the incidence of its injuries, and further study into the clinical significance of the median nerve course and relations within the forearm and hand is advisable to clarify the critical point of nerve compression within its full course.

In conclusion, this knowledge will help the clinicians to interpret unusual clinical manifestations, and guide anesthetists, surgeons, and orthopedics when performing surgical procedures involving the axilla and arm.

Acknowledgments. *The author extends deep thanks to Professor Mohamed H. Badawoud, Chairman of Anatomy Department, Faculty of Medicine, King Abdulaziz University for his great support and guidance. He also appreciates the efforts of all technical staff members.*

References

1. Standring S, editor. Gray's Anatomy: The anatomical basis of clinical practice. 40th ed. Edinburgh, London: Churchill Livingstone, Elsevier; 2008. p. 828-848.
2. Das S, Paul S. Anomalous branching pattern of lateral cord of brachial plexus. *Int J Morphol* 2005; 23: 289-292.
3. Yang HJ, Gil YC, Lee HY. Intersegmental origin of the axillary artery and accompanying variation in the brachial plexus. *Clin Anat* 2009; 22: 586-594.
4. Saeed M, Rufai AA. Median and musculocutaneous nerves: variant formation and distribution. *Clin Anat* 2003; 16: 453-457.
5. Bilecenoglu B, Uz A, Karalezli N. Possible anatomic structures causing entrapment neuropathies of the median nerve: an anatomic study. *Acta Orthop Belg* 2005; 71: 169-176.
6. Satyanarayana N, Vishwakarma N, Kumar GP, Guha R, Datta AK, Sunitha P. Variation in relation of cords of brachial plexus and their branches with axillary and brachial arteries – a case report. *Nepal Med Coll J* 2009; 11: 69-72.
7. Ramachandran K, Kanakasabapathy I, Holla SJ. Multiple variations involving all the terminal branches of the brachial plexus and the axillary artery - a case report. *Eur J Anat* 2007; 11: 61-66.
8. Budhiraja V, Rastogi R, Asthana AK, Sinha P, Krishna A, Trivedi V. Concurrent variations of median and musculocutaneous nerves and their clinical correlation – a cadaveric study. *Ital J Anat Embryol* 2011; 116: 67-72.
9. Sontakke BR, Tarnekar AM, Waghmare JE, Ingole IV. An unusual case of asymmetrical formation and distribution of median nerve. *International Journal of Anatomical Variations* 2011; 4: 57-60.
10. Uzun A, Seelig LL Jr. A variation in the formation of the median nerve: communicating branch between the musculocutaneous and median nerves in man. *Folia Morphol (Warsz)* 2001; 60: 99-101.

11. Goyal N, Harjeet, Gupta M. Bilateral variant contribution in the formation of median nerve. *Surg Radiol Anat* 2005; 27: 562-565.
12. Fazan VPS, Amadeu AS, Caleffi AL, Rodrigues Filho OA. Brachial plexus variations in its formation and main branches. *Acta Cir Bras* 2003; 18: 5.
13. Pandey SK, Shukla VK. Anatomical variations of the cords of brachial plexus and the median nerve. *Clin Anat* 2007; 20: 150-156.
14. Singhal S, Rao VV, Ravindranath R. Variations in brachial plexus and the relationship of median nerve with the axillary artery: a case report. *J Brachial Plex Peripher Nerve Inj* 2007; 2: 21.
15. Nene AR, Gajendra KS, Sarma MVR. Variant formation and course of the median nerve. *International Journal of Anatomical Variations* 2010; 3: 93-94.
16. Haviarova Z, El Falougy H, Killingerova A, Matejcik V. Variation of the median nerve course and its clinical importance. *Biomed Pap Med Fac Univ Palacky Olomouc Czech Repub* 2009; 153: 303-306.
17. Chitra R. Various types of intercommunications between musculocutaneous and median nerves: An analytical study. *Annals of Indian Academy of Neurology* 2007; 10: 100-104.
18. Vijaya PS, Vollala VR, Mohandas R, Shetty S. A rare entrapment of medial root of median nerve between axillary artery and its anomalous branch. *The Internet Journal of Neurology* 2006; 5 (2): DOI: 10.5580/1d62
19. Uysal II, Karabulut AK, Büyükmumcu M, Unver Dogan N, Salbacak A. The course and variations of the branches of musculocutaneous nerve in human fetuses. *Clin Anat* 2009; 22: 337-345.
20. Nayak S. Absence of musculocutaneous nerve associated with clinically important variations in the formation, course and distribution of median nerve – a case report. *Neuroanatomy* 2007; 6: 49-50.
21. Vollala VR, Raghunathanan D, Rodrigues V. Nerve compressions in upper limb: a case report. *Neuroanatomy* 2005; 4: 35-36.
22. George BM, Nayak SB. Median nerve and brachial artery entrapment in the abnormal brachialis muscle – a case report. *Neuroanatomy* 2008; 7: 41-42.
23. Paval J. A rare case of possible median nerve entrapment. *Neuroanatomy* 2006; 5: 35-36.
24. Kumar H, Das S, Gaur S. Entrapment of the median nerve and the brachial artery by lacertus fibrosis. *Arch Med Sci* 2007; 3: 284-286.
25. Potu BK, Rao MS, Nayak SR, Vollala VR, Mandava AK, Thomas H. Variant insertion of coracobrachialis muscle in a South Karnataka Cadaver. *Cases J* 2008, 1: 291.
26. Kopuz C, İçten N, Yildirim M. A rare accessory coracobrachialis muscle: a review of the literature. *Surg Radiol Anat* 2003; 24: 406-410.
27. Taylor GI, Cichowitz A, Ang SG, Seneviratne S, Ashton M. Comparative anatomical study of the gracilis and coracobrachialis muscles: implications for facial reanimation. *Plast Reconstr Surg* 2003; 112: 20-30.
28. Aydin ME, Kale A, Edizer M, Kopuz C, Demir MT, Corumlu U. Absence of the musculocutaneous nerve together with unusual innervation of the median nerve. *Folia Morphol (Warsz)* 2006; 65: 228-231.
29. Beheiry EE. Anatomical variations of the median nerve distribution and communication in the arm. *Folia Morphol (Warsz)* 2004; 63: 313-318.
30. Guerri-Guttenberg RA, Ingolotti M. Classifying musculocutaneous nerve variations. *Clin Anat* 2009; 22: 671-683. Review.
31. Bhattarai C, Poudel PP. Unusual variation in musculocutaneous nerves. *Kathmandu Univ Med J (KUMJ)* 2009; 7: 408-410.
32. Krishnamurthy A, Nayak SR, Venkatraya Prabhu L, Hegde RB, Surendran S, Kumar M, et al. The branching pattern and communications of the musculocutaneous nerve. *J Hand Surg Eur Vol* 2007; 32: 560-562.

ETHICAL CONSENT

All manuscripts reporting the results of experimental investigations involving human subjects should include a statement confirming that informed consent was obtained from each subject or subject's guardian, after receiving approval of the experimental protocol by a local human ethics committee, or institutional review board. When reporting experiments on animals, authors should indicate whether the institutional and national guide for the care and use of laboratory animals was followed. Research papers not involving human or animal studies should also include a statement that approval/no objection for the study protocol was obtained from the institutional review board, or research ethics committee.