

Hypertensive encephalopathy as the initial manifestation of Guillain-Barré syndrome in a 7-year-old girl

Ayman A. Aleyadhy, MD, Gamal M. Hassan, MD.

ABSTRACT

نعرض هنا حالة فتاة تبلغ من العمر 7 أعوام عانت من تشنجات واعتلال دماغي لفرط ضغط الدم كأعراض أولية وخطيرة للمظاهر اللاارادية المصاحبة لمتلازمة جيليان باري المصاحب لشلل الرخوي الثنائي الصاعد وأظهر تحليل السائل النخاعي تفاوت بين الخلايا والأليومين وأظهرت الدراسة أيضاً سرعة التوصيل العصبي لأعراض متلازمة جيليان باري وكانت الأجسام المضادة للجلوبولين المناعي M ميكروب المفطورة ايجابياً باختبار الوميض المناعي، نسلط الضوء في هذا التقرير على أهمية اعتبار متلازمة جيليان باري في التشخيص التفريقي لارتفاع ضغط الدم الحاد غير المبرر.

We report a case involving a 7-year-old girl who initially presented with seizure and hypertensive encephalopathy, serious autonomic manifestations associated with Guillain-Barré syndrome, followed by subsequent bilateral ascending flaccid paralysis. Cerebrospinal fluid analysis showed cytoalbuminous dissociation. Nerve conduction velocity tests showed features of demyelinating polyradiculoneuropathy. An immunofluorescence test of her serum was positive for mycoplasma immunoglobulin M antibody. The present case highlights the importance of considering the initial autonomic manifestations of Guillain-Barré syndrome in the differential diagnosis of unexplained acute hypertensive crisis.

Neurosciences 2013; Vol. 18 (2): 163-165

From the Pediatric Department, King Khalid University Hospital and College of Medicine, King Saud University, Riyadh, Kingdom of Saudi Arabia.

Received 3rd September 2012. Accepted 23rd December 2012.

Address correspondence and reprint request to: Dr. Ayman A. Aleyadhy, Head, Pediatric Intensive Care Unit, Assistant Professor & Consultant, Department of Pediatrics, College of Medicine, King Saud University, PO Box 2925, Riyadh 11461, Kingdom of Saudi Arabia. Tel. +966 (1) 4692001. Fax. +966 (1) 4692185. E-mail: aleyadhy@ksu.edu.sa

Guillain-Barré syndrome (GBS) is an autoimmune disorder characterized by demyelination and acute axonal degeneration, which causes acute flaccid paralysis in affected patients. Approximately 1 to 3 per 100,000 persons are affected annually.¹ Guillain-Barré syndrome is associated with an antecedent infection in two-thirds of patients,¹ and it is believed that the interaction between the infectious pathogen and the nervous system precipitates the autoimmune response. Guillain-Barré syndrome typically presents initially as fine, distal paresthesia followed by symmetrical lower extremity weakness that may ascend, over hours to days, to involve the arms and respiratory muscles.² Cardiovascular manifestations may include sinus tachycardia, arrhythmia, and blood pressure fluctuations as a result of autonomic system involvement.³ Nerve conduction velocity tests are used to confirm the diagnosis and are also used to differentiate between the heterogeneous subtypes of GBS. Treatment for GBS includes supportive care in addition to intravenous immunoglobulin, or plasmapheresis, or both. In most patients, the resolution of symptoms is complete or near complete; however, mortality related to GBS is most often associated with dysautonomia and respiratory complications.¹ A case involving a 7-year-old girl admitted to hospital for investigation of a painless hematuria who developed seizures and hypertensive encephalopathy, preceding classical manifestations of GBS, is described, which highlights the importance of considering GBS in the differential diagnosis of unexplained acute hypertension.

Case Report. A 7-year-old girl was admitted to hospital with a 2-year history of recurrent asymptomatic hematuria. Two weeks before admission, she had experienced an upper respiratory tract infection, which

Disclosure. The authors declare no conflicting interests, support or funding from any drug company.

resolved spontaneously. On admission, she was well and afebrile, with a heart rate of 108 beats/min, a respiratory rate of 22 breaths/min and a blood pressure (BP) of 105/70 mm Hg. Initial laboratory tests, including complete blood count, coagulation profile, urine analysis, and blood urea nitrogen, serum creatinine, and electrolyte levels, were all within normal limits. On day 2 of her hospital admission, she experienced diffuse headache associated with blurred vision and projectile vomiting. In addition, she experienced 2 separate attacks of generalized, tonic, clonic convulsions, cyanosis, and upward rolling of the eyes 15 minutes apart, which were successfully treated using intravenous diazepam (Valium; Hospira, Lake Forest, Illinois, USA) and intravenous phenytoin (Baxter Healthcare Corporation, Deerfield, Illinois, USA). During the convulsions, her heart rate was 150 beats/min, respiratory rate was 28 breaths/min and her BP was 170/120 mm Hg; otherwise, her physical examination was unremarkable. A CT scan, MRI, magnetic resonance angiography, and magnetic resonance venography of her brain were unremarkable. She was transferred to the pediatric intensive care unit (PICU) with a Glasgow Coma Scale score of 12/15,⁴ tachycardia, and severe hypertension. Her clinical neurological examination was otherwise unremarkable. She was treated with intravenous labetalol (Gland Pharma Limited, Hyderabad, India) and a sodium nitroprusside infusion (Nitroprussiate Fides; Rottapharm, Barcelona, Spain) and later was also prescribed oral captopril (Capril; Spimaco, Riyadh, Saudi Arabia). These medications were introduced gradually and titrated according to invasive BP monitoring over her stay in the PICU. Repeated investigations, including a complete blood count and blood urea nitrogen, serum creatinine and electrolyte levels, were all normal. Urine analysis continued to show hematuria without red blood cell casts.

On day 2 of her PICU stay, she developed lower limb weakness associated with paresthesia, diminished deep tendon reflexes and exhibited grade 4 muscle power for different muscle groups of both the upper and lower limbs, which continued to deteriorate over the next few days to be bed or chair bound corresponding to Hughes grading score of 4 (Figure 1). The rest of her neurological examination was unremarkable. The CSF analysis revealed a white blood cell count of 1/mm³, a red blood cell count of 11/mm³ and a CSF protein level of 0.95g/L. A Gram-stain, CSF culture, and polymerase chain reaction test for herpes simplex virus were all negative. An EEG was normal. Nerve conduction velocity tests on the left median, left ulnar, left peroneal, left tibial, and left

sural nerves confirmed the diagnosis of demyelinating polyradiculoneuropathy. Serum mycoplasma tests using immunofluorescence were positive for immunoglobulin M. Additional investigations for possible precipitating factors for her hypertension, including, renal Doppler ultrasound, renovascular angiogram, technetium dimercaptosuccinic acid renal isotope scan, abdominal CT scan, abdominal MRI scan, 24 h urinary vanillylmandelic acid test, echocardiography, erythrocyte sedimentation rate, antineutrophil cytoplasmic antibody, antinuclear antibody, and serum levels of complements 3 and 4, were all unremarkable. She received intravenous immunoglobulins (Octagam 5%; Octapharma, Lanchen, Switzerland) for her GBS, and clarithromycin (Klacid, Abbott, Abbott Park, Illinois, USA) for her mycoplasma infection. Over her 19-day stay in the PICU, her extremity weakness improved (Figure 1) without respiratory compromise. Her BP normalized, and all antihypertensive medications were discontinued. She was prescribed carbamazepine (Tegretol, Novartis, Basel, Switzerland) maintenance therapy with neurology follow-up and was transferred to the general pediatric ward. Three weeks later, she had regained normal muscle power, remained normotensive and her convulsions were controlled; however, the cause of her recurrent painless hematuria could not be found.

Discussion. In the present case of GBS, hypertensive encephalopathy was an initial, and rare, manifestation of the disease that preceded other neurological findings, which we initially believed were related to the patient's recurrent painless hematuria. A thorough investigation of possible renal etiologies was inconclusive; therefore, other causes of hypertension were considered. Neuroimaging studies ruled out intracranial causes, such as hemorrhage or space-occupying lesions. Echocardiography showed a normal heart and great

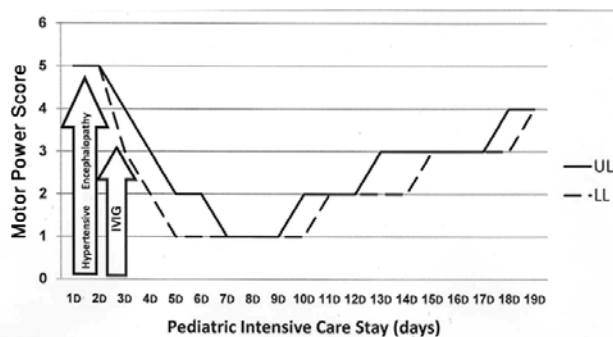


Figure 1 - Motor power in lower and upper limbs throughout the pediatric intensive care stay. UL - upper limbs, LL - lower limbs, D - day, IVIG - intravenous immunoglobulin

vessels. A diagnosis of pheochromocytoma was unlikely due to her normal levels of urinary catecholamine metabolites, and the normal findings on her abdominal CT and MRI examinations. Other possible causes of hypertension (for example, collagen vascular diseases) were also unlikely due to the lack of clinical signs and/or other systemic manifestations of an autoimmune process. Moreover, her full recovery makes porphyria, a disease requiring specific therapy, less likely to be the cause of her symptoms. Guillain-Barré syndrome was included in our differential diagnosis due to the day 2 findings of diminished deep tendon reflexes, decreased motor power and paresthesia involving both her upper and lower limbs. Also, the onset of the hypertension and its recovery, are timely associated with the onset and recovery of GBS, which makes other causes such as renal pathology unlikely to contribute to the presentation.

Signs of autonomic dysfunction are present in 50-60% of GBS patients, and are usually associated with severe cases of the disease common in young adults, and may contribute to GBS-related mortality. Autonomic cardiac changes associated with GBS include labile hypertension, orthostatic hypotension, and cardiac arrhythmias, such as tachycardia, brady-arrhythmias, and asystole.⁵ Autonomic manifestations in GBS occur due to the unbalanced activities of the sympathetic and parasympathetic pathways. Hypertension in such patients may be ascribed to sympathetic nervous system hyperactivity due to reduced inhibition of the vasomotor centers or secondary to renin or catecholamine release.⁶ In previous studies, hypertension was reported in up to 66.7% of GBS cases, with variable correlation with respiratory function deterioration.⁷ Hypertension, as a presenting finding of GBS, has been described in a previous report.⁸ The association of transient hypertension and a syndrome involving inappropriate secretion of antidiuretic hormone was also reported in cases of GBS.⁹ The association between hypertensive encephalopathy with seizures, and GBS has not been reported in the literature to date. The role of hypertension in the prognosis of GBS is debatable; children with a greater degree of hypertension and/or tachycardia have been reported to experience more severe motor disability during their illness.¹⁰ Despite

presenting with severe hypertensive encephalopathy before the appearance of classic manifestations of GBS, our patient experienced a complete neurological recovery and was able to maintain control of her BP.

In conclusion, autonomic manifestations of GBS can be serious and life threatening if not recognized early and properly treated. These abnormalities may be the earliest presenting manifestations of GBS before the classic features become evident. The initial autonomic manifestations of GBS should be considered in the differential diagnosis of an acute hypertensive crisis.

Acknowledgments. *This work was supported by the College of Medicine Health Research Center, Deanship of Scientific Research, King Saud University, Riyadh, Kingdom of Saudi Arabia.*

References

1. Newswanger DL, Warren CR. Guillain-Barré syndrome. *Am Fam Physician* 2004; 69: 2405-2410.
2. Green DM, Ropper AH. Mild Guillain-Barré syndrome. *Arch Neurol* 2001; 58: 1098-1101.
3. Dages N, Haude M, Baumgart D, Sack S, Erbel R. Assessment of coronary morphology and flow in a patient with Guillain-Barré syndrome and ST-segment elevation. *Clin Cardiol* 2001; 24: 260-263.
4. Teasdale G, Jennett B. Assessment of coma and impaired consciousness. A practical scale. *Lancet* 1974; 2: 81-84.
5. Patel MB, Goyal SK, Punnam SR, Pandya K, Khetarpal V, Thakur RK. Guillain-Barré Syndrome with asystole requiring permanent pacemaker: a case report. *J Med Case Rep* 2009; 3: 5.
6. Davidson DL, Jellinek EH. Hypertension and papilloedema in the Guillain-Barré syndrome. *J Neurol Neurosurg Psychiatry* 1977; 40: 144-148.
7. Annane D, Baudrie V, Blanc AS, Laude D, Raphaël JC, Elghozi JL. Short-term variability of blood pressure and heart rate in Guillain-Barré syndrome without respiratory failure. *Clin Sci (Lond)* 1999; 96: 613-621.
8. Al-Eissa YA, Al-Herbish AS. Severe hypertension: an unusual presentation of Guillain-Barré syndrome in a child with brucellosis. *Eur J Pediatr* 1996; 155: 53-55.
9. Kaneko K, Shioya T, Yabuta K. Inappropriate secretion of antidiuretic hormone and transient hypertension associated with Guillain-Barré syndrome. *Pediatr Neurosci* 1989; 15: 257-259.
10. Singh NK, Jaiswal AK, Misra S, Srivastava PK. Assessment of autonomic dysfunction in Guillain-Barré syndrome and its prognostic implications. *Acta Neurol Scand* 1987; 75: 101-105.