

Neurosciences Quiz

Submitted by: Ramachandiran Nandbagopal, MBBS, DM.

From the Neurology Unit, Department of Medicine, College of Medicine and Health Sciences, Al-Khod, Muscat, Oman.

Address correspondence to: Dr. Ramachandiran Nandbagopal, Consultant Neurologist, Neurology Unit, Department of Medicine, College of Medicine and Health Sciences, PO Box 35, Sultan Qaboos University, Al-Khod 123, Muscat, Oman. Tel. +968 24143404. Fax. +968 24413419. E-mail: drrmandagopal@gmail.com

Notice: Authors are encouraged to submit quizzes for possible publication in the Journal. These may be in any field of Clinical Neurosciences, and should approximately follow the format used here. Please address any submissions to the Assistant Editor, Neurosciences Journal, Riyadh Military Hospital, PO Box 7897, Riyadh 11159, Kingdom of Saudi Arabia. E-mail: sdouglas@psmmc.med.sa

Triple brain insults following cranial trauma

Clinical Presentation

Four days after cranial trauma, a 41-year-old man presented with fever, headache, confusion, and neck stiffness. He had received antibiotics in an outside hospital for these symptoms. There was no history of CSF rhinorrhea or otorrhea or chronic suppurative otitis media. He underwent cranial diffusion weighted MRI (Figures 1A & 1B), post contrast T1 weighted image (Figure 1C), apparent diffusion coefficient map (Figures 1D & 1E), and MRI venogram (Figure 1F). The CSF analysis showed 5960 cells with 80% neutrophils and 20% lymphocytes and elevated protein (400 mg/dl) and tested positive for *Streptococcus pneumoniae* antigen.

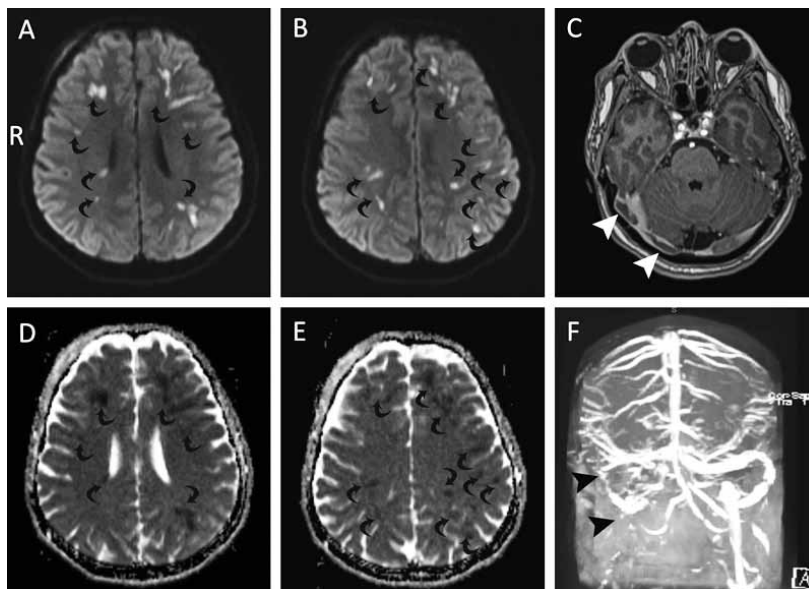


Figure 1 - Axial cranial MRI showing: A & B) Diffusion weighted image (diffusion sensitivity factor $b=1000 \text{ sec/mm}^2$); C) Post contrast T1 weighted image. D & E) Corresponding apparent diffusion coefficient map. F) Time-of-flight MR venogram.

Questions:

1. What did the patient's symptoms indicate?
2. What abnormalities are observed in Figures 1A-1F?
3. What clinical diagnosis/diagnoses would you consider in this patient?
4. What treatment would you institute for him?

Neurosciences Quiz

Answers

1. The presence of febrile illness of short duration along with headache, altered mental status, and neck stiffness favored a diagnosis of acute meningoencephalitis. In the setting of trauma, post-traumatic meningitis was a possibility. Alternative cause(s) for the secondary headache included traumatic subarachnoid hemorrhage, subdural or epidural hematoma, traumatic intra-cerebral hemorrhage, skull fracture, and dissection of cranial arteries (note that the brain parenchyma alone is insensitive to pain and diffuse axonal injury might not result in significant headache). Neuroimaging scans would aid in establishing these competing diagnoses (see answer to question 2). Although some of these alternative conditions could be associated with fever, one must have a high threshold for considering the possibility of infectious etiology such as acute meningitis. Further diagnostic details are provided in the answer to question 3.

2. Diffusion weighted brain MRI (**Figures 1A & 1B**) showed multiple, mostly linear, bright signals predominantly in the subcortical white matter (black curved arrows). These lesions were dark on the corresponding apparent diffusion coefficient map (**Figures 1D & 1E**, black curved arrows) attesting to restricted diffusion. In the setting of trauma, these changes are highly suggestive of diffuse axonal injury.¹ There were no hemorrhagic components in these lesions on susceptibility weighted MRI (not shown). In addition, gadolinium (contrast) enhanced MRI (**Figure 1C**, white arrow-heads) and MR venogram (**Figure 1F**, black arrow-heads) showed partial filling defect in the right lateral sinus suggestive of partial dural sinus thrombosis.

3. The presence of clinical symptoms and signs of meningeal irritation (neck stiffness, fever, headache, and altered mental status) and abnormal CSF with a neutrophil-predominant pleocytosis and the detection of pneumococcal antigen (in this patient who had received antibiotics prior to lumbar puncture) suggested partially treated pyogenic meningitis. In the setting of recent trauma, post-traumatic meningitis was considered. However, there were no features of CSF rhinorrhea, otorrhea, or suppurative otitis media. In addition, brain imaging (**Figures 1A, 1B, 1D, 1E**) confirmed the presence of diffuse axonal injury in this patient who sustained recent cranial trauma. The other finding included partial right lateral sinus thrombosis (**Figures 1C & 1F**). In short, this patient had a diagnostic triad of partially treated pneumococcal meningitis, diffuse axonal injury, and right lateral sinus thrombosis.

4. The patient needed care of airway, breathing, and circulation so as to maintain his vital parameters. For pneumococcal meningitis where the antibiotic sensitivity pattern is not known, ceftriaxone and vancomycin should be instituted. The duration of treatment depends on the clinical response. If there is good clinical response (subsidence of fever, confusion, headache), the same antibiotics should be continued for 2 weeks. Monitoring of renal parameters, electrolytes, blood glucose, and vancomycin levels should be part of the overall management. Treatment of cerebral venous thrombosis in the setting of meningitis is controversial and the available recent case series in the setting of septic lateral sinus thrombosis (mostly related to suppurative otitis media) in children have reported anticoagulation as a favorable option.²⁻⁴ The benefits and risks of anticoagulation have to be balanced especially in the setting of recent trauma. Of note, this patient did not have any loculated pus or infection in the ears or paranasal sinuses for surgical drainage.

Discussion

Cranial trauma has been recognized as an important risk factor for bacterial meningitis.⁵ Following trauma, this patient had a triad of brain insults; namely, partially treated pneumococcal meningitis, diffuse axonal injury, and right lateral sinus thrombosis. The proximate cause of the dural sinus thrombosis (whether it was related to undetected hypercoagulable state or to trauma and meningitis) could not be clearly established. Initially, he was very sick requiring ventilatory assistance. Subsequently, his level of consciousness improved with a 2 week course of antibiotics (ceftriaxone and vancomycin), and low molecular heparin in a therapeutic dose (instituted for the right lateral sinus thrombosis extending into the right internal jugular vein). At discharge, he was fully conscious but had ataxia and cognitive sequelae including marked anterograde amnesia. Although he did not have overt CSF rhinorrhea or otorrhea, he should undergo cisternography to identify any focus of CSF leak for surgical closure to prevent recurrent meningitis. A recommendation was made for this investigation in a hospital in his native country.

References

1. Huisman TA, Sorensen AG, Hergan K, Gonzalez RG, Schaefer PW. Diffusion-weighted imaging for the evaluation of diffuse axonal injury in closed head injury. *J Comput Assist Tomogr* 2003; 27: 5-11.
2. Neilan RE, Isaacson B, Kutz JW, Jr., Lee KH, Roland PS. Pediatric otogenic lateral sinus thrombosis recanalization. *Int J Pediatr Otorhinolaryngol* 2011; 75: 850-853.
3. Ropposch T, Nemetz U, Braun EM, Lackner A, Walch C. Low molecular weight heparin therapy in pediatric otogenic sigmoid sinus thrombosis: a safe treatment option? *Int J Pediatr Otorhinolaryngol* 2012; 76: 1023-1026.
4. Saposnik G, Barinagarrementeria F, Brown RD, Jr., Bushnell CD, Cucchiara B, Cushman M, et al. Diagnosis and management of cerebral venous thrombosis: a statement for healthcare professionals from the American Heart Association/American Stroke Association. *Stroke* 2011; 42: 1158-1192.
5. Benca J, Lesnakova A, Holeckova K, Ondrusova A, Wiczmandyova O, Sladecko V, et al. Pneumococcal meningitis in community is frequent after craniocerebral trauma and in alcohol abusers. *Neuro Endocrinol Lett* 2007; 28 Suppl 3: 16-17.