

Intracranial tuberculoma

Tayseer M. Zein, MBBS, MRCP (UK), Peter S. Fletcher, MD, FRCPath, Zein M. Mirghani, BSc, PhD.

ABSTRACT

Six patients with cerebral tuberculoma seen over a 2 year period are reported. Their clinical presentations, the result of investigations including radiological findings and their response to medical treatment are discussed and correlated with other reports in the literature. Eighty five percent of the patients were above the age of 30 years. All patients had negative past history of tuberculosis and both chest x-ray and erythrocyte sedimentation rate were within normal limits. Five patients presented with symptoms and signs of space occupying lesions but none had papilloedema. Two patients showed paradoxical enlargement or development of new tuberculous lesions during antituberculous therapy. The diagnosis was established by brain magnetic resonance imaging in 3 patients, and was further confirmed by brain biopsy in the other 3. All patients received antituberculous treatment for 12 months, except one who continued medication for 2 years. Four patients normalized with medical treatment. Intracranial tuberculoma must be included in the differential diagnosis of a space occupying lesion. Magnetic resonance imaging is a sensitive, non-invasive method to diagnose cerebral tuberculoma. Paradoxical enlargement or development of new tuberculomas during antituberculous therapy is a documented phenomenon which can be overcome by continuation of antituberculous treatment. Twelve months of antituberculous treatment is considered to be adequate to resolve intracranial tuberculoma.

Keywords: Intracranial tuberculoma, papilloedema, magnetic resonance imaging, brain biopsy.

Neurosciences 2000; Vol. 5 (2): 131-134

Although the lungs are the main port of entry and bear the major clinical brunt of tuberculosis, the disease can be a disseminated infection. Even before human immunodeficiency virus (HIV) infection became wide-spread, about 15% of all newly recognized cases of tuberculosis were extrapulmonary.¹ Intracranial tuberculoma is one form of central nervous system (CNS) tuberculosis. It presents a more subtle clinical picture than tuberculous meningitis.² The usual presentation is that of a slow-growing focal lesion, although few patients develop cerebral tuberculoma in the course of tuberculous meningitis.³ Fever and general ill-health are unusual findings but a past history of tuberculosis or evidence of active infection outside the CNS occurs in less than one third of patients.⁴ Except in children and HIV infected adults, there is typically a long latent period between the first episode of infection and the development of intracerebral tuberculoma.^{5,6} The diagnosis is

established by computerized tomography (CT) scanning or magnetic resonance imaging (MRI) with or without subsequent biopsy.⁷ Medical treatment is preferable to surgery which is reserved for diagnosis, or for treatment of complications.⁸ The response to antituberculous chemotherapy is good and corticosteroids are indicated only if there is an increase in intracranial pressure.

Case Report. Six patients with intracranial tuberculomas were admitted to our hospital between 1995-1997. For each patient, age, country of origin, history of previous exposure to active tuberculosis, presenting symptoms and neurological findings were recorded. This data, as well as laboratory and radiological results, histopathological report of brain biopsies and the response to antituberculous therapy is summarized in Table 1. Only one patient (patient no. 3) was immunocompromised. She had idiopathic

From the Department of Medicine and Pathology, Armed Forces Hospital Southern Region, Khamis Mushat (Zein, Fletcher) and the Department of Biochemistry, College of Medicine, King Saudi University, Abha, (Mirghani), Kingdom of Saudi Arabia.

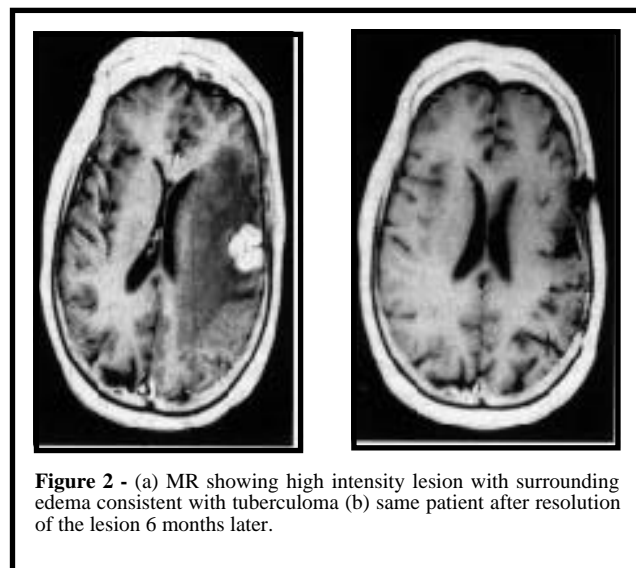
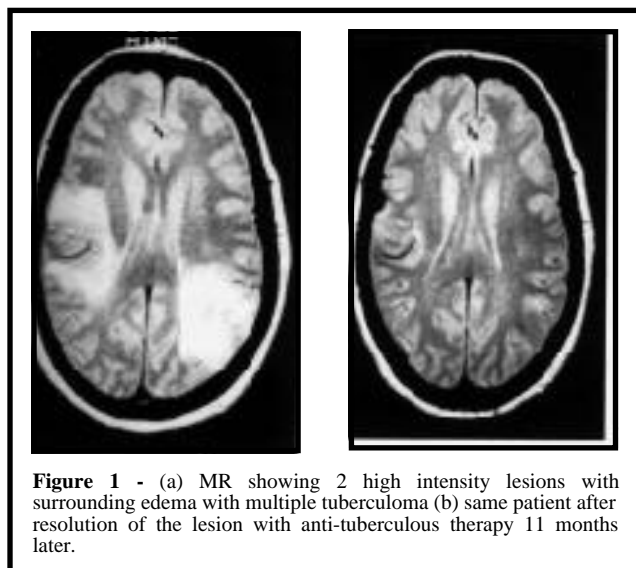
Published with special permission from Saudi Medical Journal.

Address correspondence and reprint request to: Dr. T. Zein, Armed Forces Hospital, Southern Region, PO Box 101, Khamis Mushayt, Kingdom of Saudi Arabia. Tel/Fax. +00966 (7) 2511550. Fax. +00966 (7) 2247570.

Table 1 - A table showing a summary of personal data, laboratory, neuroimaging and histopathological results of 6 patients with intracranial tuberculomas.

	1	2	3	4	5	6
Age/Sex	34/m	27/M	41/F	58/F	60/F	65/M
Nationality	Saudi	Indian	Saudi	Saudi	Saudi	Saudi
Immuno-compromised status	No	No	Yes (on steroids)	No	No	No
Clinical presentation	Tuberculous meningitis	Headache, diplopia	Seizures	Focal fits motor asphyxia left hemiparesis	Left-dense hemiplegia	Left hemiparesis
Previous history of tuberculosis	None	None	None	None	None	None
Papilloedema	No	No	No	No	No	No
Chest x-ray	Negative	Negative	Negative	Negative	Negative	Negative
Sedimentation Rate (1st/hr)	12 mm/hr	6mm/hr	19mm/hr	20mm/hr	10mm/hr	7mm/hr
Tuberculin test	Not done	Note done	5mm positive	Not done	Not done	Not done
Localization of tuberculoma	Supra and infratentorial	Infratentorial	Supratentorial	Supratentorial	Supratentorial	Supra and infratentorial
MRI brain findings	Multiple masses with high signals	Solitary occipital mass with extensive edema	Multiple lesions with intense enhancement	Solitary parietal mass with massive edema	Right multiple enhancing lesions plus right falx meningioma	Multiple enhancing lesions
Brain biopsy	Not done	Multiple caseating granuloma	Caseating granulomas	Caseating granuloma	Not done	Not done
Brain biopsy culture for AFB	Not done	Negative	Positive	Negative	Not done	Not done
Response to antituberculous medication	Moderate	Complete cure	Complete cure	Complete cure	Poor	Complete cure
Residual neurological deficit	Epilepsy visual field defect	None	None	None	Left dense hemiplegia	None

AFB - Acid Fast Bacilli MRI - Magnetic Resonance Imaging 1st/1hr - First hour



thrombocytopenic purpura and was on steroids for 8 years prior to hospital admission. None of the patients had a positive HIV test. Patient no. 1 developed cerebral tuberculoma during the course of tuberculous meningitis. Three patients underwent surgery for brain biopsy. Patient no. 2 was started on antituberculous therapy, but a follow up CT brain scan after 6 weeks showed paradoxical expansion of the cerebral lesion. Brain biopsy was carried out to confirm the diagnosis. All patients had brain CT scan and MRI carried out before, and every 3 months following antituberculous treatment. Neuroimaging of patient no. 3 (Figure 1a and 1b) and patient no. 4 (Figure 2a and 2b) before and after antituberculosis therapy are shown. Five patients received antituberculous treatment for 12 months with complete cure except for one patient (patient no. 5) who had an associated inoperable right falx meningioma. One patient (patient no. 1) received antituberculous therapy for 2 years because he continued to develop new cerebral lesions even after adequate antituberculous medications for more than one year. He continued to have visual field defect and epilepsy.

Discussion. In this study, the patients investigated for intracranial tuberculoma are mostly above 30 years of age which is in contrast with other investigators. They report that between 60 and 80% of their patients are below 30 years.⁹ Further, none of our patients presented with papilloedema which is reported as an important presenting sign of intracranial tuberculoma.⁹ Two types of cerebral tuberculoma have been classified. A superficial vascular type that produces early focal signs, usually with no increase in intracranial pressure. The 2nd type is a deep vascular type accompanied with increased intracranial pressure.¹⁰ Our patients possibly belong to the first type of cerebral tuberculoma and thus none of them had papilloedema. Erythrocyte sedimentation rate (ESR) is considered to be a helpful test for diagnosis of pulmonary and extrapulmonary tuberculosis and is reported to be raised in cerebral tuberculoma in a small percentage of cases.¹⁰ However, all our patients had normal ESR.

It has been reported that the predominant locations of tuberculoma are supratentorial in adults and infratentorial in children.¹¹ Half of our patients had infratentorial tuberculomas. Brain stem tuberculomas are reported to be uncommon, accounting for 2.5% to 8% of all intracranial tuberculomas.^{12,13} In our patients, 2 (patient no. 1 & 6) out of 6 (33%) developed brain stem tuberculomas. Most of the patients (5 out of 6, 67%) had multiple tuberculomas. Other studies report that solitary tuberculomas are found in 66% of cases while multiple tuberculomas represent only 15-34%.¹⁴⁻¹⁶

Two patients (patient no. 1 & 2) have shown the peculiar phenomenon of paradoxical enlargement or development of new tuberculomas while receiving appropriate antituberculous therapy. Such a paradoxical response is thought to be due to a hypersensitivity reaction to mycobacterial products.¹⁷ This phenomenon generally occurs within 3 months from the start of therapy.¹⁸ One patient who had tuberculous meningitis (patient no. 1) continued to develop new tuberculomas even after one year of antituberculous therapy. Such a paradoxical response should be looked for if the patient develops new neurological symptoms or signs during the course of the disease.¹⁹ In patient no. 2, continuation of antituberculous therapy resulted in regression of the tuberculoma within the following 2 months, while in the other patient with tuberculous meningitis (patient no. 1), adjunctive therapy with steroids appeared to improve the outcome. This is in keeping with others who found that the tuberculoma responded to the same regimen of antituberculous therapy with or without corticosteroids.²⁰ Five patients received 12 months of antituberculous treatment with complete resolution of intracranial tuberculomas as shown radiologically. Short course regimens of 9 months duration are reported as effective in the treatment of cerebral tuberculoma.²¹

In our series, Brain MRI is found to be more sensitive than CT scan in detecting intracranial tuberculomas. This is in keeping with other reports which reported that brain CT scan alone can not differentiate a tuberculoma from an abscess or other granulomatous process.²² Also, CT scan is shown to have low positive predictive value 33% (with confidence limits 24-42%) for the diagnosis of intracranial tuberculoma.²³ Cerebral tuberculomas are shown to have specific magnetic resonance signal intensity patterns, and enhancement patterns corresponding to their histopathological features.^{24,25}

We conclude that intracranial tuberculoma is not an uncommon disease in Saudi Arabia. Therefore, it should be included in the differential diagnosis of all patients presenting with symptoms and signs of space occupying lesion irrespective of age or negative history of exposure to tuberculosis.

Acknowledgments. The authors are grateful to Professor N. Murad for reviewing the manuscript and to Mr. A. M. Al-Hassan for preparing the histopathological slides. The excellent secretarial work of Mr. Arnold Pagayon is greatly acknowledged.

References

1. Rieder HL, Sinder DE Jr., Cauthen GM. Extrapulmonary tuberculosis in the United States. *Am Rev Respir Dis* 1990; 141: 347-351.
2. Danergis JA, Leftwich EI, Curtin JA, Witorsh P. Tuberculoma of the brain. *JAMA* 1978; 239 (5): 413-415.

3. Hopewell CP, Bloom RP. Tuberculosis and other mycobacterial diseases. *Respir Med* 1994; (1): 1136-1137.
4. Clifford CD. Tuberculosis. *Office Practice of Neurology* 1996; 373-374.
5. Dale DC, Federman DD. Infections due to Mycobacteria *Scientific American Medicine* 1995; VIII: 1-20.
6. Martinez VC, Bordon J, Rodriguez GA. Cerebral Tuberculoma - a comparative study in patients with and without HIV infection. *Infection* 1995; 23 (3): 149-153.
7. Whelan M, Stern J. Intracranial tuberculoma. *Radiology* 1981; 138: 75-81.
8. Gropper MR, Schulder M, Sharan AD, Cho ES. Central nervous system tuberculosis, medical management and surgical indications. *Surg Neurol* 1995; 44 (4): 378-384.
9. Arvind C, Korath MP, Raoendranadhan K, Jagadeesan K. A retrospective study of 1247 cases of intracranial tuberculomata diagnosed by computerized Tomography. *J Assoc Physicians India* 1993; 41(9): 559-561.
10. Martinez-Lacasa JT, Burillo J, Niubo R, Rufi G, Podzameczer D, Mariscal A et al. Cerebral Tuberculoma. Report of 8 cases. *Med Clin (Barc)* 1991; 97(6): 218-223.
11. Traub M. Tuberculosis of the central nervous system. *Clinical Neurology* 1991; Vol 1: 875-877.
12. Gropper MR, Schulder M, Dutan HL, Wolansky L. Cerebral tuberculosis with expansion into brain stem tuberculoma. Report of two cases. *J Neurosurg* 1994; 81(6): 927-931.
13. Talamas O, Del Bulto OH, Garcia-Ramos G. Brain stem tuberculoma: An analysis of 11 patients. *Arch Neurol* 1989; 46: 529-535.
14. Gurses N, Aydin M. Intracranial tuberculoma. *Microbiol Bul* 1992; 26(2): 163-169.
15. Asenjo A, Valladares H, Fierro J. Tuberculomas of the brain: Report of 159 cases. *Arch Neurol Psychiatry* 1951; 65: 146-160.
16. Sibley WA, O'Brien JL. Intracranial tuberculomas, a review of clinical features and treatment. *Neurology* 1956; 6: 157-165.
17. Afghani B, Lieberman JM. Paradoxical enlargement or development of intracranial tuberculomas during therapy: Case report and review. *Clin Infect Dis* 1994; 19(6): 1092-1099.
18. Wong GW, Oppenheimer SJ, Poon W, Leung R. Intracranial tuberculoma and hydrocephalus developing during treatment of tuberculous meningitis. *J Trop Med Hyg* 1994; 97(4): 236-238.
19. Abdull Jabbar M. Paradoxical response to chemotherapy for intracranial tuberculoma: Two case reports from Saudi Arabia. *J Trop Med Hyg* 1991; 94(6): 374-376.
20. Nozaki H, Takashima S, Ishihara T, Aoyagi T. Paradoxical expansion of intracranial tuberculomas during chemotherapy. *Rinsho Shinkeigaku* 1992; 32(1): 91-93.
21. Rajeswani R, Sivasubramanian S, Balambal R, Parthasarathy R, Ranjani R, Santha T et al. A controlled clinical trial of short course chemotherapy for tuberculoma of the brain. *Tuber Lung Dis* 1995; 75(4): 311-317.
22. Konsuoglu SS, Ozcan C, Ozmenoglu M, Aydin N, Komsuoglu B. Intracranial tuberculoma: Clinical and computerized tomographic findings. *Isr J Med Sci* 1994; 30 (2): 153-157.
23. Selvapandian S, Rajshekhar V, Chandy MJ, Idikula J. Predictive value of computed tomography-based diagnosis of intracranial tuberculomas. *Neurosurgery* 1994; 35(5): 845-850.
24. Kim TK, Chang KH, Kim CJ, Goo JM, Kook MC, Han MH. Intracranial tuberculoma: Comparison of MR with pathological findings. *Am J Neuroradiol* 1995; 16(9): 1903-1908.
25. Gupta RK, Pandey R, Khan EM, Mittal P, Gujral RB, Chhabra DK. Intracranial tuberculomas: MRI signal intensity correlation with histopathology and localized proton spectroscopy. *Magn Reson Imaging* 1993; 11(3): 443-449.