

Accidental tricyclic antidepressant poisoning in a 2 year-old boy

Parameswaran M. Nair, DM, MNAMS, Alexander Chacko, MD, DCH, Poothirikovil Venugopalan, MD, FRCPC.

ABSTRACT

We present a 2-year old boy with accidental ingestion of a tricyclic antidepressant and outline the clinical features, management and prevention. Despite ingesting a high dose of amitriptyline (20mg/kg) and showing serum levels above the toxic range (1380 ng/ml), our patient did not develop any life threatening complications. Gastric lavage followed by instillation of activated charcoal, repeated at 6 hours, along with supportive measures led to complete recovery in 48 hours. As children are often exposed to tricyclic antidepressant poisoning, their carers and physicians need to be well aware of the disorder and its management.

Keywords: Accidental poisoning, children, amitriptyline, tricyclic antidepressants, cardiac arrhythmia.

Neurosciences 2002; Vol. 7 (1): 50-52

Children aged one to 4 years are prone to accidental ingestion of medications and insecticides. We present here a 2-year old boy who had accidental poisoning with amitriptyline, one of the tricyclic antidepressants (TCA), and outline the management.

Case Report. A 2-year old Omani boy was brought to the accident and emergency department of our hospital 2 hours after ingestion of 9 tablets of amitriptyline (25 mg tablets), a total dose of 20 mg/kg body weight. The medication had been prescribed for the mother and the tablets had inadvertently been left on the table by the mother. Examination revealed a well-grown young boy who was comatose and not responding even to painful stimuli. Pupils were dilated and reacting sluggishly to light. He also had dry mouth, facial flushing and fine erythematous rash over the body. He was tachycardiac, had normal blood pressure and required nasal oxygen (3L/minute) to maintain his saturation. Airway was secured and gastric lavage performed in the accident

and emergency department. Thirty gm of charcoal in 240 ml water was left in the stomach. He was admitted to the Intensive Care Unit (ICU) and commenced on intravenous fluids, thiamine, naloxone and sodium bicarbonate. Serum electrolytes, full blood counts and blood gas analysis were normal. Electrocardiogram (ECG) shows sinus tachycardia, normal QRS duration (0.09 second), prolonged corrected QT (QTc) interval of 0.52 seconds, and T wave inversion in lateral chest leads (**Figure 1**). Serum TCA level at 3 hours post ingestion was 1380ng/ml (well above the toxic level). Gastric lavage and instillation of activated charcoal were repeated at 6 hours, to remove any residual TCA resulting from entero-hepatic circulation.

The child exhibited considerable waxing and waning of sensorium which, improved in the next 8 hours, although he remained drowsy and irritable. Electrocardiogram did not show any evidence of cardiac arrhythmia. In approximately 24 hours, he became alert, playful and accepted oral feeds. The

From the Department of Child Health, Sultan Qaboos University Hospital, Muscat, Sultanate of Oman.

Received 17th February 2001. Accepted for publication in final form 7th July 2001.

Address correspondence and reprint request to: Dr. P. Venugopalan, Consultant Pediatrician, Child Ward 2, Sultan Qaboos University Hospital, PO Box 38, PC 123, Muscat, Sultanate of Oman. Tel. +968 513562. Fax. +968 5130009. E-mail: gopalax@omantel.net.om

parents were counselled on prevention of similar episodes and the proper use of child-safe bottles for keeping medications. The child was discharged after 48 hours.

Discussion. Accidental ingestion of TCA, especially amitriptyline, represents a potentially lethal intoxication frequently reported in children of the United States of America and Europe.¹⁻⁴ A 2-year review of the poisoning cases at the Sultan Qaboos University Hospital^{5,6} has shown similar results and children aged one to 4 years formed 36% of the patients studied. The clinical features are predominantly neurologic and cardiovascular. In a study on 45 affected children,^{4,7} the major manifestations included cardiac conduction disturbances (40%), coma (26%), lethargy/disorientation (31%) and generalised seizures (16%). Neurologic changes develop generally within 6 hours of ingestion and persist for 24-48 hours. Lethargy, confusion, disorientation and ataxia are the initial effects and may progress to seizures, coma and respiratory depression.^{3,4} Cardiovascular toxicity includes fatal ventricular arrhythmias and refractory hypotension. Electrocardiogram changes are prolonged QRS and QTc intervals, first degree heart block, rightward shift in the terminal 40 milliseconds of the QRS axis and intraventricular conduction delays.^{1,8} QRS duration of ≥ 0.10 seconds has been associated with increased incidence of seizures and ≥ 0.16 seconds with ventricular dysrhythmias.^{9,10} Severe cardiac toxicity generally develops within 6 hours, although ECG changes may persist for 48 hours.⁹ Other anti-cholinergic effects include mydriasis, blurred vision, dry mouth and urinary retention. Serum TCA levels have been used as markers of severity, however published studies have not yielded uniform results. The therapeutic range for

most TCAs is 100-260 ng/ml and toxicity is seen with levels of more than 300 ng/ml. Serious symptoms are associated with levels >1000 ng/ml.⁷

Our patient had ingested 20 mg/kg of amitriptyline and the blood level at 3 hours post-ingestion correlated with severe intoxication. Although he presented in coma, he did not develop seizures or respiratory depression. Waxing and waning of sensorium, characteristic of TCA poisoning was noted in our patient. Despite the high blood levels of amitriptyline, the QRS duration was normal. Although the QTc was prolonged, he did not exhibit any dangerous cardiac arrhythmias. Therefore, ECG could be a better tool to predict toxicity.^{4,9} Management of TCA poisoning is largely symptomatic and supportive. Patients require monitoring and stabilisation of vital signs and cardiac rhythm, with serial ECGs until the mental status is normal and the ECG remains normal for 24 hours. Emesis is contraindicated for fear of rapid neurologic, hemodynamic and respiratory deterioration. Gastric lavage followed by instillation of activated charcoal (30 g charcoal in 240 ml water - dose 25-50 gm in children $>$ one year old and one gm/kg in infants) is preferred. Follow up doses are also useful in view of the enterohepatic recirculation¹¹ and drug induced delayed gastric emptying. Alkaline diuresis enhances urinary elimination.¹² Intravenous naloxone and oral thiamine may be useful in patients with loss of consciousness. Ventricular tachycardia may require intravenous lidocaine, bretylium, phenytoin or magnesium sulfate.¹³ Quinidine and procainamide are contraindicated. Seizures must be controlled with diazepam and if resistant, with midazolam infusion or intravenous phenytoin. Hypotension is managed initially with boluses of saline infusion and may require inotropes. Intra-aortic balloons, hemoperfusion and extracorporeal membrane oxygenation have also been used successfully in patients with severe toxicity.¹⁴ Our child received quick gastric decontamination with activated charcoal which was repeated after 6 hours. Prompt and repeated use of gastric lavage and activated charcoal could have helped our patient's prompt recovery without any serious complication. Parental counselling and public education help to reduce accidental poisoning. High-risk substances such as antidepressants, hydrocarbons, iron, sedatives/hypnotics and anti-arrhythmic drugs at home should have child-safe caps and kept in their original containers, and stored in locked places where children cannot access. Old medications after use are to be discarded in safe places. Legislative measures also have their role.^{15,16}

In conclusion, we presented a 2-year old boy with accidental ingestion of a TCA, amitriptyline, who presented in coma. Despite high serum levels of TCA, he did not develop any of the life-threatening

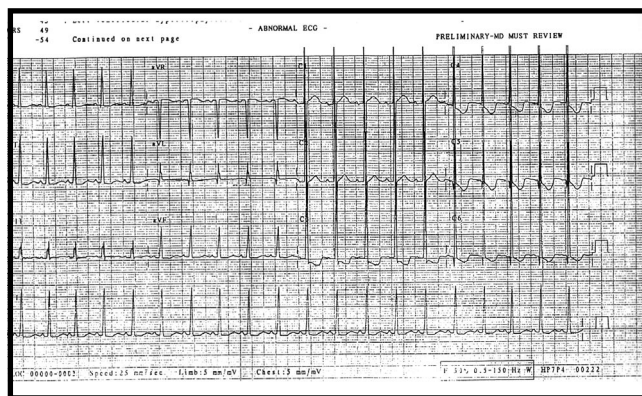


Figure 1 - Twelve lead electrocardiogram in a 2-year-old boy with accidental ingestion of amitriptyline showing sinus tachycardia, normal QRS duration (0.09 second), prolonged QTc interval (0.52 second), and T-wave inversion in leads C3 to C6.

complications. The clinical manifestations and management of this poisoning are outlined.

References

1. Laura PJ, Gregory LK. Cyclic antidepressant toxicity in children and adolescents. *J Clin Pharmacol* 1995; 35: 343-350.
2. Brown TC, Dwyer ME, Stocks JG. Antidepressant overdose in children. A new menace. *Med J Aust* 1991; 2: 848-857.
3. Noble J, Mathew H. Acute poisoning by tricyclic antidepressants: clinical features and management of 100 patients. *Clin Toxicol* 1969; 2: 403-421.
4. James LP, Kearns GL. Tricyclic antidepressant toxicity in children and adolescents. *J Clin Pharmacol* 1995; 35: 343-350.
5. Poisoning cases reported at SQUH over 1998. *Pharmacy Bulletin* 1999; 5: 4-5.
6. Poisoning cases reported at SQUH over 1999. *Pharmacy Bulletin* 2000; 6: 6-7.
7. Biggs JT, Spiker DG, Petit JM, Ziegler VE. Tricyclic antidepressant overdose: Incidence of symptoms. *JAMA* 1997; 238: 135-138.
8. Barnes RJ, Kong SM, Wu Rwy. Electrocardiographic changes in amitriptyline poisoning. *Brit Med J* 1968; 3: 222-223.
9. Caravati EM. The electrocardiogram as a diagnostic discriminator for acute tricyclic antidepressant poisoning. *Clin Toxicol* 1999; 37: 113-115.
10. Lavoie FW, Ganset GG, Weiss RF. Value of ECG findings and plasma drug levels in cyclic antidepressant overdose. *Ann Emerg Med* 1990; 19: 666-670.
11. Hulten BA, Adams R, Askenasi R. Activated charcoal in tricyclic antidepressant poisoning. *Hum Toxicol* 1988; 7: 307-310.
12. Mackway-Jones K. Alkalinisation in the management of tricyclic antidepressant overdose. *J Accid Emerg Med* 1999; 16: 139-140.
13. Knudsen K, Abrahamsson J. Magnesium sulphate in the treatment of ventricular fibrillation in amitriptyline poisoning. *Eur Heart J* 1997; 18: 881-882.
14. William JM, Hollingshed MJ, Vasilakis A. Extracorporeal circulation in the management of severe tricyclic antidepressant overdose. *Am J Emerg Med* 1994; 12: 456-458.
15. Temple AR. Poison prevention education. *Pediatrics* 1984; 74: 964-969.
16. Rodgers GB. The safety effects of child resistant packing for oral prescription drugs; two decade of experience. *JAMA* 1996; 275: 1661-1665.