

# Pacinian neuroma

*Sarah Kuruvila, MBBS, MD, Kukuvaayil L. Devi, MBBS, MD, Gopal Malhotra, MBBS, MCh, Chona Thomas, MBBS, FRCS.*

---

## ABSTRACT

Neural tumors composed of Pacinian corpuscles are rare and have only occasionally been reported in the literature. All such lesions, which have been reported to date, have been benign. One such lesion described here presented as a painful lesion on the right hand in a 17-year-old Omani female. There was history of trap door injury 7 years back involving the wrist, thumb and index finger. The patient gradually developed multiple bosselated nodules near the first web space with gradually increasing pain. This case is being reported for the first time in the Sultanate of Oman. We herein report this case due to its rarity.

Neurosciences 2003; Vol. 8 (1): 53-54

---

Pacinian corpuscles are specialized nerve endings with a lamellated structure that are regarded as pressure receptors and are thought to play a role in vibration sense. These structures are widely distributed anatomically, notably around osteo articular structures, tendons and the external genitalia. However, these are most heavily concentrated in the deep dermis and the subcutaneous tissues of the flexor aspect of the digits, palms and soles. Neural tumors either composed solely of Pacinian corpuscles, or showing only focal Pacinian differentiation are rare and only a few cases have been documented in the literature.<sup>1</sup> Pacinian neuroma refers to localized hyperplasia of Pacinian corpuscles occurring following trauma and commonly produces pain.<sup>2</sup> Typically it develops on the digits where it produces a localized mass attached to the nerve by a slender stalk, or as a nodule beneath the epineurium.

**Case Report.** A 17-year-old Omani female presented with multiple bosselated nodules on the right hand near the first web space with a history of gradually increasing pain of 7 years duration (**Figure 1**). There was a history of trap door injury approximately 7 years back involving the wrist, thumb and index finger of the right hand. On examination, the swellings were bluish and compressible. The median nerve was found to be

thickened for a length of about 5 cm at the distal forearm. The nerve proximal to the swelling was normal. The digital nerve of the thumb was also thickened. There was no evidence of neurofibromatosis. Carpel tunnel decompression was carried out and a biopsy was taken from the nodules in the web space. Histologically, the subcutaneous tissue showed an increase in the number of Pacinian corpuscles of varying sizes. The intervening stroma was composed of fibroadipose tissue. Small-thickened nerve fibers were seen scattered in between. There was no evidence of any inflammation. A diagnosis of Pacinian neuroma was made.

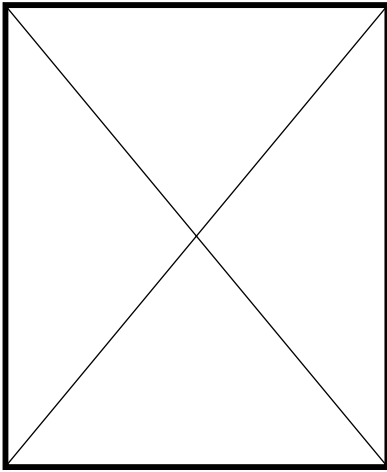
**Discussion.** The occurrence of hyperplastic Pacinian corpuscles in the hand is rare. These usually occur following trauma and commonly produce pain. The major lesions are of 2 types: (1) fibrosis in and around the nerve (2) reactive hyperplasia of the nerve support elements, special end organs, Pacinian corpuscles and even of the nerve fibers themselves. Collections of Pacinian corpuscles, when present, do not form discrete masses. They are usually non encapsulated with a mild degree of fibrosis around the capsule of individual corpuscles.<sup>1</sup> Unusually prominent

---

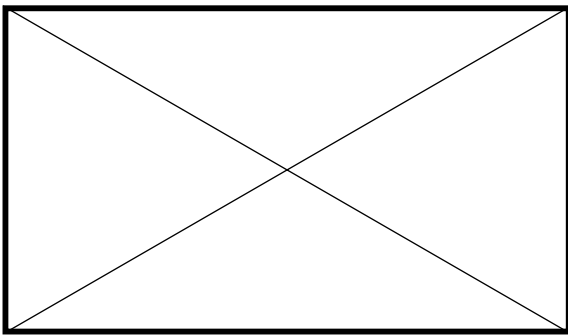
From the Department of Histopathology (Kuruvila), The Royal Hospital, Departments of Histopathology (Devi) and Plastic Surgery (Malhotra, Thomas), Khoula Hospital, Muscat, *Sultanate of Oman*.

Received 15th July, 2002. Accepted for publication in final form 10th September, 2002.

Address correspondence and reprint request to: Dr. S. Kuruvila, Department of Histopathology, The Royal Hospital, PO Box. 1331, Seeb 111, *Sultanate of Oman*. Tel. +968 592888 ext. 2731. Fax. +968 590298. E-mail: alexp@omantel.net.om



**Figure 1** • A 17-year-old Omani female with multiple bosselated nodules on the right hand and near the first web space.



**Figure 2** • Histology showing enlarged Pacinian corpuscles embedded in a fibroadipose tissue stroma. (Hematoxylin and eosin stain).

nerve fibers are seen coursing between these aggregates of Pacinian corpuscles. All these features were present in our case. The corpuscles were large, with normal number of lamellae (normal range - 13-15 lamellae) (**Figure 2**). The pathogenesis remains a matter of speculation, but it seems possible that trauma, either to the digital nerve or to pre-existent Pacinian corpuscles may lead to the growth of further newer Pacinian corpuscles either by budding or by stimulated differentiation of specialized terminal nerve fibers. Some of these may be newly formed, in response to the injury, which could explain the apparent increase in adjacent small nerve fibers seen in this case.

In our case, there was definite history of trap door injury 7 years back. Treatment is best provided by awareness of risk elements embodied in many personal and professional devices and avoiding risk activities and techniques. These risk activities, especially repetitive risk activities are present in all parts of our society including home, occupational, vocational and medical situations. Surgery is best avoided. In this case, no further surgery was carried out, and the patient is doing well.

## References

1. Fletcher CDM, Theaker JM. Digital Pacinian Neuroma: a distinctive hyperplastic lesion. *Histopathology* 1989; 15: 249-256.
2. Enzinger FM, Weiss SW. Benign tumours of peripheral nerves. In: *Soft Tissue Tumours*. 3rd ed. St Louis (MO): CV Mosby; 1995. p. 821-885.