

Erratum

In manuscript "Traumatic fat embolism syndrome" Neurosciences 2003; Vol. 8 (1): 60-64,
Figure 1 should have appeared as follows:

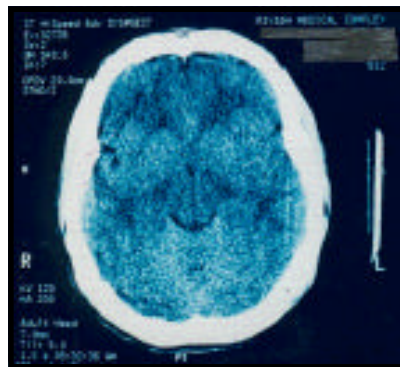


Figure 1 - Computed tomography scan showing mild cerebral edema.