

Magnetic resonance imaging of normal lumbar intervertebral foraminal height

Maher T. Al-Hadidi, MD, PhD, Jamal H. Abu-Ghaida, MD, PhD, Darwish H. Badran, MD, PhD, Azmy M. Al-Hadidi, MD, FRCR, Hassan N. Ramadan, MD, PhD, Diana F. Massad, MD, MPH.

ABSTRACT

Objective: To study the pattern and changes of lumbar intervertebral foraminal heights in an asymptomatic Jordanian sample relative to age, sex, level, and correlate values with midpoint vertebral and disc heights.

Methods: One hundred and fifty-three patients (87 male and 66 female) were selected during the study period. The study was carried out at the Jordan University Hospital, Amman, Jordan from June 1999 to June 2000. Parasagittal magnetic resonance images were used to measure intervertebral foraminal heights at all lumbar levels. Values were statistically analyzed and the significance of differences in the means of foraminal heights at different levels in every age group and among age groups was determined. Foraminal height indices and correlation coefficients with midpoint vertebral and disc heights were calculated.

Results: The study revealed that the mean foraminal height measured is 20.9 mm \pm 1.7 with a range of 17.1-24 mm. Foraminal heights increased significantly in a craniocaudal pattern reaching a maximum at lumbar (L)2/3 in females and

at L3/4 in males followed by continuous significant decrease reaching their minimum at L5/sacral (S) 1. In relation to age, foraminal heights decreased significantly in females reaching their minimum in the 7th decade. In males, foraminal heights at L3/4 until L5/S1 increased significantly reaching their maximum in the 5th decade followed by significant decrease reaching their minimum in the 7th decade. Foraminal height indices remained relatively constant. A fair degree of correlation of foraminal heights with intervertebral disc heights and vertebral body heights was evident.

Conclusions: Foraminal heights show different level- and age-dependent characteristic pattern of change between asymptomatic males and females. Changes of foraminal heights seem to directly reflect changes of vertebral body heights. These changes are considered normal age-dependent changes, and are discussed under consideration of adaptation to physical activity and changing hormonal levels.

Neurosciences 2003; Vol. 8 (3): 165-170

The lumbar nerve root canal (LNRC) bridges between the intra spinal space and the extra spinal space. For descriptive and practical purposes this region has been subdivided into 3 zones: the entrance zone, the midzone, and the exit zone. The exit zone describes the area surrounding the intervertebral foramen (IVFo). It is bordered anteriorly by the intervertebral disc (IVD) and posteriorly by facet joint one level below the entrance zone.^{1,2} The exiting nerve root along with the dorsal root ganglion lie in the subpedicular notch. The descriptive anatomy of IVFo is important because variations in

shape and size are often associated with nerve root compression. Foraminal size varies, even at individual levels.³⁻⁵ Wide variations of normal lumbar foraminal height (FH) have been reported.⁶⁻⁸ From a pathophysiological point of view, the development of static foraminal stenosis is related to lumbar spondylosis.⁵ The loss of disc height (DH) secondary to desiccation and degeneration allows the superior articular process of the inferior vertebra to sublunate anteriorly and superiorly diminishing the foraminal area. The alterations of biomechanical forces contribute to

From the Department of Anatomy and Histology (M. Al-Hadidi, Abu-Ghaida, Badran, Ramadan), Division of Radiology (A. Al-Hadidi), Jordan University Hospital and Department of Community Medicine (Massad), Faculty of Medicine, University of Jordan, Amman, Jordan.

Received 4th August 2002. Accepted for publication in final form 28th October 2002.

Address correspondence and reprint request to: Dr. Maher T. Al-Hadidi, Department of Anatomy and Histology, Faculty of Medicine, University of Jordan, Amman 11942, Jordan. Tel. +962 (6) 5355000 Ext. 2384. Fax. +962 (6) 5356746/5355522/5355511. E-mail: mthadid@ju.edu.jo

development of hypertrophic ligamentum flavum and bony spurs anterior to the facet joint, thus adding to anteroposterior stenosis.⁸ Craniocaudal stenosis develops after posterolateral osteophytes protrude into the foramen along with a laterally bulging annulus fibrosus or herniated disc. Anteroposterior and craniocaudal stenosis lead to circumferential stenosis.⁵ Correlation has been made between posterior DH, FH, and incidence of foraminal nerve root compression.⁸ In relative loss of posterior DH the pedicles would come closer followed by posterior disc bulging and the ligamentum flavum would be pushed anteriorly by the superior articular process of the underlying vertebra resulting in stenosis of the IVFo.⁹ On the other hand, increasing the DH through anterior interbody distraction in degenerative lumbar spine increases significantly IVFo volume and area.^{9,10} The incidence of disc degeneration increases in old age. However, disc degeneration is not synonymous with disc thinning.⁵ Rational of this study is to provide anatomic baseline data related to lumbar IVFo dimensions based on parasagittal magnetic resonance images (MRI) of selected asymptomatic Jordanians. Foraminal heights are studied in relation to vertebral level, age, and gender. Measurements are correlated with midpoint DH, and midpoint vertebral heights (VH). This data should serve as reference to which degenerative or pathologic changes may be compared.

Methods. Patients. A total of 153 asymptomatic patients (87 males, age range 20-65 years; mean 43 ± 21.1 , and 66 females, age range 22-68 years; mean 47 ± 13.7), were selected during the study period. Asymptomatic patients were selected from patients referred to the MRI unit in Jordan University Hospital for abdominopelvic problems during a one year period, June 1999 through to June 2000. Patients with history of spine problems or those who showed spine degenerative changes were excluded. The patients were divided into 5 age groups (**Table 1**).

Technique. Magnetic resonance imaging was performed on a magnetic vision plus scanner with a 1.5-tesla magnet (Siemens, Erlangen, Germany) using spine array coil. Sagittal T1-weighted single spin echo images with a repetition time (TR) of 500 milliseconds and echo time (TE) of 15 milliseconds with 3 acquisitions and 2 saturations of the lumbosacral spine showing L1 to S1, comprising 5 consecutive images for each patient. Images were taken using 4 mm slice thickness and 30cm field of view with a 0.10 distant factor. The axial images were parallel to the axial plane of the IVFo of the LNRC. The best most medial parasagittal image that showed the borders of the IVFo precisely, upper surface and lower surface of the 2 adjacent pedicles were used for the measurements to the best advantage was chosen at each level. Data was acquired with a 150 x 300 matrix and displayed on the Sun ultra spanner computer system in a 1024 x 768 matrix.

Measurements. For the sake of consistency all measurements were taken by one observer. Our consultant radiologist did all the measurements performed in the study directly on the lumbar images. On the best image, landmarks of the IVFo were digitized by electronic cursor and were labeled. The FH was measured between the highest and lowest points of the IVFo between the inferior surface of the upper pedicle (P1) and superior surface of the lower pedicle (P2) at all vertebral levels between L1 and S1 (**Figure 1**). Midpoint DH and midpoint VH were measured as previously described.¹¹ All measurements were automatically calculated and displayed on the computer screen then labeled on the magnetic resonance films. Values were recorded to the nearest 0.1 mm.

Statistical analysis. The means and standard deviations of the FH were calculated for all lumbar levels in males and females among each age group. The mean percent changes in FH were calculated. Student paired t-tests and ANOVA tests were used to detect significant changes ($p = <0.05$) in FH between age groups in both genders. Correlation tests between the FH, midpoint DH, and midpoint VH were also performed and correlation coefficient (r) was calculated. All data was analyzed by using an IBM compatible personal computer.

Results. The FH for males and females for each lumbar level and in all 5 age groups are given in (**Table 1 and Figure 2**). The mean FH measured was $20.9\text{mm} \pm 1.7$ with a range of 17.1 - 24 mm ($20.8\text{ mm} \pm 1.4$ with a range of 17.1 - 23 mm in males and $21.1\text{ mm} \pm 1.9$ with a range of 17.8 - 24 mm in females). The statistical differences in the FH means in males and females were insignificant.

The correlation of foraminal height to vertebral level showed an obvious craniocaudal sex-independent pattern of increase of FH is observed at L2/3 compared to L1/2 in all age groups averaging 6.5% in males and 3.8% in females. At L3/4 no increase was evident in females (except in the 5th decade). In males, however, an increase at L3/4 averaging 7.8% as compared to L1/2 was seen. Maximum FH values were thus reached at L2/3 in females and at L3/4 in males. Caudal to L3/4 FH showed a continuous sex-independent decrease with a clear age-dependent pattern. There, the most obvious and statistically significant decrease was seen in the third decade. This decrease becomes gradually less obvious and statistically insignificant as age progresses beyond the 3rd decade. Minimum FH were measured at L5/S1 where the most obvious decrease was evident averaging 11.3% in males and 9.3% in females as compared to maximum values at L3/4 and L2/3.

When the foraminal height interrelated to age in females, it revealed an age-dependent continuous decrease of FH at L1/2 through L4/5 is evident where minimum values were reached in the 7th decade. At the L5/S1 level FH values showed an initial increase

Table 1 - Means and standard deviations for lumbar intervertebral foraminal heights (FH) with age and sex.

Level	Age groups (years)					ANOVA p-value
	20-29.9	30-39.9	40-49.9	50-59.9	60-69.9	
L1/2	M 19.4 ± 1.4 n=12* F 24 ± 0 n=6*	20.4 ± 2.1 n=21* 22.8 ± 1.2 n=15*	20.6 ± 2.5 n=30* 20.2 ± 3.2 n=18*	20.2 ± 1.2 n=12* 20 ± 1.5 n=12*	20.7 ± 2.4 n=12* 18.8 ± 3.5 n=15*	M 0.48817 F 0.000
L2/3	M 21.5 ± 1.6 F 24 ± 1	21.1 ± 1.9 23.4 ± 2.7	22.1 ± 1.5 22 ± 1	21.7 ± 2.7 21.5 ± 1.2	21.5 ± 2.7 18.8 ± 2.6	M 0.6 F 0.000
L3/4	M 22.5 ± 0.9 F 23 ± 0	20.8 ± 1.8 22.4 ± 2.1	23 ± 1.1 23.4 ± 2.7	21.8 ± 2.9 21.5 ± 1.6	21 ± 3.7 18.8 ± 2.3	M 0.0036 F 0.000
L4/5	M 21.5 ± 1.9 F 24 ± 2.2	19.6 ± 3.5 20.2 ± 4.4	22.7 ± 1.1 20 ± 3.4	21.5 ± 1.9 20.4 ± 1.8	19.1 ± 4.4 19.6 ± 2.1	M 0.000 F 0.065
L5/S1	M 18 ± 3.4 F 20 ± 2.2	17.1 ± 3.6 22 ± 3.5	21.3 ± 2.8 19.2 ± 1.9	20.7 ± 2.4 19.9 ± 2.7	19.7 ± 3 17.8 ± 4.5	M 0.000 F 0.0147
ANOVA p-value	M 0.000 F 0.000	M 0.000 F 0.05614	M 0.000 F 0.000	M 0.16816 F 0.07126	M 0.40297 F 0.65051	

L - lumbar, S - sacral, M - male, F - female, ANOVA - analysis of variance, *number in each age group

Table 2 - Relative foraminal height indices in males and females.

Vertebral level	Parameters	Age Group (years) and sex									
		20-29.9		30-39.9		40-49.9		50-59.9		60-69.9	
		Male	Female	Male	Female	Male	Female	Male	Female	Male	Female
L1	xFH	19.4	24	20.4	22.8	20.6	20.2	20.2	20	20.7	18.8
	xDH	8.5	9.5	10.1	10.5	9.8	10.3	10	9.8	8.8	9
	xVH	27	24	23.6	23	26.4	24.9	25.8	24.5	27	22.8
	FH/DH	2.3	2.5	2	2.2	2.1	2	2	2	2.4	2.1
	FH/VH	0.7	1	0.9	1	0.8	0.8	0.8	0.8	0.8	0.8
L2	xFH	21.5	24	21.5	23.4	22	22	21.7	21.5	21.5	18.8
	xDH	9.8	11	11.3	12.2	10.7	11.9	11.8	11.8	11.5	10.4
	xVH	25.9	25.7	24.9	23.8	27.3	25	27.6	25.4	27.4	24
	FH/DH	2.2	2.2	1.9	1.9	2.1	1.8	1.8	1.8	1.9	1.8
	FH/VH	0.8	0.9	0.9	1	0.8	0.9	0.8	0.8	0.8	0.8
L3	xFH	22.5	23	20.8	22.4	23	23.4	21.8	21.5	21	18.8
	xDH	11.3	12	13.1	12.6	12.4	12.8	13.3	12.3	11.8	11.8
	xVH	29	25.7	25.4	27.7	27.5	24.6	28	24.8	27	25.2
	FH/DH	2	1.9	1.6	1.8	1.9	1.8	1.6	1.7	1.8	1.6
	FH/VH	0.8	0.9	0.8	0.8	0.8	1	0.8	0.9	0.8	0.7
L4	xFH	21.5	24	19.6	20.2	22.7	20	21.5	20.4	19.1	19.6
	xDH	11.5	12	11.4	12.6	12.2	12.7	13.8	11.8	11.8	11.6
	xVH	27	26	24.9	23.7	24.1	24.1	27.4	24.7	27.4	24.5
	FH/DH	1.9	2	1.7	1.6	1.9	1.6	1.6	1.7	1.6	1.7
	FH/VH	0.8	0.9	0.8	0.9	0.9	0.8	0.8	0.8	0.7	0.8
L5	xFH	18	20	17.1	22	21.3	19.2	20.7	19.9	19.7	17.8
	xDH	9	11.5	12.1	12	12.7	11.2	12	12.5	13.3	13.2
	xVH	26.4	27.5	24.9	23.1	25.2	24	24	23.5	24.9	22.4
	FH/DH	2	1.7	1.4	1.8	1.7	1.7	1.7	1.6	1.5	1.3
	FH/VH	0.7	0.7	0.7	1	0.8	0.8	0.9	0.8	0.8	0.8

L - lumbar, xFH - mean of foraminal height, xDH - mean of midpoint disc height, xVH - mean of midpoint vertebral height

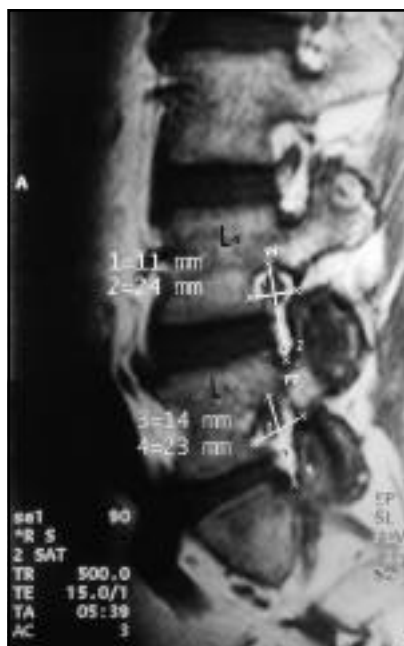

Figure 1 - Sagittal MR image of the lumbar spine, demonstrates positions of markers for measuring the foramina heights (FH) between L4/L5.

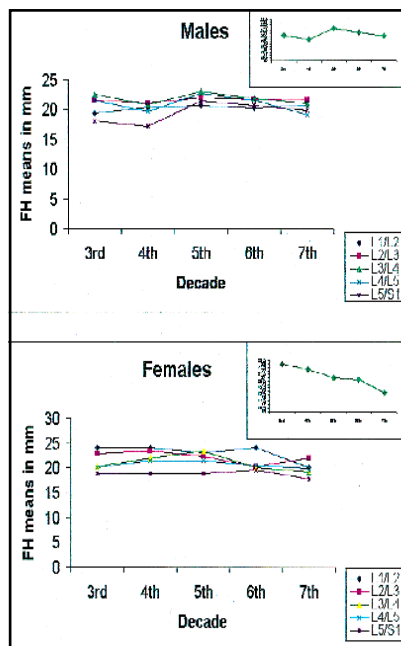


Figure 2 - Foramina height (FH) in male and females by age. Inset shows general pattern: the mean of each decade is plotted.

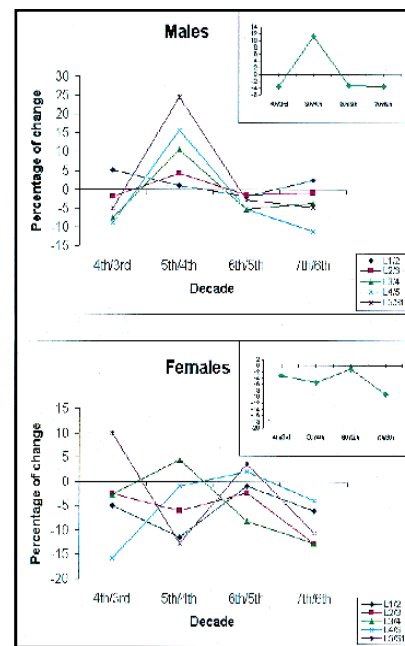


Figure 3 - Percentage of relative change of foramina height (FH) in males and females. Inset shows general pattern of change: the mean of changes in each decade is plotted.

reaching their maximum in the 4th decade followed by a continuous decrease in the 7th decade. All described changes were statistically significant except at L4/5.

Whereas in males, the FH at L1/2 and L2/3 follow an insignificant equivocal alternating increase/decrease pattern through the successive examined decades. At L3/4, L4/5, and L5/S1 showed an obvious initial significant statistical increase evident between the 3rd and 5th decades. A mild but statistically significant decrease becomes evident between the 6th and 7th decades. The maximum values were reached in the 5th decade at all levels. The minimum values, on the other hand, were evident in the 7th decade at upper vertebral levels and between the 3rd and 4th decades at lower vertebral levels.

The foramina height/vertebral height index (FH/VH) showed a level-independent and age-independent constant FH/VH index (0.8 ± 0.1) in males and (0.9 ± 0.1) in females (Table 2). Furthermore, foramina height/intervertebral disc height index (FH/DH), revealed relatively constant FH/DH indices (1.9 ± 0.2) in males and (1.8 ± 0.2) in females. The index shows a craniocaudal decrease in each decade and a decreasing age-dependent pattern at each level (Table 2).

A fair degree of correlation between FH and DH and VH values was evident when correlation coefficients (r) were calculated where (r) = 0.3 in males and (r) = 0.4 in females (Table 2).

Discussion. The spatial relationship between the nerve root and the osseous and nonosseous elements of

the IVFo is clinically important.¹² The LNRC can be compromised by changes of the structures that constitute its anatomical boundaries.¹³⁻¹⁵ Although there is correlation between foramina nerve root compression and bony dimensions discernible on lateral radiographs,¹⁰ yet, plain radiologic measurements are misleading. This is due to angulations and superposition as the foramina change orientation from horizontal and lateral in upper lumbar spine to anterior and caudal in lower lumbar and sacral levels.^{1,3} Similarly, myelography has limited relevance for lateral spinal pathology. Computed tomography and MRI techniques are considered mainstays for evaluation and quantifying foramina dimensions. In this regard, MRI is preferred as it visualizes foramina along the whole length of lumbar spine associated with superior resolution of IVD and vertebral body.⁵

Most literature related on the IVFo is based on studies performed on cadavers^{3,4,8,16} or degenerative spine and symptomatic patients.^{17,18} Their results are conflicting and carry excessive individual variations.¹⁹ The present study has been designed to provide anatomical baseline information on normal lumbar IVFo, to which degenerative or pathologic changes may be compared.

The statistical analysis of our measurements showed that the mean of lumbar FH is $20.9 \text{ mm} \pm 1.7$ without significant male/female differences. This value confirms some already published figures; however, it lies higher than others.^{3,4,5,19} This discrepancy can be explained on the basis of the age range of the examined samples, which is represented by a gapless wide age range in both

genders with young, middle-aged, and elderly normal groups included. This becomes clear if the mean of age (43 years \pm 12.1) is considered. Normal middle age, especially in males, is associated with higher FH values. If only older aged females are considered the means would lie significantly lower (18.8 mm). Our results also confirm already published data related to level-dependent differences in lumbar FH.^{3,16,19} Similar FH are shared at L2/3, L3/4 levels, which are equal or higher than L4/5, while FH is least at L5/S1 level. Following the change in FH through successive decades (**Figure 3**), it becomes evident that the continuous decrease, exhibits 2 peaks in females, an early peak between the 4th and 5th decades averaging 10% and late peak between the 6th and 7th decades averaging 9.1%. The early peak of decrease is more obvious in transitional levels namely, L1/2 and L4/5.

In males, an obvious increase averaging (17%) between the 4th and 5th decades is evident. This change follows a craniocaudal pattern which starts with 1.1% at L1/2 and increases steadily to 4.3% at L2/3, 10.6% at L3/4, 15.8% at L4/5 to finally reach its maximum 24.6% at L5/S1. A mild decrease of 3.3% is evident in late decades between the 5th and 6th which, relatively unchanged (5.2%) remains between the 6th and 7th decades. The 2-peak pattern of decrease in females coincides with premenopausal and late menopausal phases. Foraminal height has been already shown to decrease significantly in females in the 7th decade.²⁰ Hormonal imbalance in addition to nutritional factors and sedentary life with resulting osteoporotic changes may account for vertebral body changes. These changes include loss of perpendicular bone trabeculae and increased endplate concavity resulting in loss of FH especially at transitional vertebral levels. As for males, the decrease in FH is delayed to 6th decade, which may be attributed to relative physical inactivity at this age. Early decades are characterized by increase of FH, which shows a strict progressive craniocaudal pattern conforming to increased craniocaudal vertebral load.²¹

Correlation has been made between posterior DH and FH.^{3,8,9} Postural, adaptive or degenerative changes of disc architecture would result in decreased dimensions of the IVFo.^{3,4,5,9,22} Even subtle degenerative alterations such as traction spurs and bulging annuli may result in foraminal stenosis which puts the nerve root at risk for compression.^{3,4,9} Indeed, in a previous paper¹¹ we have already shown that the midpoint DH increases with age in normal population reaching its maximum in the 5th and 6th decades. We were also able to demonstrate that although the midpoint DH reaches the minimum in the 7th decade, however, in absolute figures this minimum remains higher than that in the 3rd decade. In this regard, we share the view that the true average DH increases with age, as the disc sinks into the vertebra.²² As a result of osteoporosis the vertebral endplates collapse and disc convexity increases.²² The regular and direct parallel pattern of changes of FH and VH is supported by constant FH/VH index. However, the age-

dependent and level-dependent decreasing pattern of FH/DH index, similar to already published data,¹⁶ reflects a more differential and indirect relationship between these 2 parameters.

In conclusion, it should be stressed, that the normal age changes, which have been illustrated in our present study, could make subjects more vulnerable to nerve root compression, as previously suggested,¹⁶ however, the relevance of FH to nerve root compression should be critically evaluated. The nerve root is more likely to be trapped in tear-shaped than oval foramina although both might share the same height.³ Age-related changes of other foraminal dimensions including foraminal width in normal subjects will be the central theme of part II of this work.

Acknowledgment. The authors wish to express their sincere appreciation to Mr. Abdullah Hamdan, MRI Senior Operator, Jordan University Hospital, Amman, Jordan for his technical artistic work.

References

1. Bose K, Balasubramaniam P. Nerve root canals of the lumbar spine. *Spine* 1984; 9: 16-18.
2. Lee CL, Rauschnig W, Glenn W. Lateral lumbar spinal canal stenosis: Classification, pathologic anatomy and surgical decompression. *Spine* 1988; 13: 313-320.
3. Stephens MM, Evans JH, O'Brien JP. Lumbar intervertebral foramina: An in vitro study of their shape in relation to intervertebral disc pathology. *Spine* 1991; 16: 525-529.
4. Infusa A, An HS, Lim TH, Hasegawa T, Haughton VM, Nowicki BH. *Spine* 1996; 21: 2412-2420.
5. Jenis LG, An HS. Spine update: Lumbar foraminal stenosis. *Spine* 2000; 25: 389-394.
6. Putti V. New conceptions in the pathogenesis of sciatic pain. *Lancet* 1927; 2: 52-60.
7. Magnusson PB. Differential diagnosis of causes of pain in the lower back accompanied by sciatic pain. *Ann Surg* 1944; 119: 878-901.
8. Hasegawa T, An HS, Haughton VM, Nowicki BH. Lumbar foraminal stenosis: Critical heights of the intervertebral discs and foramina. A cryomicrotome study in cadavers. *J Bone Joint Surg [Am]* 1995; 77: 32-38.
9. Luoma K, Riihimaki H, Luukkonen R, Raininko R, Viikari-Juntura E, Lamminen A. Low back pain in relation to lumbar disc degeneration. *Spine* 2000; 25: 487-492.
10. Infusa A, An HS, Glover JM, McGrady L, Lim T, Riley LH. The ideal amount of lumbar foraminal distraction for pedicle screw instrumentation. *Spine* 1996; 21: 2218-2223.
11. AL-Hadidi MT, Badran DH, AL-Hadidi AM, Abu-Ghaida JH. Magnetic resonance imaging of normal intervertebral discs. *Saudi Med J* 2001; 22: 1013-1018.
12. Hasue M, Kunogi J, Konno S, Kikucji S. Classification by position of dorsal root ganglia in the lumbosacral region. *Spine* 1989; 14: 1261-1264.
13. Farfan HF. Mechanical disorders of the low back pain. Philadelphia (PA): Lea and Febiger; 1973.
14. Young-Hing MD, Reily J, Kirkadly-Willis WH. The ligamentum flavum. *Spine* 1976; 1: 226-234.
15. Taylor JR, Twomey LT. Age changes in lumbar zygapophyseal joints: Observations on structure and function. *Spine* 1986; 11: 739-745.
16. Twomey L, Taylor J. Age changes in the lumbar spinal and intervertebral canals. *Paraplegia* 1988; 26: 238-249.
17. Postacchini F. Surgical management of lumbar spinal stenosis. *Spine* 1999; 24: 1043-1047.
18. Giles LG. Mechanisms of neurovascular compression within the spinal and intervertebral canals. *J Manipulative Physiol Ther* 2000; 23: 107-111.

19. Hasegawa T, Mikawa Y, Watanabe R, An HS. Morphometric analysis of the lumbosacral nerve root and dorsal root ganglia by magnetic resonance imaging. *Spine* 1996; 21: 1005-1009.
20. Nathan H. Osteophytes of the vertebral column. *J Bone Joint Surg [Am]* 1962; 44: 243-268.
21. Eisenstein S. The morphometry and pathological anatomy of the lumbar spine in South African Negroes and Caucasoid with specific reference to spinal stenosis. *J Bone Joint Surg [Br]* 1977; 59: 173-180.
22. Twomey LT, Taylor JR. Age changes in lumbar intervertebral discs. *Acta Orthopédica Scandinavica* 1985; 56: 496-499.

Related Abstract

Source: Saudi MedBase



Saudi MedBase CD-ROM contains all medical literature published in all medical journals in the Kingdom of Saudi Arabia. This is in electronic format with a massive database file containing useful medical facts that can be used for reference. Saudi Medbase is a prime selection of abstracts that are useful in clinical practice and in writing papers for publication.

Search Word: **spinal, injury**

Authors: Fatma A. Al-Mulhim, Ezz-Eldin M. Ibrahim
Institute: King Faisal University, Dammam, Kingdom of Saudi Arabia
Title: Magnetic resonance imaging of the spine: an initial experience
Source: Annals of Saudi Medicine 1994; 4: 333-337

Abstract

Retrospective analysis was carried out for 477 magnetic resonance imaging (MRI) studies of the spine. The overall mean age \pm SD of the entire series was 38.7 ± 12.9 years. Degenerative spinal lesions and prolapsed intervertebral disks were detected in 62% and 73% of all the studies and of those which showed spinal abnormalities respectively. Postoperative granulation tissue was the third most common abnormality detected (12%). MRI was superior to computed tomography (CT) and CT myelograms in the diagnosis of disk prolapse (97% versus 66%), degenerative disease of the spine (94% versus 48%), and postsurgical granulation tissue (100% versus 6%). Comparing the numbers of CT and CT myelograms requested in the year prior to the installation of the MRI to the numbers requested during the year where the MRI was functioning did not show any change in the frequency of ordering CT studies. We conclude that our hospital-based series has shown an interesting pattern for spinal disorders. The first year experience of the utilization of MRI in various spinal diseases has been satisfactory with prevailing diagnostic superiority for that modality.