

Radiographic abnormalities in acute lymphoblastic leukemia

Shiekh A. Aziz, MD, DM, Mushtaq Ahmed, MD,
Samoon Jeelani, MD, Abdul R. Lone, MD.

Radiologically detectable skeletal involvement is rare in adults with leukemia and among the characteristic features are diffuse demineralization, horizontal radiolucent bands in metaphysis of long bones, multiple small clearly defined radiolucent defects, periosteal reaction on long bones, fractures, metaphyseal or diaphyseal patches of moth-eaten or permeative bone destruction laminated new bone formation, osteolytic, osteoblastic lesions or a mixture of any other changes. Expressed in approximately 10% of adults with leukemia, skull lytic lesions are variedly nonspecific and may precede typical findings in peripheral blood. Herein, we report a young patient who has acute lymphoblastic leukemia (ALL) with predominant bone related complaints.

A 20-year-old male was admitted with chief complaints of easy fatigability, fever, headache and bone pain of one month's duration. Clinical examination revealed pallor, bilateral proptosis, and small nodes in right axilla and femoral region with marked bone tenderness. Systemic examination of chest, cardiovascular system and central nervous system were non-contributory. Per-abdominal examination revealed hepatomegaly and splenomegaly. Abnormal investigations carried out showed hemoglobin 7.8g, total white blood cell count 15.84, (neutrophils 18%, lymphocytes 33%, and blasts 49%) and platelets 126. Among the biochemical parameters lactic dehydrogenase was 635 U/L, urea 8.3 mg%, calcium 9mg%, alkaline phosphatase 3100 U/ml, chest x-ray, ECG and thyroid function tests were normal. Skull x-ray abnormalities are shown in **Figure 1**. Serum electrophoresis was normal (Immunoglobulin (Ig)M 998 mg/24 hours, IgA 138 mg/24 hours, IgM 97 mg/24 hours). Twenty-four-hour urinary vanillylmandelic acid levels measured 8.2 mg. Bone scan revealed abnormal intense theca uptake in skull in left parietal bone and 8th rib. Bone marrow biopsy revealed erythrocyte 3%, myelo 3% and blasts 92%. These blasts measured 14-16 microns in diameter, having fine chromatin, inconspicuous 1-2 prominent nucleoli, indented nucleoli and scanty cytoplasm. Immunocytochemistry of the bone marrow slides revealed PAS positivity. The patient was finally diagnosed as ALL-L2 morphology,

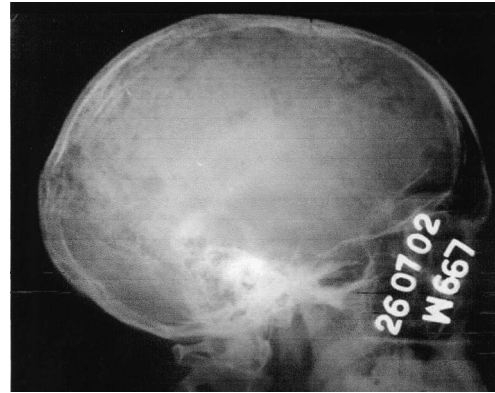


Figure 1 - Skull x-ray revealing small multiple punched out circumscribed well-define lytic lesions without any sclerosis.

having lytic lesion in the skull bones. He received induction and intensification and is planned for maintenance chemotherapy.

Unbalanced osteoclastic activity consequent to altered cytokine milieu, whether there is any prognostic implications in adult ALL with lytic lesions is unknown, nevertheless, rare atypical presentation and future studies would unveil these gaps in our understanding.

Received 29th October 2003. Accepted for publication in final form 8th March 2004.

From the Department of Medical Oncology, Sher-I-Kashmir Institute of Medical Sciences, Srinagar, Kashmir. Address correspondence and reprint requests to Dr. Sheikh A. Aziz, Additional Professor, Department of Medical Oncology, Sher-I-Kashmir Institute of Medical Sciences, Soura Post Bag No. 27, Srinagar 190011, Kashmir, India. Fax: +91 (194) 403470. E-mail: saejaz@vsnl.com

References

1. Du Boulay GH. Principles of x-ray diagnosis of skull. 2nd ed. London (UK): Butterworth-Heinemann; 1980. p. 63.
2. Grainger RG, Allison DJ. Diagnostic radiology, 2nd ed, Vol II. New York: Churchill Livingstone Publishers; 1992. p. 1562.
3. Brunner S, Gulbjerg CE, Iverson T. Skeletal lesions in leukemia in children. *Acta Radiol* 1958; 49: 419-424.
4. Moseley JE. The Skull. In: Newton TH, Potts DG editors. Haematologic disorders in Radiology of the skull and brain. St. Louis: CV Mosby Company; 1963.
5. Greenfield GB. Radiology of bone diseases. 3rd ed. Philadelphia: JB Lippincott Company; 1975. p. 454
6. Murry RP, Jacobson HG. The radiology of skeletal disorders - Exercise in diagnosis. 2nd ed. Vol II. Edinburgh, London & New York: Churchill Livingstone Publishers; 1977. p. 784.
7. Juhl JH, Crummy BA, Kuhlman JE. Paul & Juhl's Essentials of Radiologic Imaging. 6th ed. Philadelphia, New York; JB Lippincott Company; 1993.