

# Large deep venous anomaly presenting as a left frontal lesion

*Nabeel Al-Naghmouh, MD, Jehad Al-Watban, MD, Ahmed Alkhani, MD, FRCSC.*

---

## ABSTRACT

Venous angiomas, also known as deep vein anomalies (DVA), are one of the well-described brain vascular malformations. Frequently they are diagnosed as an incidental finding on neuroimaging (CT or MRI). A DVA may present as a single enhancing venous channel or as a large vascular abnormality illustrated on cerebral angiogram. Such a large DVA may mimic other intracranial lesions that mandate surgical intervention. We describe the radiological findings on CT, MRI, MRA and cerebral angiography of a 26-year-old male who presented with a few months' history of recurrent attacks of light-headedness, dizziness and slurring of speech that usually lasted for 2 minutes and resolved spontaneously. Cerebral angiography illustrated enlarged medullary veins draining into a central venous trunk then into the superior sagittal sinus resembling a caput medusa sign. Large DVAs may present radiologically as a brain lesion. Early recognition of these anomalies would avoid unnecessary or harmful intervention of this, otherwise, benign pathology.

**Neurosciences 2005; Vol. 10 (2): 177-179**

---

Vascular malformations have been classified (on the basis of their microscopic features) into 4 groups: venous malformation, cavernous angioma, capillary telangiectasia and arteriovenous malformation. Venous angiomas, also known as deep vein anomalies (DVA), account for 60% of all vascular malformations.<sup>1</sup> They are frequently diagnosed as incidental findings on neuroimaging (CT or MRI), either isolated or in coexistence with other anomalies such as cavernous angioma.<sup>2-4</sup> We are reporting a case of a large DVA that presented as a frontal mass for possible surgical intervention. An accurate radiological diagnosis of DVA is essential to prevent unnecessary and possible harmful interventions.

**Case Report.** A 26-year-old male, previously healthy, presented with a few months' history of recurrent attacks of light-headedness, dizziness, and slurring of speech that usually lasted for 2 minutes

and resolved spontaneously. It was not associated with any abnormal movements. Neurological exam revealed no neurological deficits. His blood work was within normal limits and interictal EEG showed no abnormal activities. A CT of the brain illustrated a left frontal small ill-defined enhancing lesion (**Figure 1**). The patient was referred based on the lesion to our institute for possible surgical intervention. An MRI and MRA illustrated a large left frontal venous trunk with no associated brain parenchymal changes (**Figure 2**). A 4 vessel cerebral angiography was carried out, and it illustrated normal arterial phase, no evidence of arterio-venous shunting and enlarged medullary veins draining into a central venous trunk. From the central venous trunk, these veins were draining into the superior sagittal sinus representing a caput medusa sign (**Figure 3**). The patient was started on anti seizure medications and was reported well 2 years after his presentation.

---

From the Division of Neurosurgery, Department of Neurosciences (Al-Naghmouh, Alkhani), and the Department of Radiology (Al-Watban), King Faisal Specialist Hospital and Research Center, Riyadh, *Kingdom of Saudi Arabia*.

Received 6th July 2004. Accepted for publication in final form 11th September 2004.

Address correspondence and reprint request to: Dr. Ahmed Alkhani, Consultant Neurosurgeon, Division of Neurosurgery, Department of Neurosciences, King Faisal Specialist Hospital and Research Centre, MBC 76, PO Box 3354, Riyadh 11211, *Kingdom of Saudi Arabia*. Tel. +966 (1) 4641212. Ext. 32772/32773 E-mail: alkhani@yahoo.com

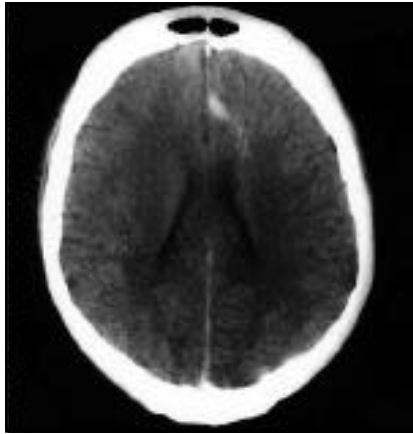


Figure 1 - Contrasted axial CT scan of the brain at the level of lateral ventricles showing an enhancing, ill-defined left medial frontal lesion with surrounding cortical changes.

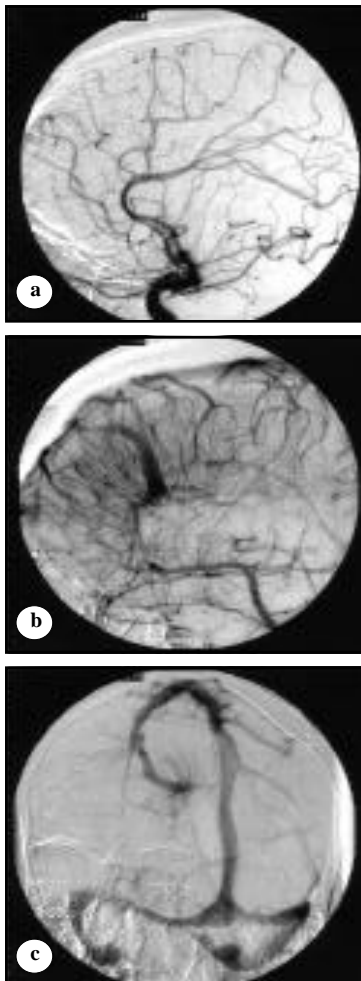


Figure 3 - Cerebral angiography showing **a)** Lateral arterial phase selected left internal carotid (IC) injection showing no radiological evidence of arterio-venous shunting. **b)** Lateral late venous phase from IC injection demonstrating the venous angioma with peculiar morphology. The venous draining is directed to cortical veins then to the sagittal sinus system. **c)** Oblique AP view of early venous phase nicely demonstrating the vascular angioma.

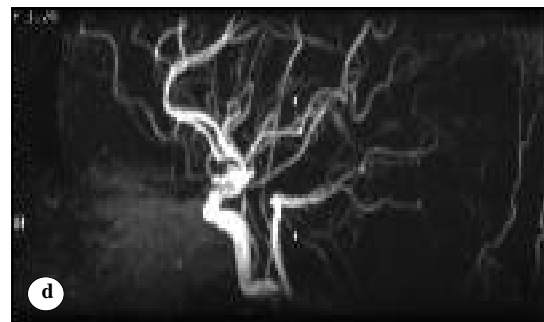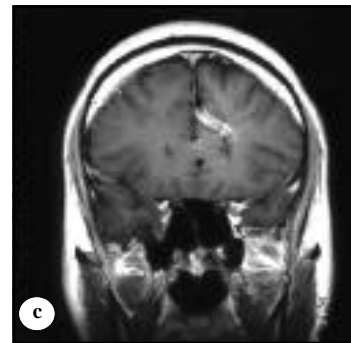
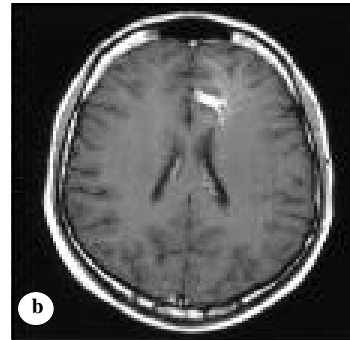
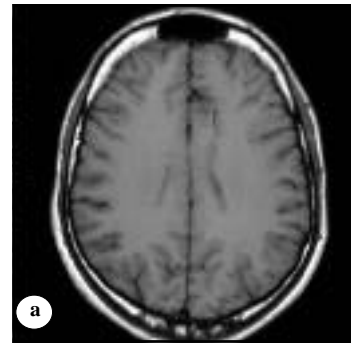


Figure 2 - Brain MRI showing **a)** Axial T1 MRI showing a streak-like structure with surrounding flow-void signals in the left medial frontal area. **b)** Axial T2 MRI after gadolinium injection illustrating the vascular anomalies with large (8mm) trunk and multiple small streams leading to it. **c)** Coronal T2 MRI with similar findings. **d)** MR angio with no vascular anomalies identified.

**DISCUSSION.** In 1887, Pfannenstiel<sup>5</sup> was the first to describe an intracranial vascular malformation composed entirely of veins. In 1963, Courville<sup>6</sup> described the morphological details of 22 small venous angioma found in autopsies. He confirmed their anomalous venous character and used the term "venous shunt" to describe it. This was recognized later as the draining vein of the lesion. McCormick<sup>7</sup> delineated the classical anatomical features of venous angioma. It is composed entirely of veins that intervene with neural parenchyma. These veins are commonly thick, hyalinized and have a sparse smooth muscle and elastic tissue.

Venous angioma is a congenital malformation of the normal venous drainage system. It has been reported in infants and children.<sup>8</sup> Complete absence of the normal draining veins in the region is substituted with abnormal venous channels that eventually drain into the dural sinuses. Although the pathogenesis of venous angioma is not known, Saito and Kobayashi<sup>9</sup> hypothesized that an intrauterine event happened during the formation of the medullary veins or their tributaries. Thrombosis, aplasia, hypoplasia or by some other unknown mechanism, lead to the formation of collateral venous pathways. It is also suggested, that abnormal development at appropriate gestational age could lead to an anomalous draining vein supplementing the usual drainage.

Venous angioma can be found in the supratentorial space, which behaves, in a benign nature and infratentorial, which may have a slightly increased risk of hemorrhage. It has been reported to cause epilepsy, progressive neurological deficits and hemorrhage,<sup>8,10,11</sup> however, other authors have considered them to be clinically insignificant.<sup>8,12</sup> Cerebellar venous angioma is frequently associated with symptoms such as gait ataxia, diplopia and dizziness even in the absence of hemorrhage. Annual risk of hemorrhage for DVAs has been calculated in 2 major studies. Garner et al<sup>8</sup> estimated the risk of hemorrhage to be of 0.22% per year (one hemorrhage per 4498 person-years of follow-up) based on the clinical follow-up of 100 patients with DVA. In the second study, McLaughlin et al<sup>13</sup> estimated the risk of hemorrhage to be 0.61% per year (18 bleeds in 2949 patient-years) on 80 patients with DVA.

The angiographic features of venous angioma are pathognomonic especially in the late venous phase. Fine veins are seen essentially in the white matter converging to a dilated vein draining into the superficial system or less commonly to the deep venous system. The arterial phase and the capillary phase are essentially normal. Radiological appearances have been referred to as a "Palm Tree," "Umbrella," or "Caput Medusa" due to the appearance of the peripheral draining veins.<sup>8,11-14</sup> The

CT scan shows a linear or curvilinear enhancement after contrast administration. Usually, there is no mass effect unless a hematoma is near by.<sup>14</sup> An MRI will illustrate a similar appearance to the CT scan, a linear area of hypointensity in T1 and hyper or hypointense in T2.<sup>4</sup> Due to the low estimated annual risk of hemorrhage and the potential risk of venous infarction after surgical excision or radiosurgery, conservative management is the treatment of choice.<sup>8,11,13</sup> The surgical removal of the venous angioma may result in a venous infarct of the adjacent brain.<sup>15</sup> In cases of intracerebral hemorrhage from apparently isolated venous angioma causing significant neurological deficits and mass effect, evacuation of the clot with preservation of the venous angioma is recommended. When a hemorrhage is caused by the conjunction of a venous angioma associated with a cavernous malformation, surgical resection or radiosurgery of the cavernous malformation is performed and preservation of the venous angioma is the recommended treatment.

## References

1. Sarwar M, McCormick W. Intracerebral venous angioma. Case report and review. *Arch Neurol* 1978; 35; 323-325.
2. Comey C, Kondziolka D, Yonas H. Regional parenchymal enhancement with mixed cavernous/venous malformations of the brain: Case report. *J Neurosurg* 1997; 86; 154-158.
3. Goualo A, Alvarez H, Garcia Monaco R. Venous anomalies and abnormalities of the posterior fossa. *Neuroradiology* 1990; 31; 476-482.
4. Rigamonti D, Spetzler R. Appearance of venous malformation on magnetic resonance imaging. *J Neurosurg* 1988; 69; 535-539.
5. Pfannenstiel J. Apoplexie als tödlicher Ausgang von Eklampsie. *Zentralbl Gynakol* 1887; 11; 601-606.
6. Courville C. Morphology of small vascular malformations of the brain. With particular reference to their drainage. *J Neuropathol Exp Neurol* 1963; 22: 274.
7. McCormick W. The pathology of the vascular ("arteriovenous") Malformations. *J Neurosurg* 1966; 24; 807-816.
8. Garner T, Del Curling Jr. O. The natural history of intracranial venous angiomas. *J Neurosurg* 1991; 75; 715-722.
9. Saito Y, Kobayashi N. Cerebral venous angioma. Clinical evaluation and possible etiology. *Radiology* 1981; 139; 87-94.
10. Beatty R, Zervas N. stereotactic aspiration of a brain stem hematoma. *Neurosurgery* 1983; 13; 204-207.
11. Rigamonti D, Spetzler R. Cerebral venous malformations. *J Neurosurg* 1990; 73; 560-564.
12. Agnoli AL, Hildebrandt G. cerebral venous angiomas. *Acta Neurochir* 1985; 78; 4-12.
13. McLaughlin M, Kondziolka D. The prospective natural history of cerebral venous malformations. *Neurosurgery* 1998; 43; 195-201.
14. Valavanis A, Aellauer J, Yasargil MG. The radiological diagnosis of cerebral venous angioma: cerebral angiography and computed tomography. *Neuroradiology* 1998; 24; 193-199.
15. Senegor M, Dohrmann G. Venous angiomas of the posterior fossa should be considered as anomalous venous drainage. *Surg Neurol* 1983; 19; 26-32.