

Alveolar hydatid disease of the spine causing paraplegia

Hakan H. Kadioglu, MD, PhD, Umit A. Malcok, MD, Goksin Sengul, MD, Ismail H. Aydin, MD, FCNS.

ABSTRACT

Hydatid disease involving the vertebral body and paravertebral soft tissues is a rare disease with poor prognosis. We report a case of spinal cord compression caused by secondary extradural cysts.

Neurosciences 2005; Vol. 10 (2): 180-182

Hydatic disease occurs in humans as a result of feco-oral contamination. Vertebral involvement is estimated to represent 0.5-2% of all cases.^{1,2} The lack of characteristic radiographic features and accompanying neurologic deficits cause difficulties in the diagnosis of this condition. A rare case of secondary thoracic extradural hydatid cyst, which causes spinal cord compression, is reported and clinical presentation, diagnosis and surgical treatment are discussed.

Case Report. A 36-year-old woman was admitted to the hospital with back pain, progressive bilateral leg weakness, and sphincter dysfunction for one month. On neurological examination, she had paraparesis with loss of deep tendon and anal reflexes. Plain radiographs of thoracolumbar spine showed collapse of 9th-11th thoracic vertebral bodies and disc spaces could not be identified. An MRI revealed a well-bordered, multilobulated cystic mass lesion that compressed the dural sac and spinal cord, collapse of anterior vertebral body and destruction at the intervertebral discs. This lesion was hypointense on T1 weighted images and hyperintense on T2 weighted images. Axial images showed extradural localization and extension into paravertebral muscles with noncontrast

enhancement (**Figures 1 & 2**). Ultrasonography of the liver revealed a multiseptated cyst in the seventh segment. The patient underwent posterior spinal decompression, curettage, drainage and washout of paravertebral cyst cavities. Histopathological examination confirmed Periodic acid-Schiff positive folded lamellae of *Echinococcus multilocularis* in necrotic tissue surrounded by fibrosis and mononuclear inflammatory reaction (**Figures 3-5**). Postoperatively mebendazole was given orally for one year. She was discharged on the seventh day without any recovery of neurological deficits and referred to a rehabilitation program.

Discussion. Alveolar echinococcosis always represents as a late metastatic disease originating from a longstanding primary liver focus, which is usually seen in adults. Pathogenesis of the secondary infestation remains poorly understood. There may be vascular or lymphatic migration of a fertile cell from the hepatic focus. Echinococcosis affecting the spine is rare in rural areas where echinococcosis is endemic.³ Generally, spinal hydatid disease presents with a radicular symptom of cord compression. Plain radiographs may show the collapse of vertebral bodies and narrowing of intervertebral disc spaces. Both CT and MRI are

From the Department of Neurosurgery, Research Hospital, Ataturk University Medical School, Erzurum, Turkey.

Received 10th July 2004. Accepted for publication in final form 31st October 2004.

Address correspondence and reprint request to: Dr. Hakan H. Kadioglu, Department of Neurosurgery, Research Hospital, Ataturk University Medical School, Erzurum 25070, Turkey. Tel. +90 4423152393. Fax. +90 4423166340. E-mail: hakanhadi@superonline.com

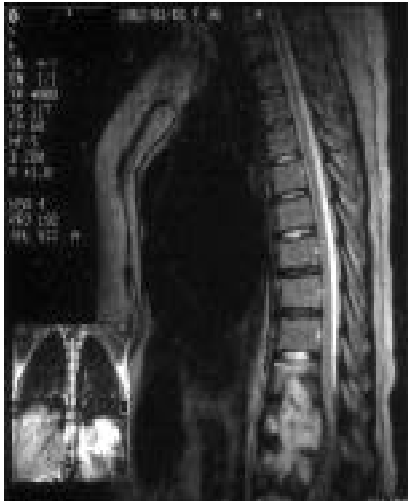

Figure 1 - Sagittal T2-weighted magnetic resonance image shows a well-defined, multilobulated, extradural intraspinal hyperintense cystic lesion.

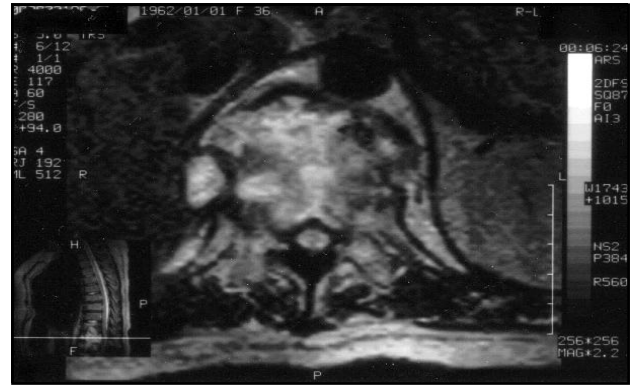

Figure 2 - Axial T2-weighted magnetic resonance image shows the hyperintense lesion localized extradurally, and extended into paravertebral muscles.

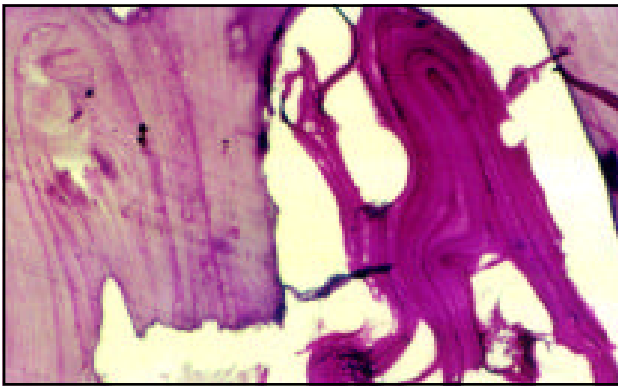


Figure 3 - Bone tissue and lamellae of *Echinococcus multilocularis* in a necrotic tissue (Hematoxylin and Eosin x 100).

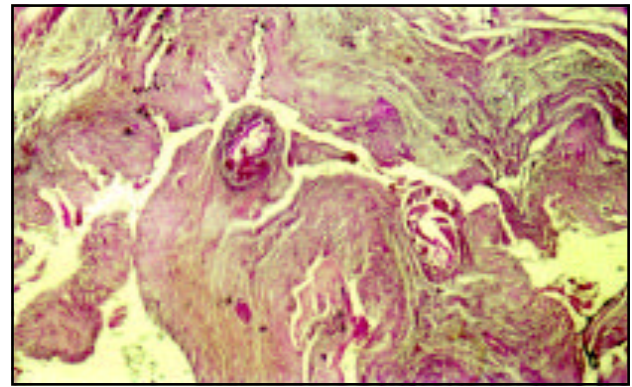


Figure 4 - Periodic acid-Schiff positive folded lamellae of *Echinococcus multilocularis* (x 100).

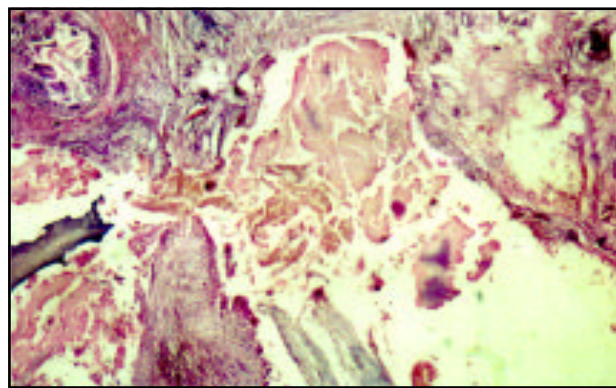


Figure 5 - Periodic acid-Schiff positive folded lamellae of *Echinococcus multilocularis* in bone tissue (x 400).

superior because they can precisely define the borders of the infection and detect its extension to adjacent structures. The CT further contributes to the evaluation of such a vertebral mass lesion. The expansion, exact location and nature of the lesion can be assessed more accurately with the aid of CT examination.⁴ The usefulness of MR imaging lies in the precise definition of anatomic relationships due to the multiplanar capabilities and the excellent contrast resolution for soft tissues. Detailed information about the MR findings of the hepatic and extrahepatic echinococcosis has been well described in the literature. A more or less continuous hypointense rim, more prominent on T2-weighted images was defined in most cases, which were believed to represent the pericyst, consisting of a dense fibrous capsule from reactive host tissue.

Tuberculosis and other granulomatous infections affecting the vertebral bodies causing paravertebral abscess and tumors must be considered in the differential diagnosis. In our patient, multiple cysts in the vertebral bodies and non-enhancement of a psoas abscess after intravenous gadolinium led to the diagnosis of hydatid disease.

The histological diagnosis of alveolar echinococcosis is made from typical findings of "alveolar" vesicles with a characteristic lamellar outer layer and inflammatory reaction surrounding areas of necrosis. Microscopically, a cuticle is the sign of an echinococcosis. The larval stage of the organism may be seen in the cysts, but this rarely seems possible. To make the diagnosis the pathologist has relied on the characteristic histological appearance, rather than on strict demonstration of the parasite.^{5,6} It is difficult to distinguish from a hydatid cyst at histological study, as the latter takes on a multilocular appearance in the bone.⁶

Surgery remains the best therapy for spinal hydatid disease, although adjuvant antihelminthic therapy may be necessary. The surgical goal should be an extensive removal of the cysts and affected

bone. After surgery, antihelminthic medication by high dose mebendazole or albendazole is advised for a long time.^{7,8} Surgery has been the treatment of choice although success is limited. A complete recovery is quite exceptional. Recurrence of disease is common because the disease invasively involves the bone, and the canal.⁸ However, reported series and long-term outcomes relating to spinal alveolar echinococcosis are inadequate.

In conclusion, alveolar echinococcosis should be considered in the differential diagnosis of diseases causing spinal destruction. Magnetic resonance imaging, although not specific for alveolar hydatid disease, must be superior in suspected cases of spinal echinococcosis. Although various therapy modalities may be applied in the treatment for hydatid disease, surgical decompression in addition with antihelminthic medication is the best approach.

References

1. Apt WL, Fierro JL, Calderon C, Perez C, Mujica P. Vertebral hydatid disease. Clinical experience with 27 cases. *J Neurosurg* 1976; 44: 72-76.
2. Fares Y, Khazim R, El Zatari MM, Haddad GF, Barnes PR. Spinal hydatid disease and its neurological complications. *Scand J Infect Dis* 2003; 35: 394-396.
3. Basak M, Ozel A, Yildirim O, Erturk M. Relapsing hydatid disease involving the vertebral body and paravertebral soft tissues. *Acta Radiol* 2002; 43: 192-193.
4. Begs I. The radiology of hydatid disease. *AJR Am J Roentgenol* 1985; 145: 639-648.
5. Aydın Y, Barlas O, Yolas C, Aydın IH, Ceviz A, Aladag A et al. Alveolar hydatid disease of the brain. Report of four cases. *J Neurosurg* 1986; 65: 115-119.
6. Claudon M, Bracard S, Plenat F, Regent D, Bernadac P, Picard L. Spinal involvement in alveolar echinococcosis: Assessment of two cases. *Radiology* 1987; 162: 571-572.
7. Porat S, Robin GC, Wertheim G. Hydatid disease of the spine causing paraplegia. The combined treatment by surgical drainage and mebendazole: a case report. *Spine* 1984; 9: 648-653.
8. Savas R, Calli C, Alper H, Yuntun N, Ustün EE, Ertugrul G et al. Spinal cord compression due to costal Echinococcus multilocularis. *Comput Med Imaging Graph* 1999; 23: 85-88.