

Warfarin induced skin necrosis in a patient with craniopharyngioma

Mohammad H. Bhat, MBBS, MD, Sanjay Bhadada, MD, DM, Anil Bhansali, MD, DM, Pinaki Dutta, MD, DM.

ABSTRACT

Oral anticoagulants are associated with several adverse skin manifestations ranging from ecchymosis, purpura, and hemorrhagic necrosis to maculopapular rash, vesicular urticarial eruptions and purple toes. Skin necrosis is a rare but serious side effect of warfarin therapy, associated with significant morbidity and mortality. The prevalence of warfarin induced skin necrosis (WISN) is 0.01-0.1%. We report a 20-year-old female patient of craniopharyngioma who developed WISN following postoperative femoropopliteal deep vein thrombosis.

Neurosciences 2006; Vol. 11 (1): 50-52

Warfarin induced skin necrosis (WISN) was first described in 1943¹ and there are approximately 300 cases reported so far. It is a rare and dangerous complication affecting 0.01-0.1% of patients.² Failure in early diagnosis and treatment may result in death. Most patients require surgical intervention with local debridement, skin grafting, or even amputation. Warfarin induced skin necrosis usually occurs in perimenopausal obese middle-aged women treated for deep vein thrombosis or pulmonary thromboembolism. The most common site is the breast followed by buttocks, thighs, and abdomen. One bases the diagnosis mainly on clinical grounds, or biopsies at a later stage. However, the pathological changes include microvascular injury with fibrin deposits in the post capillary venules and small veins, hemorrhage and diffuse necrosis in the dermis and subcutaneous fat. The differential diagnosis of WISN includes venous gangrene, necrotizing fasciitis, and disseminated coagulopathy with purpura fulminans, ecthyma, cellulites, and Fournier's gangrene. We report a 20-year-old female

patient of craniopharyngioma who developed WISN following postoperative femoropopliteal deep vein thrombosis, which is a rare and serious side effect of warfarin treatment associated with significant morbidity and mortality. With the increasing number of patients being anti-coagulated as out-patients for thromboprophylaxis, clinicians should be aware of this rare entity, as sometimes it may be confused with other dermatological conditions.

Case Report. A 20-year-old female presented with headache, vomiting, and progressive diminution of vision of 3 months duration. On examination, she was conscious with a pulse rate of 88 beats per minute, blood pressure of 120/80 mm Hg with no postural drop. Neurological examination was normal except bilateral optic atrophy. Her secondary sexual characters were normal. Investigations revealed normal hemogram and serum biochemistry. Serum sodium was 134 meq/L, and potassium 3.9 meq/L. Thyroid functions were normal with triiodothyronine (T₃) 1.28 ng/ml (0.6-1.01), thyroxine (T₄) 8.5 ng/ml

From the Department of Endocrinology, Postgraduate Institute of Medical Education and Research, Chandigarh, India.

Received on 8th June 2005. Accepted for publication in final form 27th September 2005.

Address correspondence and reprint request to: Dr. Anil Bhansali, Department of Endocrinology, Postgraduate Institute of Medical Education and Research, Chandigarh 160012, India. Tel. +91 (172) 747585-600 Ext. 6583. Fax. +91 (172) 744401/745078. E-mail: anilbhansali_endocrine@rediffmail.com

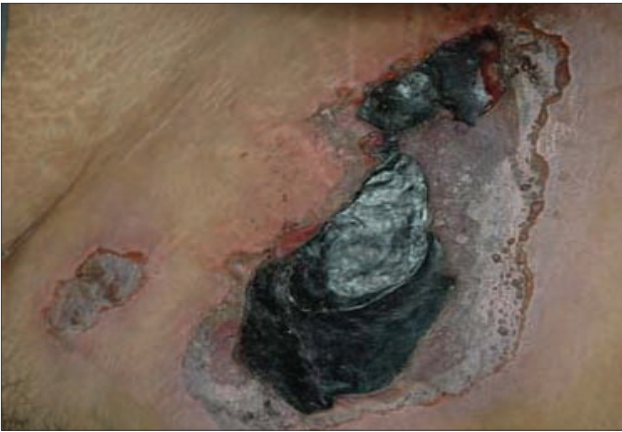

Figure 1 - Extensive skin necrosis with eschar formation on anterior abdominal wall.

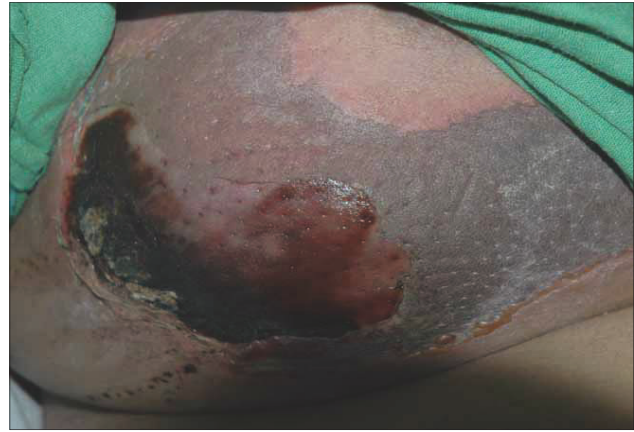


Figure 2 - Extensive skin necrosis on the right breast.

(5.5-11) and thyroid stimulating hormone (TSH) 2.11 μ mIU/L (0.35-5.5). Her 0800 hour serum cortisol was 126 ng/ml (40-150), luteinizing hormone 5.6 mIU/L (5-15), follicle-stimulating hormone 8.2 mIU/L (5-15), and prolactin 8.8 ng/ml (5-25). Perimetry showed left inferotemporal quadrantanopia. Contrast enhanced MRI of the sella showed a 3 x 2 cm suprasellar mass with cystic and solid components suggestive of a craniopharyngioma. She underwent right craniotomy with near total excision of the tumor. Postoperatively, on day 7 she developed pain and swelling in the right calf muscle, which was confirmed to be right femoropopliteal deep vein thrombosis by compression ultrasound and venous Doppler. Her prothrombin time index (PTI) and partial thromboplastin time with Kaolin (PTTK) before starting anticoagulation were 98% and 37 seconds (C-35). She was put on low molecular weight heparin and warfarin. Following anticoagulation, her PTI was 55% and PTTK was 68 seconds (C-35). Three days later she developed hemorrhagic areas of skin necrosis in the breasts, abdomen, and groin (Figures 1 & 2). The lesions were painful and initially started as blisters followed by maculopapular eruptions and later full thickness skin necrosis. She was subjected to extensive debridement, but the lesions became secondarily infected. Cultures from the lesions grew *Escherichia coli*. She was treated with broad-spectrum antibiotics and despite cessation of warfarin some lesions continued to progress. The patient died of septic shock.

Discussion. Warfarin induced skin necrosis is a rare and dangerous complication affecting 0.01-0.1% of patients.²⁻⁵ It is usually associated with high morbidity, and frequently requires surgical intervention with local debridement, skin grafting

or even amputation. Failure in early diagnosis and treatment may result in death. The lesions start with paresthesias or a sensation of pressure and erythema. They become painful, well-localized, and erythematous. There occurs accumulation of edema in the dermis and subcutaneous tissue. Over the next 24 hours, there is development of petechiae and hemorrhagic bullae within the borders of the involved skin finally leading to full thickness skin necrosis,³ and eschar sloughs revealing a defect up to subcutaneous fat. Smaller lesions may heal by granulation and scarring, but extensive lesions require surgical debridement and skin grafting or amputation. The WISN usually occurs in perimenopausal obese middle-aged women undergoing treatment for deep vein thrombosis or pulmonary thromboembolism.⁴ Our patient was young with a BMI of 29.8 kg/m². Ad-EL et al⁵ reports WISN in a patient aged 17 years of age. The lesions appear within 1-10 days after initiation of warfarin therapy, though most of them appear on the third to sixth day. Our patient developed lesions 3 days following initiation of warfarin. The most common site is the breast, followed by buttocks, thighs, and abdomen.⁶ Our patient had lesions on the breasts, groin and abdomen. One bases the diagnosis mainly on clinical grounds, as we usually take biopsies at a later stage. However, the pathological changes include microvascular injury with fibrin deposits in the post capillary venules and small veins, hemorrhage and diffuse necrosis in the dermis and subcutaneous fat.⁷ We do not fully know the precise nature of this entity. Several pathophysiological mechanisms that have been suggested include thrombosis, hypersensitivity, protein C and S deficiency and a direct toxic effect of warfarin.^{7,8} However, observations show that administration of warfarin to

protein C and S deficient patients causes increased imbalance between procoagulant and anticoagulant pathways. Thus, the early suppressive action of warfarin on protein C may not be counterbalanced by the anticoagulant effect created by the decrease of other vitamin K dependent fractions. As a result producing a relative hypercoagulable state leading to thrombotic occlusion of the microvasculature and necrosis.⁸ A few cases have been seen in patients with protein S deficiency and antithrombin 111 deficiency.^{9,10} Recently, Byrne et al¹¹ described a mutation in the methylene tetrahydrofolate reductase gene (MTHFR). Typically administration of large loading doses of the drug is associated with WISN, although our patient did not receive a large loading dose. We do not recommend screening of patients for protein C or S or antithrombins 111 deficiencies, as they are neither sensitive nor specific in predicting WISN. The medical treatment consists of early vitamin K, parenteral monoclonal antibody purified protein C concentrate and prostacyclin.^{12,13} However, more than 50% patients need debridement or even amputation of extremities.¹⁴ Once the necrotic areas are secondarily infected, outcome is usually fatal and patients succumb to sepsis.⁶ We managed our patient with wide surgical debridement and broad spectrum antibiotics. However, her lesions were secondarily infected and she died of septic shock.

In conclusion, WISN is a rare and dangerous complication affecting 0.01-0.1% of patients on warfarin. Previously uncomplicated administration of warfarin does not necessarily obviate the possibility of skin necrosis with future administration. Initiation of low dose warfarin with heparin reduces the likelihood of this disorder. Differential diagnosis of WISN includes venous gangrene, necrotizing fasciitis, and disseminated coagulopathy with purpura fulminans, ecthyma, cellulites, and Fournier's gangrene.

References

1. Flood EP, Redish MH, Bociek SJ, Shapiro S. Thrombophlebitis migrans disseminata: Report of a case in which gangrene of a breast occurred: observations on the therapeutic use of dicumarol (3,3'-methylenebis(4-hydroxycoumarin)). *N Y State J Med* 1943; 43: 1121-1124.
2. Chan YC, Valenti D, Mansfield AO, Stansby G. Warfarin induced skin necrosis. *Br J Surg* 2000; 87: 266-272.
3. Eby CS. Warfarin induced skin necrosis. *Hematol Oncol Clin North Am* 1993; 7: 1291-1300.
4. Nalbandian RM, Mader IJ, Barret JL, Pearce JF, Rupp EC. Petechiae, ecchymoses and necrosis of skin induced by coumarin congeners. Rare occasionally lethal complication of anticoagulant therapy. *JAMA* 1965; 103: 271-277.
5. Ad-EL DD, Meirovitz A, Weinberg A, Arielli KD, Neumann A, Linton D. Warfarin induced necrosis: local and systemic factors. *Br J Plast Surg* 2000; 53: 624-626.
6. Scandling J, Walker BK. Extensive tissue necrosis associated with warfarin sodium therapy. *South Med J* 1980; 73: 1470-1472.
7. Cole MS, Minifee PK, Wolma FJ. Coumarin necrosis-a review of literature. *Surgery* 1988; 103: 271-277.
8. Becker CG. Oral anticoagulant therapy and skin necrosis. Speculations on pathogenesis. *Adv Exp Med Biol* 1987; 214: 217-222.
9. McGhee WG, Klotz TA, Epstein DJ, Rapaport SI. Coumarin necrosis associated with hereditary protein C deficiency. *Ann Intern Med* 1984; 100: 59-60.
10. Cheng A, Scheinfeld NS, McDowell B, Dokras AA. Warfarin skin necrosis in a postpartum woman with protein S deficiency. *Obstet Gynecol* 1997; 90: 671-672.
11. Byrne JS, Abdul Razak AR, Patchett S, Murphy GM. Warfarin skin necrosis associated with protein S deficiency and a mutation in the methyltetrahydrofolate reductase gene. *Exp Dermatol* 2004; 29: 35-36.
12. Lawondowski K, Zawilska K. Protein C concentrate in the treatment of warfarin induced skin necrosis in the protein C deficiency. *Thromb Hemost* 1994; 71: 395.
13. Norris PG. Warfarin skin necrosis treated with prostacyclin. *Clin Exp Dermatol* 1987; 12: 370-372.
14. Stewart AJ, Penman ID, Cook MK, Ludlam CA. Warfarin induced skin necrosis. *Postgrad Med J* 1999; 75: 233-235.