

Incidence and morphology of the accessory head of the flexor pollicis longus muscle (Gantzer's muscle) in a Turkish population

Feray G. Uyaroglu, MD, Gulgun Kayalioglu, MD, Mete Erturk, MD.

ABSTRACT

Objective: To present the incidence, morphology, and the relationships of the accessory head of the flexor pollicis longus (Gantzer's) muscle (AHFPL) in a recent Turkish population.

Methods: The study was performed on 52 upper extremities of 26 adult Turkish cadavers in the Department of Anatomy, Ege University Faculty of Medicine, Izmir, Turkey in 2005. In our dissections, the prevalence and anatomical morphology of the AHFPL including muscle shape, origin and insertion point, and its relation to the anterior interosseous nerve (AIN) was examined.

Results: The AHFPL muscle was found in 27 upper extremities (51.9%). It was bilateral in 10 cadavers (74%), and unilateral in 7 cadavers (26%). The muscle shape was

spindle in 19 (70.4%), and papillary in 8 (29.6%). The AHFPL originated from the coronoid process of the ulna in 22 upper extremities (81.5%), and the medial epicondyle of the humerus in 5 cases (18.5%). The AIN passed anterior to the AHFPL in one case (3.7%), lateral in 3 (11.1%), posterolateral in 8 (29.6%) and posterior in 15 (55.6%) cases.

Conclusion: The knowledge of the morphology and the topography of the AIN and AHFPL is important for understanding the mechanism of the AIN syndrome. The results of this study show the mechanical compression due to the AHFPL may be a cause of the pronator and AIN syndromes.

Neurosciences 2006; Vol. 11 (3): 171-174

The flexor pollicis longus muscle (FPL) arises from the upper part of anterior surface of the radius and the anterior surface of the interosseous membrane. This muscle is sometimes connected to the flexor digitorum superficialis, profundus, or pronator teres muscles. The FPL muscle and its interosseous attachment may be absent. Anomalous tendon slips from the FPL to the flexor digitorum profundus are frequently observed. Usually, the FPL has a slip arising in common with the flexor digitorum superficialis muscle from the medial border of the coronoid process or the medial epicondyle or from both, named variously as the accessory head of the FPL muscle (AHFPL) or Gantzer's muscle. The anterior

interosseous nerve (AIN) arises from the median nerve in the distal part of the cubital fossa, and it passes distally on the anterior interosseous membrane and supplies the flexor digitorum profundus, the FPL and the pronator quadratus muscle. The AIN and vessels descend on the interosseous membrane between the FPL and flexor digitorum profundus muscles. The FPL is innervated by the anterior interosseous branch of the median nerve that originates from the C7-8 spinal nerves.¹⁻⁵ The AHFPL is considered an archaic pattern of the flexor muscles of the forearm. It usually connects to the radial part of the FPL.^{6,7} A well-developed FPL is not present in primates except for the human. Its presence differentiates the forearm,

From the Departments of Neurology (Uyaroglu) and Anatomy (Kayalioglu, Erturk), Faculty of Medicine, Ege University, Izmir, Turkey.

Received 13th February 2006. Accepted for publication in final form 15th March 2006.

Address correspondence and reprint request to: Dr. Gulgun Kayalioglu, Department and Anatomy, Faculty of Medicine, Ege University, TR035100, Bornova, Izmir, Turkey. Tel. +90 (532) 6860921. Fax. +90 (232) 3422142. E-mail: kayali@rocketmail.com

and the hand of the human from other primates.⁸⁻¹¹ Kiloh and Nevin (1952) first suggested the role of AHFPL in the *AIN syndrome*, later confirmed by other studies.^{7,11-17} This study was performed on a large series of adult Turkish cadavers to present the incidence, morphology and the relationships of the AHFPL to reveal the underlying mechanism for the AIN syndrome, and guide the surgeon in regional surgical approaches.

Methods. This study was performed on 52 upper extremities of 26 adult Turkish cadavers (23 male, 3 female) in the Department of Anatomy, Ege University Faculty of Medicine, Izmir, Turkey in 2005. In our forearm dissections, the presence of AHFPL was investigated (**Figure 1**). When present, the shape and origin of the AHFPL, its insertion point to the FPL and its relation to the AIN were examined. The length, width of the AHFPL, the length of its tendon, and the distance between the insertion point of AHFPL to the medial margin of FPL and the distal wrist line (DWL) were measured using a stainless steel caliper. Distance between the arising point of the AIN and the interepicondylar line (IEL) were also measured.

Results. The AHFPL muscle was found in 27 of 52 upper extremities (51.9%). It was bilateral in 10 cadavers (74%) and unilateral in 7 cadavers (26%). Its shape was spindle in 19 (70.4%) and papillary in 8 (29.6%) specimens. The AHFPL originated from the coronoid process of the ulna in 22 upper extremities (81.5%) and the medial epicondyle of the humerus in 5 cases (18.5%). The length and width of the AHFPL, its tendon length and the distance between the insertion point of AHFPL to the medial margin of FPL and the DWL are shown in **Table 1**. In one forearm, the AHFPL had 2 muscle bellies and 2 tendons (3.7%). The AHFPL was innervated by the AIN in all cases (**Figure 2**). The nerve arose from the medial aspect of the median nerve. The arising point of the AIN was 33.79 mm below the IEL. The AIN crossed anterior to the AHFPL in one case (3.7%). The AIN was located lateral to the AHFPL in 3 (11.1%), posterolateral in 8 (29.6%) and posterior in 15 (55.6%) cases.

Discussion. The presence and morphology of the AHFPL (Gantzer's muscle) and its relations to the AIN were investigated in former studies. The incidence of the AHFPL was found as 66.7% by Oh et al,¹⁸ 66.6% by Hemmady et al,¹⁹ 62.1% by Mahakkanukrauh et al,²⁰ 55% by Jones et al²¹ and Shirali et al,²² 52% by Al-Qattan,⁷ and 45% by Dellon and Mackinnon.²³ In our study on a recent Turkish population, the AHFPL was found in 27 of 52 upper extremities

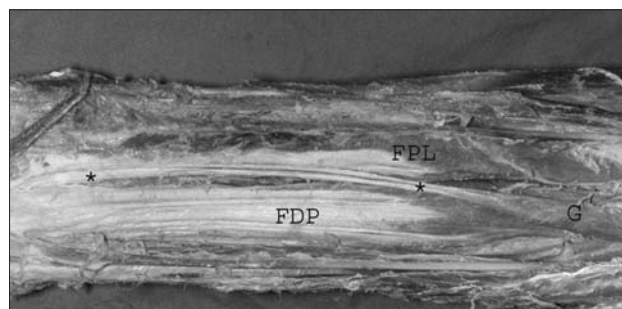


Figure 1 - Gantzer's muscle (G) in the right forearm. FPL - flexor pollicis longus muscle, FDP - flexor digitorum profundus muscle, *tendon of the AHFPL.

Table 1 - Measurements of the accessory head of the flexor pollicis longus muscle (AHFPL) and anterior interosseous nerve (AIN).

Measurements	Mean ± SD	Min-Max
Length	71.25 ± 11.97	46.2 - 98
Width	6.99 ± 2.38	4 - 11.8
Tendon length	20.7 ± 17.7	3.5 - 78
INS-DWL	127.35 ± 21.47	58.4 - 152
AIN-IEL	33.79 ± 6.1	24.4 - 42.2

INS - insertion point of the AHFPL to the medial margin of FPL, DWL - distal wrist line, IEL - interepicondylar line.




Figure 2 - The accessory head of the flexor pollicis longus muscle (G) and the anterior interosseous nerve (AIN) in left forearm. FPL - flexor pollicis longus muscle, FDP - flexor digitorum profundus muscle, MN - median nerve.

(51.9%). Oh et al¹⁸ observed AHFPL bilateral in 50% and unilateral in 33% of their cadaveric specimens, whereas Mahakkanukrauh et al²⁰ observed bilateral in 75.3% and unilateral in 24.7% of their specimens. Jones et al²¹ found the AHFPL bilateral in 58.4% and unilateral in 33.4%. In our study, AHFPL was observed bilateral in 10 cadavers (74%) and unilateral in 7 cadavers (26%).

The AHFPL may originate from the coronoid process of the ulna, the medial epicondyle of the

humerus and the flexor digitorum superficialis muscle. Oh et al¹⁸ found its origin as the coronoid process of the ulna in 87.5%, the medial epicondyle of the humerus in 10.4% and the flexor digitorum superficialis muscle in 2.1% of their cases. Mahakkanukrauh et al²⁰ observed the AHFPL originating from the coronoid process of the ulna in 23.5%, the medial epicondyle of the humerus in 74.5% and the flexor digitorum superficialis muscle in 2% of their specimens. In the study of Hemmady et al,¹⁹ the origin was the coronoid process of the ulna in 16.6% and the medial epicondyle of the humerus in 55.5% of the cadavers. Jones et al²¹ observed the flexor digitorum superficialis muscle, and Al-Qattan⁷ the medial epicondyle of the humerus (85%). The muscle was arising from the coronoid process of the ulna (81.5%), and the medial epicondyle of the humerus (18.5%) in our study.

The shape of the AHFPL was observed as papillary, spindle (fusiform) and band (slender) type in former studies.^{18,20} Oh et al¹⁸ observed papillary type in 62.4%, spindle type in 18.8% and band type in 18.8% of their cadavers. Mahakkanukrauh et al²⁰ observed spindle type in 98% and slender type in 2% of cases. Jones et al²¹ used a different classification, as slender (42.9%), voluminous (28.6%), triangular (14.3%), and fusiform (14.3%) types. In our study, the shape of the AHFPL was spindle (70.4%) or papillary (29.6%).

The average width of the AHFPL was 7 mm in the study of Oh et al,¹⁸ 6.7 mm in the study of Mahakkanukrauh et al,²⁰ 10-25 mm in the study of Hemmady et al,¹⁹ and 6.99 mm in our study. The mean length of the muscle belly was found as 50-80 mm by Hemmady et al,¹⁹ 68 mm by Jones et al,²¹ and 71.25 mm in our study. The tendon length of the AHFPL was measured as 11.7 mm by Jones et al,²¹ and 20.7 mm in our study. The distance between the insertion point of the AHFPL to the FPL muscle and the distal wrist line was measured as 128 mm by Mahakkanukrauh et al,²⁰ and 127.35 mm in our study. The average distance between the arising point of the AIN on the median nerve to the IEL was found as 49 mm by Oh et al.¹⁸ The arising point of the AIN was 33.79 mm below the IEL in our study.

The most common course of the AIN was posterior to the AHFPL.²² The topographical relationship of the AIN to the AHFPL was classified as 3 different types by Oh et al.¹⁸ The nerve crossed the muscular part of the AHFPL in Type A (56.3%), the tendinous part of the muscle in Type B (10.4%), and it coursed lateral to the AHFPL in Type C (33.3%). Mahakkanukrauh et al²⁰ classified the course of the AIN in 4 groups. The AIN passed anterior to the AHFPL in Type 1 (13.4%), lateral to the AHFPL in Type 2 (65.8%), posterior to

the AHFPL in Type 3 (8.1%) and the AIN passed both lateral and posterior to the AHFPL in Type 4 (12.8%). Using the same classification, we observed the AIN crossing anterior to the AHFPL in one case (3.7%), lateral in 3 (11.1%), posterolateral in 8 (29.6%) and posterior in 15 (55.6%) cases.

It was indicated that the mechanical compression due to the AHFPL may cause pronator and AIN syndromes.^{11,19} Tabib et al¹⁵ reported a case of incomplete AIN syndrome due to mechanical compression by the AHFPL. Degreef and De Smet²⁴ stated a case of an older female patient with paralysis of the AIN caused by an accessory muscle slip of the FPL muscle. Narayana et al²⁵ found a case of coexistence of the Gantzer's muscle, Martin-Gruber anastomosis and the nerve of Henle in the forearm of the male cadaver. The AIN syndrome is characterized by paralysis of the FPL muscle, the flexor digitorum profundus muscle to the index and middle fingers, and the pronator quadratus muscle. The nerve compression is frequently caused by the pronator teres muscle, or the fibrous arcade of the flexor digitorum superficialis muscle.²⁶ Bilecenoglu et al²⁷ also report AHFPL as an important factor compressing the median nerve.

The morphology and the topographical classification of the relationship between the AIN and the accessory head of FPL muscle is considered to be helpful in understanding the mechanism of AIN syndrome.¹⁸ There are some differences between our results and the findings of previous studies such as incidence and origin site of the AHFPL and the course of the AIN. Probably, these differences occur due to the differences of the populations investigated, and also to the number of specimens studied. This study presents topographic features of the AHFPL and the accompanying AIN to be a guide for the surgeon in approaches to the region.

References

1. Moore KL, Dalley AF. Clinically oriented anatomy. 4th ed. Baltimore: Lippincott Williams and Wilkins; 1999. p. 758.
2. Romanes GJ. Cunningham's Textbook of Anatomy. 10th ed. London: Oxford University Press; 1964. p. 333.
3. Schaeffer JP. Morris' Human Anatomy. 11th ed. New York: The Blakiston Division, McGraw-Hill Book Company; 1953. p. 487.
4. Standring S. Gray's Anatomy, The Anatomical Basis of Clinical Practice. 39th ed. Edinburgh: Elsevier Churchill Livingstone; 2005. p. 877-878.
5. Testut L. Traite D'anatomie Humaine. Tome Premier. 5th ed. Paris: Octave Doin; 1904. p. 901.
6. Dellon AL. Musculoaponeurotic variations about the medial humeral epicondyle. *J Hand Surg (Br)* 1986; 11: 175-181.
7. Al-Qattan MM. Gantzer's muscle. An anatomical study of the accessory head of the flexor pollicis longus muscle. *J Hand Surg (Br)* 1996; 21: 269-270.

8. Brooks SJ. On the short muscles of the pollex and hallux of the anthropoid apes, with special reference to the opponens hallucis. *J Anat Physiol* 1888; 22: 78-95.
9. Tuttle RH. Postural, propulsive and prehensile capabilities in the cheiridia of chimpanzees and other great apes. In: Bourne GH, editor. The chimpanzee. Volume 2. Basel: Karger; 1970. p. 167-253.
10. Susman RL. Comparative and functional morphology of hominoid fingers. *Am J Phys Anthropol* 1979; 50: 215-236.
11. Susman RL. Hand function and tool behaviour in early hominids. *J Hum Evol* 1998; 35: 23-46.
12. Kiloh LG, Nevin S. Isolated neuritis of the anterior interosseous nerve. *Br Med J* 1952; 1: 850-851.
13. Kayamori R. Electrodiagnosis in Martin-Gruber anastomosis. *Nippon Seikeigeka Gakkai Zasshi* 1987; 61: 1367-1372.
14. Kida M, Ishida H. Gantzer's muscle like variation inserted into the forearm flexor retinaculum. *Okajimas Folia Anat Jpn* 1989; 66: 1-11.
15. Tabib W, Aboufarah F, Asselineau A. Compression of the anterior interosseous nerve by Gantzer's muscle. *Chir Main* 2001; 20: 241-246.
16. Van Egmond C, Tonino AJ, Kortleve JW. Steindler flexorplasty of the elbow in obstetric brachial plexus injuries. *J Pediatr Orthop* 2001; 21: 169-173.
17. Walliser M, Beer S, Mark G. Anterior interosseous nerve syndrome differential diagnosis of closed isolated flexor tendon lesion. *Swiss Surg* 2001; 7: 218-221.
18. Oh CS, Chung IH, Koh KS. Anatomical study of the accessory head of the flexor pollicis longus and the anterior interosseous nerve in Asians. *Clin Anat* 2000; 13: 434-438.
19. Hemmady MV, Subramanya AV, Mehta IM. Occasional head of flexor pollicis longus muscle: A study of its morphology and clinical significance. *J Postgrad Med* 1993; 39: 14-16.
20. Mahakkanukrauh P, Surin P, Ongkana N, Sethadavit M, Vaidhayakarn P. Prevalence of accessory head of flexor pollicis longus muscle and its relation to anterior interosseous nerve in Thai population. *Clin Anat* 2004; 17: 631-635.
21. Jones M, Abrahams PH, Sanudo JR, Campillo M. Incidence and morphology of accessory heads of flexor pollicis longus and flexor digitorum profundus (Gantzer's muscles). *J Anat* 1997; 191: 451-455.
22. Shirali S, Hanson M, Branovacki G, Gonzalez M. The flexor pollicis longus and its relation to the anterior and posterior interosseous nerve. *J Hand Surg (Br)* 1998; 23: 170-172.
23. Dellon AL, Mackinnon SE. Musculoaponeurotic variations along the course of the median nerve in the proximal forearm. *J Hand Surg (Br)* 1987; 12: 359-363.
24. Degreef I, De Smet L. Anterior interosseous nerve paralysis due to Gantzer's muscle. *Acta Orthop Belg* 2004; 70: 482-484.
25. Narayana K, Narendiran K, Shetty KP, Prashanthi N. A case of coexistence of three anatomical variations in the forearm: Gantzer's muscles, Martin-Gruber anastomosis, and nerve of Henle. *Eur J Anat* 2004; 8: 81-84.
26. Proudman TW, Menz PJ. An anomaly of the median artery associated with the anterior interosseous nerve syndrome. *J Hand Surg (Br)* 1992; 17: 507-509.
27. Bilecenoglu B, Uz A, Karalezli N. Possible anatomic structures causing entrapment neuropathies of the median nerve: an anatomic study. *Acta Orthop Belg* 2005; 71: 169-176.