

# Intracranial hydatid cyst. *Dilemma in diagnosis and management*

Marwan W. Najjar, MD, Yasser Rajab, MD, Yehyia El-Beheiri, MD.

## ABSTRACT

Intracranial hydatid disease is a parasitic infection that affects children in endemic areas such as the Mediterranean, South America, and Australia. In non-endemic areas, it is rare and may pose a diagnostic dilemma. We review a boy who presented with a right cerebral cyst. All investigations were negative, and hydatid cyst was encountered upon intra-operative exploration. We review the available diagnostic modalities, and the difficulty in reaching a preoperative diagnosis. We also review the surgical and medical treatment strategies. A cerebral hydatid cyst should be considered in children with cystic brain lesions even in non-endemic areas. Since serologic tests are frequently negative, the most reliable methods in reaching a diagnosis are radiological evaluation and histopathological examination. The cyst has a typical appearance on CT and MRI and this bears special importance on the treatment strategy where the cyst is best removed intact to avoid recurrence or anaphylaxis.

*Neurosciences 2007; Vol. 12 (3): 249-252*

From the Division of Neurosurgery (Najjar), American University of Beirut, Lebanon, and Departments of Radiology (Rajab) and Neurosurgery (El-Beheiri), Dr Erfan and Bagedo Hospital, Jeddah, Kingdom of Saudi Arabia.

Received 29th May 2006. Accepted 10th October 2006.

Address correspondence and reprint request to: Dr. Marwan W. Najjar, Assistant Professor of Surgery, Neurosurgery Division, American University of Beirut, PO Box 11-0236, Riad El Solh 1107 2020, Beirut, Lebanon. Tel. +961 (3) 043704. Fax. +961 (1) 363291. E-mail: mwnajjar@yahoo.com, mn12@aub.edu.lb

Intracranial hydatid cysts are rare in non-endemic areas and may pose a difficult diagnostic problem. We present a boy with a large intracranial cyst, where all serologic and other diagnostic tests were inconclusive and was found at surgery to harbor a hydatid cyst. We review the pertinent literature on intracranial hydatidosis, the diagnostic means

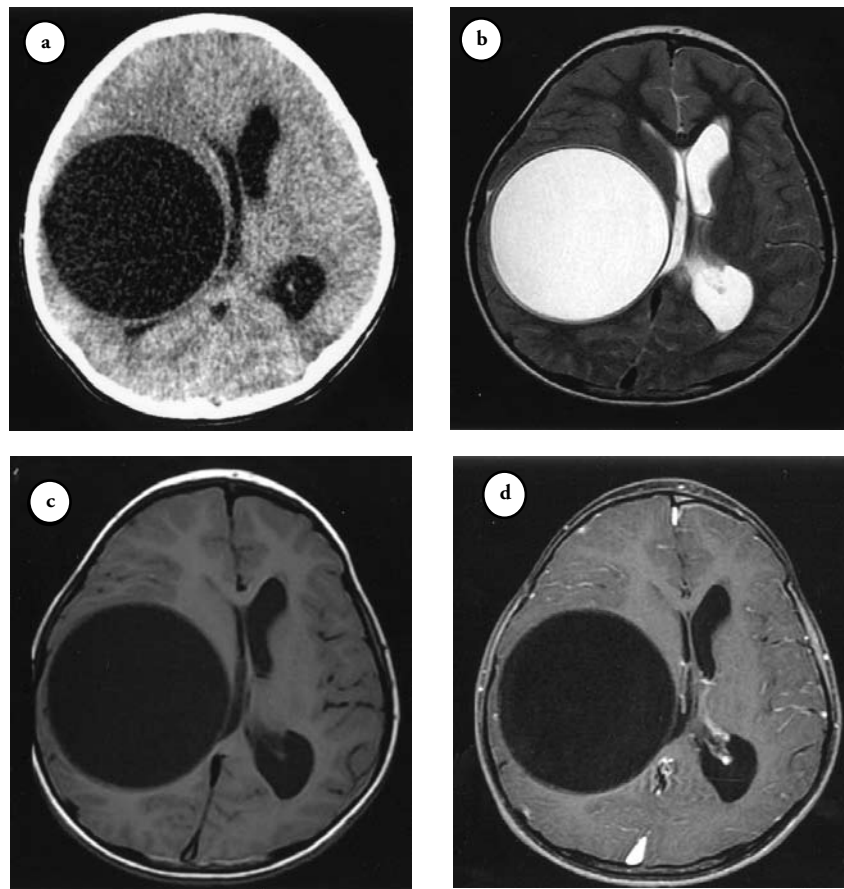
available in arriving at a pre-operative diagnosis, in addition to the treatment strategies and outcome. The difficulty in arriving at the diagnosis led us to present this case.

**Case Report. History and exam.** An 11-year-old boy from an agricultural area of Yemen presented with progressive weakness of the left side over one year. He had no sensory symptoms. In addition to the grade 3/5 motor power found on examination, he had a positive Babinski sign on the left side.

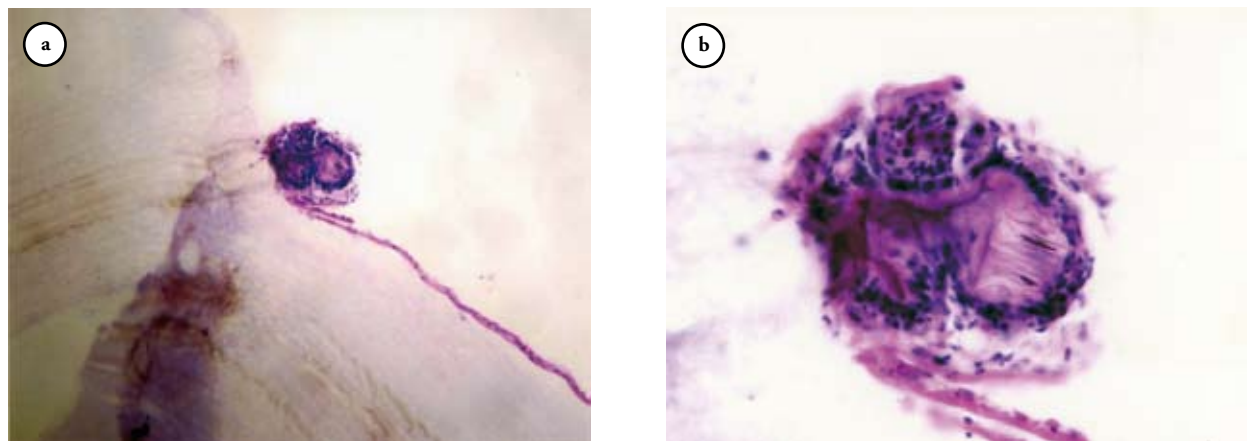
**Investigations.** A large isodense cyst was present on CT scan. An MRI of the brain was performed and showed a large (8 x 8 x 8 cm) spherical cyst isointense with CSF on T1-W and T2-W images. The right-sided cyst was intraparenchymal and had no solid components. It did not enhance upon gadolinium administration (Figure 1). It was not related to the arachnoid and was reported as a simple cyst. The cyst caused marked mass effect and early hydrocephalus.

A cerebral hydatid cyst was high on the differential diagnosis list, although he did not come from or live in an endemic area. Indirect hemagglutination test, indirect fluorescence antibody test, and enzyme-linked immunosorbent assay (ELISA) were all negative for echinococcus. Complete blood count revealed no eosinophilia. Chest x-ray and abdominal ultrasound were performed to look for systemic hydatidosis, and showed no pathology. The ELISA had been sent abroad as it was not available, and since all other investigations were negative, and did not confirm hydatid disease, the patient was started on Albendazole as a trial of medical treatment. His weakness was long standing, and the treatment trial, waiting for the ELISA results, was thought to help in determining the diagnosis as well. A follow up CT scan was obtained 4 weeks later but was comparable to the previous CT scan.

**Management.** Since all serological and other investigations supporting hydatid disease were negative, and after discussion with other colleagues, the possibility of a simple cyst was raised. We thus decided to take the patient to the operating theatre to aspirate and examine the cyst and possibly shunt it. A ventricular catheter was inserted through a burr hole and clear fluid was aspirated and sent for examination. The cyst was filled with hypertonic saline while waiting for the analysis. The analysis came back negative for scolices or other pathology. The cyst was aspirated and then, just before preparation for a cyst-peritoneal shunt, the cyst wall started to collapse and



**Figure 1** - Axial CT and MR images of the hydatid cyst. The images are typical of a cerebral hydatid cyst. a) Axial CT scan image showing the large intraparenchymal cyst on the right side with clear contents isodense with CSF. b) Axial T2W MR image showing the perfectly spherical thin walled homogenous cyst with contents similar to CSF. There is no communication with the ventricular system or subarachnoid space. c) Axial pre-gadolinium T1W images showing the low signal intensity rim. d) There is no enhancement of the rim upon gadolinium administration and no mural nodules differentiating it from neoplastic cysts.



**Figure 2** - Pathological examination of the cyst. a) Low power microscopic examination showing the cyst wall in the lower field and one of the scolices. b) High power magnification of one of the scolices. Note the hooklets on the right side.

gelatinous material appeared within. The burr hole was widened with a Kerrison rongeur to mimic a small craniectomy, and the collapsed cyst was removed in total, trying not to spill any of its gelatinous contents. The cavity was irrigated with hypertonic saline. Pathological gross and microscopic examination revealed hydatid cyst (Figure 2). His postoperative course was complicated by the formation of an abscess in the bed of surgery, treated with drainage, and then antibiotics for one month. He was kept on Albendazole in cycles for a total of 6 months. A CT scan 8 months after surgery showed no recurrence.

**Discussion.** Hydatid disease (echinococcosis) is a parasitic infection caused by the larval stage of the tapeworm *Echinococcus*.<sup>1</sup> Dogs and foxes are the definitive hosts that harbor adult tape worms in their intestines, whereas sheep, cattle, and rodents are intermediate hosts.<sup>2</sup> Humans are by accident intermediary blind hosts in the parasite cycle. The 2 main forms of the illness are caused by *Echinococcus granulosus* (*E. granulosus*) and, less frequently, *Echinococcus multilocularis* (*Echinococcus alveolaris*).<sup>3</sup> Hydatid disease is transferred to human adults by ingestion of the scolex, or eggs, that are present in foodstuffs, whereas in children infection commonly takes place via accidental contamination by direct contact with feces of dogs. The hydatid cyst reaches the brain after passing through the liver and the lungs, double obstacles, totaling 60% and 30% of the localization.<sup>4</sup> Only 1-2% of the cysts reach the brain.<sup>1,5</sup> The disorder caused by *E. granulosus* is most widespread in endemic areas such as the Mediterranean countries, South America, Australia, and New Zealand.<sup>2</sup> It affects mostly children, where the pediatric population constituted 73% of the patients in one series from Turkey, and the average age in another series was 7.2 years.<sup>4,6</sup> In a review of 276 cases of the literature, most patients presented with headache and vomiting, followed by motor weakness and seizures. The lesions were mostly located in the cerebral hemispheres with very few cases occurring in an intraventricular location.<sup>2</sup> Common CT, and MR findings include the presence of well-defined, smooth, thin-walled, spherical, homogenous cystic lesions. The cyst fluid appears similar to CSF. The cyst wall is isodense or hyperdense to brain tissue on unenhanced CT, and shows a rim of low signal intensity on both T1- and T2-weighted MR images.<sup>3</sup> There is usually no contrast enhancement and no edema on CT and MRI.<sup>1</sup> Calcification of the cyst wall is rare, being less than 1%.<sup>3</sup> The differential diagnosis of cerebral cystic echinococcosis includes abscess, cystic tumor, arachnoid cyst, and porencephalic cyst. The hydatid cyst can be differentiated from brain abscess and cystic tumor by the absence of significant rim enhancement, surrounding edema, and mural nodule. Arachnoid cysts

and porencephalic cysts are seldom as spherical and are not surrounded by brain tissue as in hydatid cysts.<sup>1,2</sup> On diffusion-weighted imaging (DWI), the hydatid cyst has the same intensity as arachnoid cysts. Arachnoid cysts are, however, extra-axial in location.<sup>7</sup> Serologic tests available to accomplish a preoperative diagnosis are indirect hemagglutination test, indirect fluorescence antibody test, and enzyme-linked immunosorbent assay (ELISA).<sup>2</sup> These tests are usually carried out after suspecting a cerebral hydatid cyst on CT or MRI. The sensitivity of these tests is limited, however, with the ELISA test permitting detection in up to 20% of the cases. Eosinophilia of peripheral blood may be of limited value. The frequent negativity of the hydatid cyst serology when the cerebral lesion is isolated is caused by the immunological sequestration of the cyst at the level of the central nervous system.<sup>4</sup> The CSF examination may reveal cyst wall membranes or scolices and hooklets of *E. granulosus*, but may not be performed often because of the mass effect caused by the cyst.<sup>8</sup> Although fewer than 20% may demonstrate other organ involvement, all patients with intracranial hydatidosis should undergo chest x-ray and abdominal ultrasound to reveal any systemic disease affecting the lung or the liver.<sup>9</sup> Despite all diagnostic measures, it may be impossible at times to arrive at a definite preoperative diagnosis.<sup>2</sup> The difficulty in establishing a preoperative diagnosis, especially in non-endemic areas, has led to accidental drainage of a cerebral hydatid cyst into the peritoneal cavity in one recent report.<sup>9</sup> The most reliable means of establishing the diagnosis are neuro-radiologic methods and pathohistologic examination (after removal).<sup>10</sup>

Treatment of the intracranial hydatid cyst is necessarily surgical and should be as radical as possible. Injection of formalin and evacuation of the cyst was the technique used until 1967.<sup>2</sup> After that, the Dowling technique has been used to remove the cyst in toto. It consists of performing a large craniotomy and corticectomy, meticulous manipulation throughout the procedure, avoiding electrocauterization, declining the head of the table, and performing hydraulic dissection to help intact cyst delivery.<sup>6</sup> The cyst ruptured at surgery in 28% of the cases in one series, and the cyst rupture was related to a frontal location.<sup>6</sup> In a review of the literature and reported cases, similar figures were found (63% intact cysts removed).<sup>2</sup> Cyst rupture into the subarachnoid space may lead to widespread dissemination followed by a severe anaphylactic response, in addition to a higher recurrence rate. In the case of intra-operative rupture, the operative site was systematically and repeatedly cleaned with a solution of 3% NaCl or 10% formaldehyde. The more recent cases were additionally treated with chemotherapy to obtain better results. This reduced the recurrence rate from 13% to 4%.<sup>2</sup> Albendazole at 10mg/kg/day is

recommended in cases of intra-operative rupture of the cysts and in case of recurrence. It is also recommended in inoperable cases of multifocal disease, or involving vital brain structures.<sup>11</sup> It is advised as presurgical treatment to reduce the size of a big cyst and prevent the possible spread of daughter cysts. Mebendazole may also be used to treat and try to prevent recurrence, although it seems less effective than Albendazole.<sup>2,12</sup>

In conclusion, hydatid disease of the brain is a rare disease in non-endemic areas that should be included in the differential diagnosis of cystic lesions of the brain, especially in a child coming from a farming region. The cyst may pose a diagnostic dilemma, especially as most serologic tests may be negative. It has a typical radiologic appearance, however, making CT scan and MRI the most reliable means of pre-operative diagnosis. This bears importance on the treatment strategy, where the cyst is best delivered in toto, avoiding intra-operative rupture.

## References

1. Tüzün M, Altunörs N, Arda İS, Hekimoğlu B. Cerebral hydatid disease CT and MR findings. *Clin Imaging* 2002; 26: 353-357.
2. Turgut M. Intracranial hydatidosis in Turkey: Its clinical presentation, diagnostic studies, surgical management, and outcome. A review of 276 cases. *Neurosurg Rev* 2001; 24: 200-208.
3. Tüzün M, Hekimoğlu B. Hydatid disease of the CNS: Imaging features. *AJR Am J Roentgenol* 1998; 171: 1497-1500.
4. Khaldi M, Mohamed S, Kallel J, Khouja N. Brain hydatidosis: report on 117 cases. *Childs Nerv Syst* 2000; 16: 765-769.
5. Kemaloğlu S, Ozkan U, Bükte Y, Acar M, Ceviz A. Growth rate of cerebral hydatid cyst, with a review of the literature. *Childs Nerv Syst* 2001; 17: 743-745.
6. Onal C, Unal F, Barlas O, Izgi N, Hepgul K, Turantan MI, et al. Long-term follow-up and results of thirty pediatric intracranial hydatid cysts: half a century of experience in the department of neurosurgery of the school of medicine at the University of Istanbul (1952-2001). *Pediatr Neurosurg* 2001; 35: 72-81.
7. Kitis O, Calli C, Yuntun N. Report of diffusion-weighted MRI in two cases with different hydatid disease. *Acta Radiol* 2004; 45: 85-87.
8. Sherwani RK, Abrari A, Jayrajpuri ZS, Srivastava VK. Intracranial hydatidosis. Report of a case diagnosed on cerebrospinal fluid cytology. *Acta Cytol* 2003; 47: 506-508.
9. Daskas N, Aggelopoulos E, Tzoufi M, Kosta P, Siamopoulou A, Argyropoulou MI. Accidental drainage of a cerebral hydatid cyst into the peritoneal cavity. *Pediatr Infect Dis J* 2004; 23: 685-686.
10. Talan-Hranilovic J, Sajko T, Negovetic L, Lupret V, Kalousek M. Cerebral cysticercosis and echinococcosis: a preoperative diagnostic dilemma. *Arch Med Res* 2002; 33: 590-594.
11. Kalaitzoglou I, Drevelengas A, Petridis A, Palladas P. Albendazole treatment of cerebral hydatid disease: evaluation of results with CT and MRI. *Neuroradiology* 1998; 40: 36-39.
12. Erdinciler P, Kaynar MY, Babuna O, Canbaz B. The role of mebendazole in the surgical treatment of central nervous system hydatid disease. *Br J Neurosurg* 1997; 11: 116-120.

### Related topics

Kadioglu HH, Malcok UA, Senguli G, Aydin IH. Alveolar hydatid disease of the spine causing paraplegia. *Neurosciences* 2005; 10: 180-182.

Tatli M, Guzel A, Altinors N. Large primary cerebral hydatid cysts in children. *Neurosciences* 2006; 11: 318-321.

Qureshi F, Maalbared N. Unusual presentation of echinococcal cysts. *Neurosciences* 2003; 8: 201-202.