

# Transanal prolapse of a ventriculoperitoneal shunt

Goksin Sengul, MD, Ali Akar, MD.

## ABSTRACT

تعتبر عملية تركيب صارفة بطينية صفاقية من بين معظم العمليات تكررًا في علاج استسقاء الدماغ. على الرغم من ملائمة التجويف البريتوني لامتناس سائل النخاع الشوكي. والمضاعفات المتعددة ذات الصلة بالصارفة التي تميل إلى تطوير هذه المنطقة. يعتبر حدوث قسرة الصارفة البطينية الصفاقية لحافة الشرج من المضاعفات النادرة نتيجة إلى ثقب الأمعاء بسبب قسرات الصارفة البروتينية. يعتبر تشخيص هذه الحالة مبني على الحدث نفسه. في التقرير، تم تركيب قسرة للصارفة لمريض رضيع عبر الشرج مع عدم وجود علامات في البطن أو في الجهاز العصبي المركزي.

Ventriculoperitoneal shunt application is among the most frequently performed procedure in the treatment of hydrocephalus. Despite the peritoneal cavity being convenient for absorption of cerebrospinal fluid, multiple complications related to the shunt tend to develop in this area. Anal migration of ventriculoperitoneal shunt catheter is seen as a rare complication due to the intestinal perforation caused by peritoneal shunt catheters. The diagnosis of this condition is self-evident. In this report, an infant whose shunt catheter protrudes through the anus with no abdominal or CNS signs is presented.

*Neurosciences 2008; Vol. 13 (2): 174-175*

*From the Department of Neurosurgery, Medical School, Ataturk University, Erzurum, Turkey.*

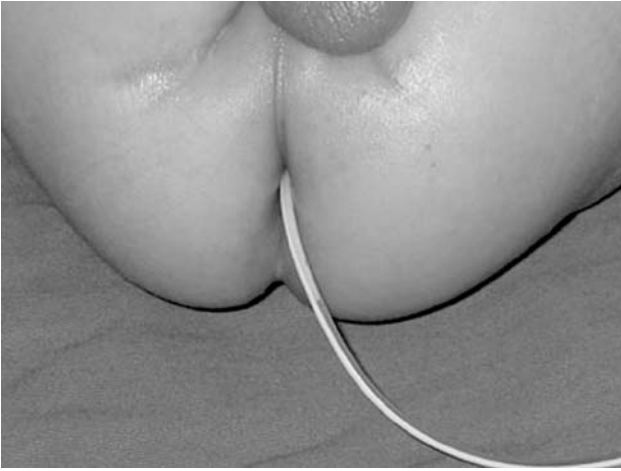
*Received 2nd July 2007. Accepted 15th September 2007.*

*Address correspondence and reprint request to: Dr. Goksin Sengul, Department of Neurosurgery, Medical School, Ataturk University, 25070, Yenisehir, Erzurum, Turkey. Tel. +90 (442) 3166333 Ext. 2085. Fax: +90 (442) 3166340. E-mail: goksinsengul@gmail.com*

Intestinal perforation by peritoneal catheters is a rare but devastating complication. Anal extrusion is present in only a minority of patients.<sup>1,2</sup> Although this complication has been previously reported,<sup>1-8</sup> it remains a rare event. The objective for presenting this additional case is to discuss the pathogenesis and treatment of this condition in light of the literature.

**Case Report.** A 4-month-old boy was brought to our department because of prolapse of ventriculoperitoneal shunt catheter tip from the anus. He had been operated for lumbar myelomeningocele and had undergone ventriculoperitoneal shunt for hydrocephalus in the neonatal period. His mother mentioned that she noticed the anal prolapse of the catheter tip while she was cleaning the infant's perianal region 30 minutes previously, but did not mention any gastrointestinal and neurological changes. On physical examination, there were no signs of peritonitis or meningitis and vital parameters were normal. The tip of the catheter was lying 10 cm from the anal verge and clear CSF was dripping from it (Figure 1). He was hospitalized, vancomycin plus cefotaxime was initiated and then taken for surgery. The shunt tube was extracted at the chest wall, and the distal part was removed from the anus. Cerebrospinal fluid samples were taken for laboratory examination. On laboratory examination, hemoglobin was 14 g/dl (range 13-17 g/dl) and leukocyte count was 4700/mm<sup>3</sup> (range 4000-10000/mm<sup>3</sup>). On CSF analysis, protein was 35 mg/dl (range 15-40 mg/dl), glucose was 38 mg/dl (range 40-75 mg/dl) and no leukocyte was seen on microscopic examination. No bacteria were cultured from the CSF and the tip of catheter. Abdominal ultrasound examination did not suggest any evidence of peritonitis. On the 3rd day of admission, the entire shunt was removed and a new shunt was inserted. The postoperative course was uneventful.

**Discussion.** Various mechanisms have been suggested regarding the pathogenesis of perforation including foreign body reaction, pressure necrosis of the intestinal wall by the tube, and a stiff end of the shunt tube causing perforation. Factors predisposing to intestinal perforation of the abdominal end may include the length of the abdominal catheter, surgical trauma, and infection leading to local adhesions.<sup>5,6</sup> Two reasons are suggested for the frequent development of intestinal perforation due to distal shunt catheter in children. The first one is that children have a weak intestinal musculature, which can easily be perforated by hard-tipped catheters, and the second is that younger patients have stronger intestinal peristaltic activity



**Figure 1** - Photograph showing the ventriculoperitoneal shunt prolapsing through the anus.

when compared to older patients.<sup>6</sup> We use shunts with a proximal valve, and the length of the distal catheter is shortened as needed to fit the patient's prospective stature, lateral slits are added along the last 10 cm of the catheter to provide extra drainage. We always insert the peritoneal catheter under direct vision and never with the trocar technique. Based on the clinical findings of our case, we think that the most probable reason is the weakness of intestinal musculature. Many cases are recognized only during shunt revision. Seeing protrusion of the peritoneal catheter from the anus makes the diagnosis definite, as in our case. The method of shunt removal depends upon the clinical condition of the patient. If the abdominal examination does not indicate peritonitis, percutaneous removal of the catheter can be performed since no complication has occurred. In the presence of shunt protrusion from the anus, the peritoneal catheter can be removed by pulling it through the anus as was carried out in our case. The peranal

approach seems practical as it eliminates the possible risk of peritoneal and shunt-track contamination.<sup>8</sup> Removal of the peritoneal catheter proximally can lead to spread of infection to the CNS. Many methods have been suggested for prevention of this complication. There have been suggestions to anchor the distal end of the peritoneal tube to the peritoneum in children. This simple method does not add much to the operation time, and has prevented shunt-tube migration in the group studied.<sup>3</sup> Other suggestions include division of the catheter, and this cut should be distal to the end of the sharp wire contained in it, which otherwise will protrude. However, a larger group will need to be studied to see whether any of these needs to be carried out on a routine basis.

## References

1. Ghritlaharey RK, Budhwani KS, Shrivastava DK, Gupta G, Kushwaha AS, Chanchlani R, et al. Trans-anal protrusion of ventriculo-peritoneal shunt catheter with silent bowel perforation: report of ten cases in children. *Pediatr Surg Int* 2007; 23: 575-580.
2. Vinchon M, Baroncini M, Laurent T, Patrick D. Bowel perforation caused by peritoneal shunt catheters: diagnosis and treatment. *Neurosurgery* 2006; 58 (1 Suppl): ONS76-ONS82.
3. Sharma A, Pandey AK, Diyar B, Shah S, Sayal P. Management of ventriculo-peritoneal shunt protruding through the anus. *Indian J Surg* 2006; 68: 173.
4. Akcora B, Serarslan Y, Sangun O. Bowel perforation and transanal protrusion of a ventriculoperitoneal shunt catheter. *Pediatr Neurosurg* 2006; 42: 129-131.
5. Gupta SK, Jaiswal AK, Kumar S. Ventriculoperitoneal shunt catheter masquerading as ascariasis. *J Clin Neurosci* 2005; 12: 966-967.
6. Yilmaz N, Kiyimaz N, Yilmaz C, Caksen H, Yuca SA. Anal protrusion of ventriculo-peritoneal shunt catheter: report of two infants. *J Pediatr Neurol* 2004; 2: 2412-2414.
7. Caksen H, Kiyimaz N, Odabas D, Tuncer O, Atas B. Anal protrusion of ventriculo-peritoneal shunt catheter in an infant. *Brain Dev* 2003; 25: 146-147.
8. Digray NC, Thappa DR, Arora M, Mengi Y, Goswamy HL. Silent bowel perforation and transanal prolapse of a ventriculoperitoneal shunt. *Pediatr Surg Int* 2000; 16: 94-95.

## NEW PEER REVIEWERS

Join our team of expert peer reviewers for the Neurosciences Journal by sending an enquiry and summarized CV to [info@smj.org.sa](mailto:info@smj.org.sa). Note that NSJ reviewers, whose reviews are returned on time and are judged satisfactory by the Editors, may receive 1 CME credit per review, with a maximum of 5 credits per year, from the Saudi Council for Health Specialties.