

# Neuroprotective effects of selenium and ginkgo biloba extract (EGb761) against ischemia and reperfusion injury in rat brain

*Guven Erbil, MD, PhD, Seda Ozbal, MD, PhD, Ulker Sonmez, MD, PhD, Cetin Pekcetin, VMD, PhD, Kazim Tugyan, MD, PhD, Alper Bagriyanik, MD, PhD, Candan Ozogul, PhD.*

## ABSTRACT

**الأهداف:** تحديد الآثار الوقائية العصبية لمستخلص جينكجو بيلوبا (EGb761) وسيلينيوم (Se) وإتحاد هذه العوامل على إصابة نقص التروية / إعادة التسريب I/R العابرة للدماغ في نموذج الجرذ.

**الطريقة:** أجريت هذه الدراسة التجريبية في مختبر أبحاث الحيوان بجامعة دو كوز إيلول - تركيا في عام 2006م. تم إجراء إصابة الدماغ بنقص التروية / إعادة التسريب المحرض I/R بواسطة تقنية سد الشريان السباتي الأيمن لمدة 45 دقيقة على 50 جرذ. وبعد ذلك تمت معالجتهم بمستخلص (EGb761) بمقدار (50mg/kg/day, ip)، وسالينيوم (Se) بمقدار (0.625mg/kg, ip)، لوحدة أو مع اتحاد كلا العاملين لمدة 14 يوما بعد الجراحة. تم قياس ديسموتيس فوق التأكسد وأنشطة قبل التأكسد للجوتين في أنسجة قرني آمون في الدماغ من 25 حيوان. تم القيام بالفحوصات النسيجية المرضية تحت الميكروسكوب (المجهر) الضوئي والإلكتروني من باقي الحيوانات.

**النتائج:** تقترح النتيجة أن لدى (EGb761) أثر وقائي عصبي ضد الإصابة بنقص التروية / إعادة التسريب المحرض I/R لدى دماغ الجرذ، والتي تم مقارنتها مع عنصر ساليينيوم (Se). ولكن اتحاد (EGb761) وسالينيوم (Se) لايقوم بالمزيد من الحماية من الإصابة العصبية عند مقارنة استعمال كل العاملان على حده.

**خاتمة:** تقترح دراستنا أن لدى المعالجة بمستخلص (EGb761) وسالينيوم (Se) وإتحاده مع (EGb761) آثار وقائية عصبية ملحوظة في إصابة الدماغ بنقص التروية / إعادة التسريب I/R في الجرذان عن طريق كبت الجهد المؤكسد.

**Objectives:** To determine the neuroprotective effects of Ginkgo biloba extract (EGb761) and Selenium (Se), and the combination of these agents on ischemia/reperfusion (I/R) injury in a rat model of transient global cerebral I/R.

**Methods:** This experimental study took place in the Animal Research Laboratory at Dokuz Eylul

University, Izmir, Turkey in the year 2006. Fifty rats were subjected to cerebral I/R induced by right carotid artery occlusion technique for a duration of 45 minutes, and then were treated with EGb761 (50 mg/kg/day, ip) and Se (0.625 mg/kg, ip), alone or in combination for 14 days after surgery. Superoxide dismutase, and glutathione peroxidase activities were measured in the hippocampal tissues from 25 animals. Histopathological examinations were also carried out under light and electron microscopy from the rest of animals.

**Results:** The results suggest that EGb761 has a potent neuroprotective effect against cerebral I/R induced injury in rat brain that is comparable with that of Se. However, the combined use of EGb761 and Se does not further protect from neuronal injury when compared with the use of both agents alone.

**Discussion:** Our results suggest that administration of EGb761, Se and its combination with EGb761 have significant neuroprotective effects on I/R injury in rats via suppression of oxidative stress.

*Neurosciences 2008; Vol. 13 (3): 233-238*

*From the Department of Histology and Embryology, School of Medicine, Dokuz Eylul University Inciralti, Izmir, Turkey*

*Received 2nd August 2007. Accepted 3rd February 2008.*

*Address correspondence and reprint request to: Assist. Prof. Guven Erbil, Dokuz Eylul Universitesi Tıp Fakultesi Histoloji ve Embriyoloji A.D. Inciralti, TR-35340 Izmir, Turkey. Tel. +90 (532) 6777949. Fax. +90 (232) 2590541. E-mail address: guven.erbil@deu.edu.tr*

**H**uman cerebral ischemia frequently results from thrombosis, vascular spasm, and changes in intracranial pressure. It initiates a series of reactions from cell dysfunction to cell death leading to cell energy depletion and toxic metabolite accumulation.<sup>1</sup> Whenever the CNS is damaged it undergoes an injury response, usually called reactive gliosis, or glial scarring. The response is broadly the same whatever the source of the injury, although the details vary somewhat with different types of pathology. Glial responses may be beneficial for

the injured CNS, however, excessive astrogliosis may be detrimental and contribute to neuronal damage.<sup>2</sup> It is well known that ischemia/reperfusion (I/R) induces neuronal injury through several pathophysiological mechanisms,<sup>3-5</sup> including intracellular calcium overload and free radical production, which finally trigger the apoptosis. Although reactive oxygen species (ROS) are essential to many normal biological processes and are produced physiologically, excessive production and gathering of ROS (or impairment of the antioxidant systems) can become hazardous to cells and tissues.<sup>6</sup> The brain is particularly susceptible to hypo-glucose and hypoxia induced by I/R and significant neuronal injuries, during which large amounts of free radicals are released. Cerebral blood flow is reduced in the brain regions during cerebral ischemia and results in the increased production of ROS. Following this, spontaneous or thrombolytic reperfusion can increase the oxygen and ROS levels.<sup>7,8</sup> Pharmacological modification of oxidative damage may protect against ischemia. An extract of the antioxidant agent Ginkgo biloba (EGb761), makes the cell membrane structure stable and speeds free radical scavenging. It also activates sodium (Na<sup>+</sup>), potassium (K<sup>+</sup>) and adenosine triphosphate (ATP) enzymes. In experimental models of brain ischemia and hypoxia, EGb761 was reported to increase cerebral blood flow considerably, and modulate neurotransmitter systems like serotonin, noradrenalin, dopamine, and acetylcholine. The EGb761 causes the consequences above by increasing oxygen consumption, glucose uptake, and intracellular respiration.<sup>9-15</sup> Selenium (Se) is taken in very low levels by diet and protects cells against free radicals and peroxidases induced by oxidative damage. In the brain, several selenoproteins are expressed. Among those, the antioxidant effect of selenoprotein P on neuronal survival was reported.<sup>16-18</sup> However, its role in post-ischemic neuron death could not be explained.<sup>7</sup> In the present study, we investigated the neuroprotective effects of EGb761 and Se, both alone and in combination, in a rat model of transient global cerebral ischemia.

**Methods.** Fifty Wistar albino healthy male rats weighing 275±25 gr were used in this study in 2006. Animals were housed under standard conditions in the Animal Research Laboratory at Dokuz Eylul University Medical Faculty, Izmir, Turkey. The study protocol was approved by the Animal Research Ethical Committee of Dokuz Eylul University. The rats were allowed free access to water and standard laboratory chow, maintained on a 12 hour light; 12 hour dark cycle and housed under controlled conditions of temperature (20±2°C) and humidity. During the surgical procedures, anesthesia was induced and maintained with intraperitoneal ketamine

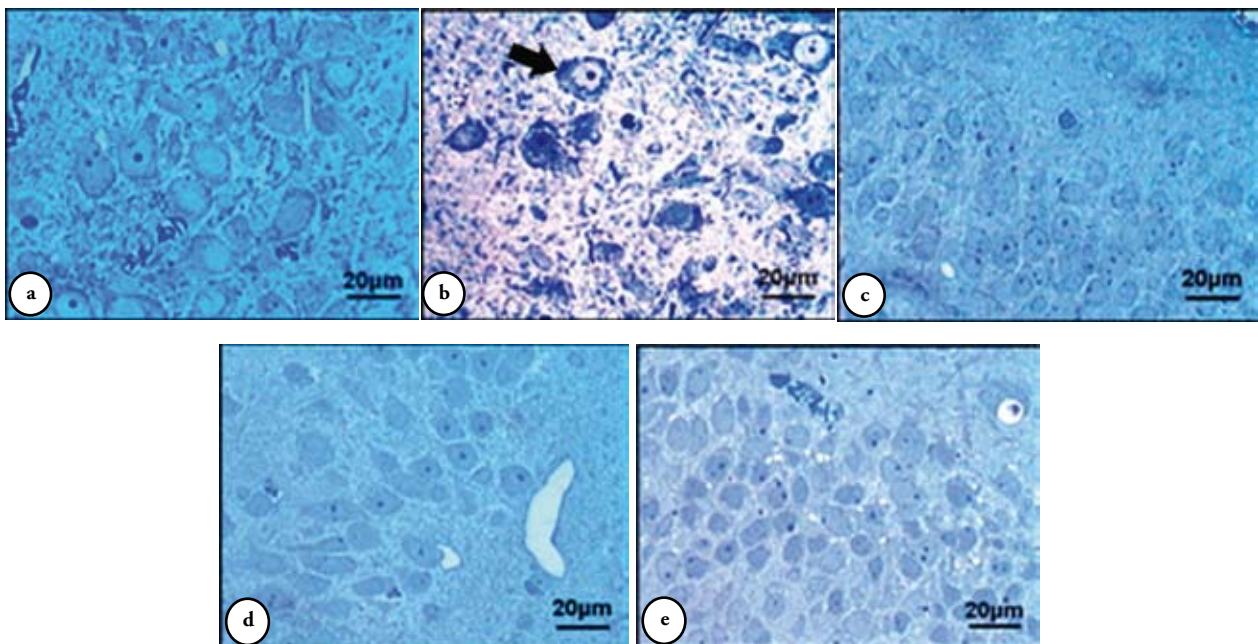
(50 mg/kg) and xylazine (6 mg/kg), as needed. No animal received hemodynamic or ventilatory support. During the surgical procedures, the body temperature was maintained with a water-filled heating pad. Animals were randomly allocated into 5 experimental groups, each of 10 rats. The right common carotid artery (CCA) was exposed with anteromedial cutaneous and subcutaneous incision by neck hyperextension. In the group one (n=10), sham-operated rats, the neck incision was left open for 45 minutes, but the right CCA was not occluded. In the group 2 (n=10) (I/R group), the right CCA was occluded with aneurysm clips for 45 minutes followed by 14 days reperfusion period, and given equal volume of normal saline intraperitoneally during the reperfusion period. The group 3 animals (n=10) (EGb761 group) received 50 mg/kg/day EGb761 (Schwabe Extracta, Germany), and the group 4 animals (n=10) (Se group) received 0.625 mg/kg/day Se (Merck, USA) after the onset of ischemia detailed above for group 2. In group 5 (n=10) (combined EGb761 and Se group), a combination of EGb761 and Se (as above) was given in the same fashion. At the end of 14 days, 25 animals were killed, 5 animals from each group, by decapitation under ether anesthesia. Brains were removed, and hippocampal tissues were separated on an ice-cold surface. Following these procedures, superoxide dismutase (SOD) and glutathione peroxidase (GPx) activities were measured in the hippocampal tissues. The rest of animals were used for histopathological evaluation under light and electron microscopy. The animals in each group were perfused by glutaraldehyde under ether anesthesia, 14 days after reperfusion injury. After decapitation, the right hemispheres of the brains were stored in the glutaraldehyde overnight at +4°C. Epoxy resin embedded sections (1-µm thickness) were stained with toluidine blue. Preparations were examined with a light microscope (Olympus BH-2 Tokyo, Japan) and images transferred to computer using a high-resolution camera (JVC TK-890-E, Japan) and Aver TV Studio (Version 4.21.0.0 Software, Aver Media Technologies, Inc.) Video Capture. Tissues for electron microscopic analyses were stained with uranyl acetate and lead citrate and examined under a Carl Zeiss EM 900 electron microscope. The histologist was blinded to the animal groups, and the procedure was conducted in a blinded fashion. For antioxidant enzyme examination, hippocampal tissue samples were homogenized as described by Carillo et al.<sup>19</sup> Homogenates were centrifuged at 4°C (Sigma Laborzentrifugen, Germany). Supernatants were obtained and kept at -70°C until examination for GPx and SOD activities. Hippocampal GPx activities were determined with RANSEL kit (Randox Labs, Crumlin, UK) at 340 nm and SOD activities were determined

with RANSOD kit at 505 nm. Tissue total protein concentration was determined with RANDOX TOTAL PROTEIN kit at 600 nm. Tissue enzyme measurements were examined by triplication. Results were described as units/mg protein.

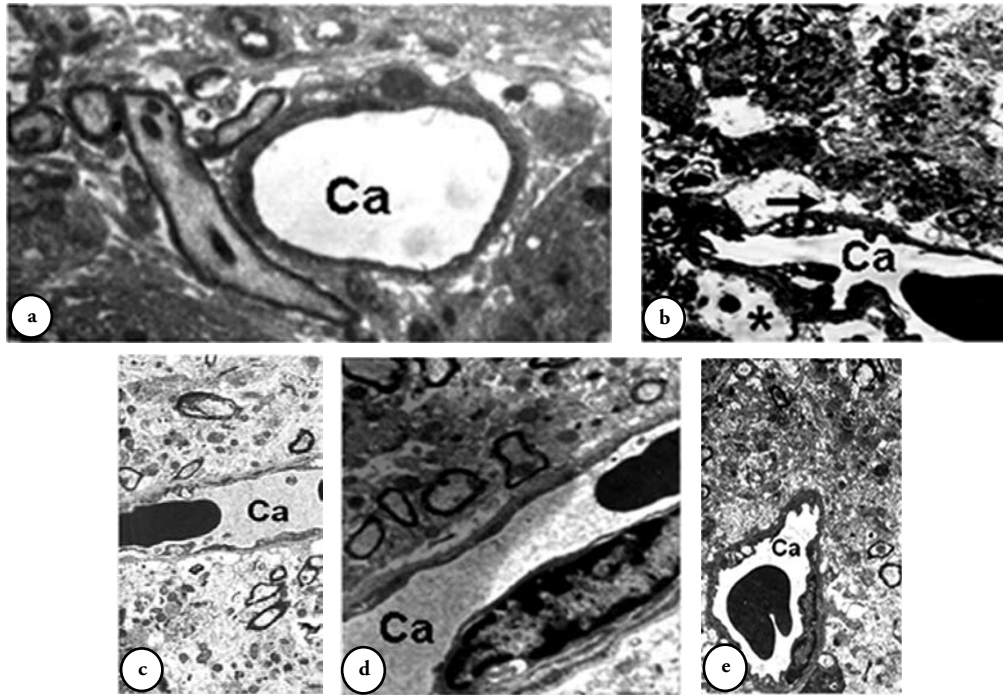
Data were analyzed using a SPSS 11.0 for Windows program on a computer. All data were expressed as mean  $\pm$  SD. One-way ANOVA and Mann Whitney U tests were used for data analysis, followed by the Tukey test for post hoc analysis. A  $p$  value  $<0.05$  was considered to be statistically significant.

**Results.** Under light microscopy, in the sham group, the neurons in the CA1 have smooth contours. Their nucleus and nucleolus view were normal. The glial cells were normal. Neuropil was compactly seen (Figure 1a). Hypervascularization was seen in only one subject, and not considered meaningful. In the I/R groups, in the hippocampal CA1 area pericellular and perivascular edema were observed. The neurons were shrunk, which gave a sparse cell impression. Because of the invaginations on cell and nucleus membranes the borders of the cells were vague, vacuolizations, nuclear condensation was determined in some neurons cytoplasm. Microscopically the increase in glial cell number attracted attention. The neuropil had lost its compact view, different from the sham group (Figure 1b). In the groups treated with

Gingko Biloba and Se, and in the groups treated with both antioxidants had the same findings as the sham group findings. The veins of the tissue, neuropil, neurons, and glial cells were in normal view (Figures 1c, d, & e). Electron microscopic results in group one (sham); CA1 pyramidal neurons had round and regular nuclei with evenly distributed chromatin and clear nucleoli. In the cytoplasm well-developed rough endoplasmic reticulum (RER), the polyribosomes formed characteristic rosettes. Mitochondria had electron dense matrix. The neuropil was compact with synapses and neuronal or glial processes (Figure 2a). In the I/R group, neuropil heterogeneity was thought to arise from cerebral spongiosis, especially from edematous (hydropic) astrocyte processes in perivascular regions. Presence of electron dense neurons was proved with electron microscopy. Mitochondrial crystalalysis, RER dilatation, and degenerative vacuoles were detected especially in those dense neurons. Glial cells increased in number were observed to be organized at the periphery of those neurons and edematous in perivascular regions (Figure 2b). In the EGb761 group, histopathologic findings were compatible with the sham group. Cell contours of neurons were regular, cytoplasm was electron pale, nuclear chromatin distribution, mitochondria, and RER cisternae were normal. Neuropil had compact morphology in all regions (Figure 2c). In the Se and the



**Figure 1** - Contours of pyramidal neurons are proper, nuclei, nucleoli, neuropil, and glial cells seem normal in sham group hippocampal CA1 region (a). Neuron contours are irregular, and neuron number decreases. Perivascular and pericellular edema, nuclear membrane irregularities (black arrow) and increased glial cells when compared to sham group, and non compact neuropil is seen in I and R groups (b). Neuron bodies, nuclei, and nucleoli have normal appearance and neuropils are compact in Ginkgo biloba extract (Egb761) (c), selenium (Se) (d) and Egb761+Se (e) treated groups. Toluidine-Blue, each bar represents 20  $\mu$ m.



**Figure 2** - In sham group capillary (Ca), perivascular area and neuropil are regular (a). Ischemia and reperfusion group; show perivascular edema (black arrow), neuropilar spongiosis compared to sham group (b). In all treated groups, Ginkgo biloba extract (EGb761) applied group (c), Selenium (Se) treated group (d) and EGb761 + Se given group (e) compact structure of neuropil, regular pericapillary view in CA1 region and treated groups show regular structures as in the sham group. Uranyl Acetate-Lead Citrate x 9000.

**Table 1** - The effects of EGb761 and/or Se treatment on GPx and SOD activities in rat hippocampus after IRI.

Groups	Sham	I and R	EGb761	Se	EGb761 + Se
GPx (U/mg protein) ± SEM	0.476 ± 0.05	0.160 ± 0.04*	0.350 ± 0.05	0.472 ± 0.03	0.460 ± 0.03
SOD (U/mg protein) ± SEM	1.036 ± 0.10	0.734 ± 0.13**	1.376 ± 0.10	1.426 ± 0.22	1.492 ± 0.20

EGb761 - Ginkgo biloba extract, Se - selenium, GPx - glutathione peroxidase, SOD - superoxide dismutase, IRI - ischemia and reperfusion injury, \*Hippocampus GPx activities in sham group were significantly higher than IR ( $p=0.001$ ) versus EGb761 ( $p=0.008$ ) groups, while IR group was significantly lower than Se ( $p=0.001$ ) versus EGb761+Se ( $p=0.001$ ) groups. Hippocampal GPx levels were significantly lower in EGb 761 ( $p=0.003$ ) treated group in compare to Se ( $p<0.01$ ) versus EGb761+Se ( $p=0.015$ ) treated groups, \*\*Hippocampus SOD activities in IR group were significantly lower than Se ( $p=0.18$ ) versus EGb761+Se ( $p=0.025$ ) treated groups. No significant difference was found between Se versus EGb761+Se treated groups

combined EGb761 and Se treated groups, the findings were compatible ultrastructurally with those in the sham and ginkgo biloba groups (Figures 2d & e). The hippocampal tissue SOD and GPx activities are shown in Table 1. The SOD and GPx activities in I/R group were much lower than those in the sham group (Table 1), and EGb761, Se and combined EGb761 and Se treatment significantly enhanced the SOD activity. Although the highest SOD activity was found in the combined treatment group, there were no statistically significant differences between this and that of the EGb761 and Se treatment groups.

**Discussion.** Ischemia and reperfusion caused alterations in SOD and GPx activities, substantial

reactive gliosis, and neuronal damage in hippocampal CA1 region. Daily administration of 0.625 mg/kg Se and 50 mg/kg EGb761 and 0.625mg/kg Se combination for 14 days after ischemia provided an increase in SOD and GPx activity, which is compatible with the sham group and preserved against I/R induced reactive gliosis neuronal damage in the hippocampal CA1 region. It is well established that astrocytes undergo reactive responses following various kinds of injury or in neurodegenerative processes. This reactive process, known as astrogliosis, or reactive gliosis, is characterized by cellular hypertrophy, hyperplasia, and increased glial filament expression, such as glial fibrillary acidic protein. Glial responses may be beneficial for the injured CNS; however, excessive astrogliosis may be detrimental and

can contribute to neuronal damage.<sup>2</sup> For example, reactive gliosis with extracellular matrix and basement membrane contributes to scar-formation at the lesion site. It is likely that early inhibition of proliferating reactive astrocytes would decrease the production, and later accumulation of molecules involved in glial scar formation.<sup>20</sup> The scar containing reactive astrocytes can form a local biochemical and physical barrier that hampers axonal regeneration and the reestablishment of circuitry after injuries in the adult mammalian CNS.<sup>21</sup> In this regard, we suppose that if excessive reactive gliosis can be moderated, a niche environment suitable for neuronal regeneration could be achieved.

Findings to date, show that reactive oxygen radicals are involved in brain injuries such as cerebral ischemia and reperfusion. It is well known that in focal or global cerebral ischemia, cerebral blood flow (CBF) is decreased in brain regions that are supplied with oxygen by the occluded vessels. Subsequently, spontaneous or thrombolytic reperfusion during reoxygenation provides oxygen as a substrate for numerous enzymatic oxidation reactions in the cytosolic compartments or subcellular organelles and mitochondria.<sup>7</sup> It has been demonstrated that approximately 2-5% of the electron flow in isolated brain mitochondria produces superoxide anion radicals ( $O_2^-$ ) and hydrogen peroxide ( $H_2O_2$ ).<sup>22</sup> These constantly produced ROS are scavenged by SOD, GPx, and catalase. Other small molecular antioxidants, including glutathione (GSH), ascorbic acid, and  $\alpha$ -tocopherol, are also involved in the detoxification of free radicals. During reperfusion, these endogenous antioxidative defenses are likely to be perturbed as a result of overproduction of oxygen radicals by cytosolic prooxidant enzymes and mitochondria, inactivation of detoxification systems, consumption of antioxidants, and failure to adequately replenish antioxidants in ischemic brain tissue. It has been demonstrated in numerous studies that ROS are directly involved in oxidative damage with cellular macromolecules such as lipids, proteins, and nucleic acids in ischemic tissues, which lead to cell death. Recent studies have provided evidence that indirect signaling pathways by ROS can also cause cellular damage and death in cerebral ischemia and reperfusion.<sup>22</sup>

Previous studies showed that the extract of Ginkgo biloba, and some of its constituents, such as ginkgolide B and bilobalide, protected cultured neurons against apoptotic and excitotoxic damage and reduced the infarct volume after focal cerebral ischemia in mice and rats.<sup>23</sup> Additionally, it was reported that hypoxia/reoxygenation,  $H_2O_2$  and high concentration of L-glutamate impaired the astrocytes' response to exogenous L-glutamate, and then bidirectional communication between astrocytes and neurons could not take place. It was concluded that EGb761 could improve the

abnormal responses and maintain the normal function of the astroglial network.<sup>24</sup> The present study indicates that treatment with 50 mg/kg EGb761 (ip) provided an increase in SOD and GPx activity and moderated I/R induced neuronal damage in the hippocampal CA1 region. Electron microscopic findings also supported the neuroprotective effects of EGb761 in this model. We supposed that positive histopathological findings in EGb761 treatment might be due to its potent antioxidant activity, although it has some other major biochemical/pharmacological activities, such as anti-PAF activity, endothelium-derived relaxing factor stimulation, increasing ATP, and anti-inflammatory effects.

Selenium is an integral component of GPx and plays a vital role in protecting aerobic organisms from oxidative and nitrosative tissue damage. In addition to its known effect on GPx, Se is noted to enhance the  $H_2O_2$  scavenging activity of GPx.<sup>25</sup> Also, it may directly neutralize peroxynitrite, which is a strong oxidant and an oxidative and nitrosative stress mediator.<sup>26</sup> It has been demonstrated that Se has a protective effect in I/R injury in many tissues, including neural tissue.<sup>27</sup> Data in the present study show that treatment with Se following I/R injury improved antioxidant enzyme activities, preserved neuronal damage and moderated I/R induced reactive gliosis in the CA1 region of hippocampus in rats. Electron microscopic findings also showed that treatment with Se, with or without EGb761, significantly attenuated tissue damage in this model. A previous study indicated that combined pretreatment of EGb761 and selegiline produced significant neuroprotective effects via suppression of oxidative stress and mitochondrial dysfunction without affecting neurological function.<sup>28</sup> However, in our study, combined treatment of Se with EGB761 did not have an additive effect on antioxidant enzymes activities, neuronal survival, and reactive gliosis when compared with other treatment groups. Contradictory findings might arise from the differences between animal models in 2 studies.

In conclusion, our results suggest that administration of EGb761, Se and its combination with EGb761 have significant neuroprotective effects on I/R in rats via suppression of oxidative stress. The effects of these 2 substances were compared in this model, and the comparable antioxidant property of EGb761 to those of Se was demonstrated. Additionally, combined administration of EGb761 and Se did not have any advantage over administration of Se alone in our model. We suppose, using unbiased stereological cell counting techniques at hippocampal tissue could provide additional information in the present study. However, because of technical limitations we could not realize this method in our study. Further studies,

providing information on other possible mechanisms of neuroprotective effect of these antioxidant agents and their modulatory roles against cerebral ischemic damage on the basis of biochemical, histopathological, and behavioral levels are needed.

## References

1. Carden DL, Granger DN. Pathophysiology of ischemia-reperfusion injury. *J Pathol* 2000; 190: 255-266.
2. Zawadzka M, Kaminska B. Immunosuppressant FK506 affects multiple signaling pathways and modulates gene expression in astrocytes. *Mol Cell Neurosci* 2003; 22: 202-209.
3. Gwag BJ, Lobner D, Koh JY, Wie MB, Choi DW. Blockade of glutamate receptors unmasks neuronal apoptosis after oxygen-glucose deprivation in vitro. *Neuroscience* 1995; 68: 615-619.
4. Chen CJ, Cheng FC, Liao SL. Effect of naloxone on lactate, pyruvate metabolism and antioxidant enzyme activity in rat cerebral ischemia/reperfusion. *Neurosci Lett* 2000; 287: 113-116.
5. Traystman KT, Kirsch JR, Koehler RC. Oxygen radical mechanisms of brain injury following ischemia and reperfusion. *J Appl Phys* 1991; 71: 1185-1195.
6. Sarsilmaz M, Songur A, Kus I, Ozyurt B, Gulec M, Sogut S, et al. The regulatory role of dietary omega-3 essential fatty acids on oxidant/antioxidant balance in rat hippocampus. *Neurosci Res Commun* 2003; 33: 114-123.
7. Chan PH. Reactive oxygen radicals in signaling and damage in the ischemic brain. *J Cerebr Blood F Met* 2001; 21: 2-14.
8. Irmak MK, Fadillioglu E, Sogut S, Erdogan H, Gulec M, Ozer M, et al. Effects of caffeic acid phenethyl ester and alpha-tocopherol on reperfusion injury in rat brain. *Cell Biochem Funct* 2003; 21: 283-289.
9. Calapai G, Crupi A, Firenzuoli F, Marciano MC, Squadrito F, Inferred G, et al. Neuroprotective effects of ginkgo biloba extract in brain ischemia are mediated by inhibition of nitric oxide synthesis. *Life Sci* 2000; 67: 2673-2683.
10. Chung HS, Haris A, Kristinsson JK, Ciulla TA, Kagemann C, Ritch R. Ginkgo biloba extract increases ocular blood flow velocity. *J Ocul Pharmacol Ther* 1999; 15: 233-240.
11. Curtis-Prior P, Vere D, Fray P. Therapeutic value of Ginkgo biloba in reducing symptoms of decline in mental function. *J Pharm Pharmacol* 1999; 51: 535-541.
12. Li AL, Shi YD, Landsmann B, Schanowski-Bouvier P, Dikta G, Bauer U, et al. Hemorheology and walking of peripheral arterial occlusive diseases patients during treatment with ginkgo biloba extract. *Zhongguo Yao Li Xue Bao* 1998; 19: 417-421.
13. Logani S, Cheng MC, Tran T, Le T, Rafa RB. Actions of ginkgo biloba related to potential utility for the treatment of conditions involving cerebral hypoxia. *Life Sci* 2000; 67: 1389-1396.
14. MacLennan KM, Darlington CL, Smith PF. The CNS effects of ginkgo biloba extracts and ginkgolide. *Prog Neurobiol* 2002; 67: 235-257.
15. Unal I, Gursoy-Ozdemir Y, Bolay H, Soylemezoglu F, Saribas O, Dalkara T. Chronic daily administration of selegiline and Egb 761 increases brain's resistance to ischemia in mice. *Brain Res* 2001; 917: 174-181.
16. Chen J, Berry MJ. Selenium and selenoproteins in the brain and brain diseases. *J Neurochem* 2003; 86: 1-12.
17. Santamara A, Sanchez RS, Roman BV, Lopez DS, Hernandez JV, Arzate SG, et al. Protective effects of the antioxidant selenium on quinolinic acid-induced neurotoxicity in rats: in vitro and in vivo studies. *J Neurochem* 2003; 86: 479-488.
18. Mostert V. Selenoprotein P: properties, functions, and regulation. *Arch Biochem Biophys* 2000; 15: 376: 433-438.
19. Carrillo MC, Kanai S, Nokubo M, Kitani K. Deprenyl induces activities of both superoxide dismutase and catalase but not of glutathione peroxidase in the striatum of young male rats. *Life Sci* 1991; 48: 517-521.
20. Di Giovanni S, Movsesyan V, Ahmed F, Cernak I, Schinelli S, Stoica B, et al. Cell cycle inhibition provides neuroprotection and reduces glial proliferation and scar formation after traumatic brain injury. *P Natl Acad Sci USA* 2005; 102: 8333-8338.
21. Davies SJ, Goucher DR, Doller C, Silver J. Robust regeneration of adult sensory axons in degenerating white matter of the adult rat spinal cord. *J Neurosci* 1999; 19: 5810-5822.
22. Navarro A, Boveris A. The mitochondrial energy transduction system and the aging process. *Am J Physiol Cell Physiol* 2007; 292: 670-686.
23. Ahlemeyer B, Junker V, Huhne R, Kriegelstein J. Neuroprotective effects of NV-31, a bilobalide-derived compound: evidence for an antioxidative mechanism. *Brain Res* 2001; 890: 338-342.
24. Li Z, Lin XM, Gong PL, Zeng FD, Du GH. Effects of Ginkgo biloba extract on gap junction changes induced by reperfusion/reoxygenation after ischemia/hypoxia in rat brain. *Am J Chin Med* 2005; 33: 923-34.
25. Ursini F, Bindoli A. The role of selenium peroxidases in the protection against oxidative damage of membranes. *Chem Phys Lipids* 1987; 44: 255-276.
26. Albrecht S, Zimmermann T, Ockert D, Oelschlager S, Heinzmann J, Schilling JU. Does selenium prevent peroxynitrite formation from NO in vascular surgery interventions? A clinical study. *Med Klin* 1997; 15: 10-13.
27. Gupta R, Singh M, Sharma A. Neuroprotective effect of antioxidants on ischemia and reperfusion induced cerebral injury. *Pharmacol Res* 2003; 48: 209-215.
28. Kwon YS, Ann HS, Nabeshima T, Shin EJ, Kim WK, Jhoo JH, et al. Selegiline potentiates the effects of EGb 761 in response to ischemic brain injury. *Neurochem Int* 2004; 45: 157-170.