

Morphometric measurements of the thalamus and interthalamic adhesion by MRI in the South-East of the Caspian Sea border

Mohammad R. Mohammadi, MD, Seyed H. Hosseini, BSc, Mohammad J. Golalipour, MSc, PhD.

ABSTRACT

الأهداف: تقييم الاختلافات في نوع الجنس، والعمر ذي الصلة بالمتغيرات الشكلية للمهاد، والالتصاق داخل المهاد، والاختلافات في الجانب الأيمن- الأيسر للمهاد على مجموعة عرقية فارسية متوطنة في الجنوب الشرقي لحدود بحر قزوين.

الطريقة: أجريت هذه الدراسة الوصفية على 97 مريضاً (44 ذكر و53 أنثى) بدون المتغيرات المرضية العصبية والأعراض. تم إدخالهم مركز كواسر للأشعة بالرنين المغناطيسي (MRI) في مدينة جورججان- إيران، في عام 2006م. تم قياس أبعاد المهاد بواسطة التصوير بأشعة الرنين المغناطيسي (MRI). كما تم قياس الأطوال العمودية للمهاد والالتصاقات داخل المهاد في أجزاء التاجي، بينما تم الحصول على الأطوال الأمامية الخلفية والمتعاكسة للمهاد والالتصاقات داخله في السطح المحوري. قيمت البيانات بواسطة برامج التحليل الإحصائي (SPSS 11.5).

النتائج: كانت أبعاد المهاد أطول لدى الذكور. لم يكن هنالك علاقة ملحوظة بين حجم المهاد والالتصاقات داخله وفقاً للعمر. تبين أن أبعاد المهاد تزداد قليلاً مع العمر من 31 عاماً وحتى 40 عاماً وبعد ذلك تنقص. لم يكن هنالك علاقة بين العمر، ونوع الجنس، وأبعاد الالتصاقات داخل المهاد.

خاتمة: أظهرت هذه الدراسة انه لا يوجد اختلافات ملحوظة بين الجانب الأيمن والجانب الأيسر للمهاد، ولكن أبعاد الجانب الأيسر للمهاد كانت أطول قليلاً من الجانب الأيمن.

Objectives: To assess the gender differences and the age-related morphometrical changes of the thalamus, interthalamic adhesion, and the right-left differences of the thalamus of the native Fars ethnic group in the South-East of the Caspian Sea border

Methods: This descriptive study was carried out on 97 patients (44 males and 53 females) without neuropathologic changes and symptoms admitted to the Kowsar MRI center in the South-East of the

Caspian Sea border (Gorgan City, Northern Iran) in 2006. Thalamic dimensions were measured by MR images. The vertical lengths of the thalami and interthalamic adhesion were measured in the coronal sections, while the anteroposterior and transverse length measurements of the thalami and interthalamic adhesion were obtained in the axial plane. The data were assessed by SPSS 11.5 statistics program.

Results: Thalamic dimensions were longer in males. There was no significant correlation between size of thalamus and interthalamic adhesion regarding age; however, we found that thalamic dimensions increase a little with age until the 31-40 years group, and decreased after that. There was no correlation between age and gender groups and dimensions of the interthalamic adhesion.

Conclusion: This study showed that there are no significant differences between right and left sides of the thalamus, however, the left-side thalamic dimensions were a little longer than the right.

Neurosciences 2008; Vol. 13 (3): 272-275

From the Department of Neurosurgery (Mohammadi), Department of Anatomy (Hosseini), Department of Embryology and Histology (Golalipour), Gorgan University of Medical Sciences, Gorgan, Iran.

Received 16th November 2007. Accepted 12th March 2008.

Address correspondence and reprint request to: Dr. Mohammad Jafar Golalipour, Department of Embryology and Histology, Gorgan University of Medical Sciences, Gorgan, Iran. Tel. +98 (171) 4421289, 4425165. Fax. +98 (171) 4421657. E-mail: mjgolalipour@yahoo.com

The thalami are large, grey, bilateral, ovoid, masses flanking the third ventricle, which also extend posterior to it. A very large number of sensory channels converge on it and many integrate with each other, the results, of even greater range and complexity, diverge to many destinations. It is indeed involved in activities of all major regions of the CNS.^{1,2} There are many studies concerning the diameters, area, volume, morphology, age and gender-related differences of the thalamus.^{3,4} Investigations of aging effects on the brain

are important, not only to understand normal aging, but also for comparative study of the pathophysiology of degenerative brain disorders. Literature investigating right-left differences for the thalamus is scarce. The MRI is an important research tool that enables investigation of the brain in vivo. Direct measurement in vital cases is not possible. Direct method is used in cadavers where the brain is removed during autopsy from the cranial vault. Although some research has estimated morphometric indices such as cranial capacity and brain weight of Iranian newborns recently,⁵⁻⁷ there is no documented study on the morphologic and morphometric characteristic of the thalamus in the South-East of the Caspian Sea border (Gorgan City, Northern Iran). Therefore in this study, our purpose was to assess the gender differences and the age-related morphometrical changes of the thalamus and interthalamic adhesion of the native Fars ethnic group in the South-East of the Caspian Sea border. Additionally, we analyzed the right-left differences of the thalamus.

Methods. This descriptive study was carried out on 97 patients (44 males and 53 females) without neuropathologic changes and symptoms admitted to the Kowsar MRI center in the South-East of the Caspian Sea border (Gorgan City, Northern Iran) in 2006. The patients were divided into 5 age groups. The groups were 20 years old and under, 21-30, 31-40, 41-50, 51 and more. Thalamic dimensions were measured on an MRI Unit (Siemens, Symphony, 1.5 Tesla). The MR images were acquired in the axial and vertical planes by using flair, T1 and T2 weighted sequences. The vertical lengths of the thalami and interthalamic adhesion were measured in the coronal sections, while the anteroposterior and transverse length measurements of the thalami and interthalamic adhesion were obtained in the axial plane (Figures 1 & 2). For investigating right-left differences in thalami we measured both thalamic dimensions of all patients. Patient consent was obtained for the study along with a clearance from the institutional ethics committee.

The data were assessed by SPSS 11.5 statistical program. For all the comparisons, *p*-values less than 0.05 were considered significant.

Results. Mean \pm SD of the dimensions of the thalamus and adhesion interthalami in males and females are depicted in Table 1. Regarding gender, the mean values of thalamic dimensions such as the anteroposterior ($p=0.016$), transverse ($p=0.002$), and vertical lengths ($p=0.006$) were found longer in males than in females. The transverse length of the interthalamic adhesion was significantly longer in male. There was no significant difference between anteroposterior and vertical length

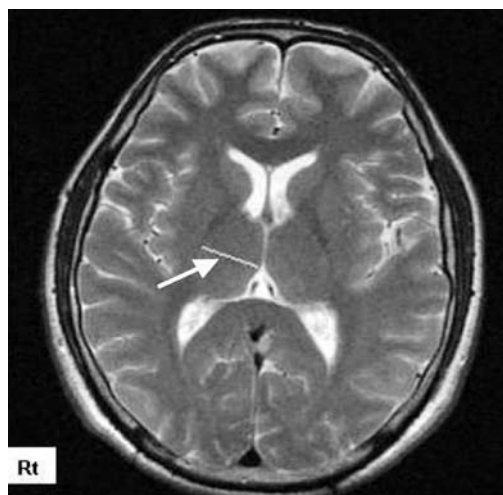


Figure 1 - Measurement of the transverse length (arrow) of right thalamus in magnetic resonance imaging.

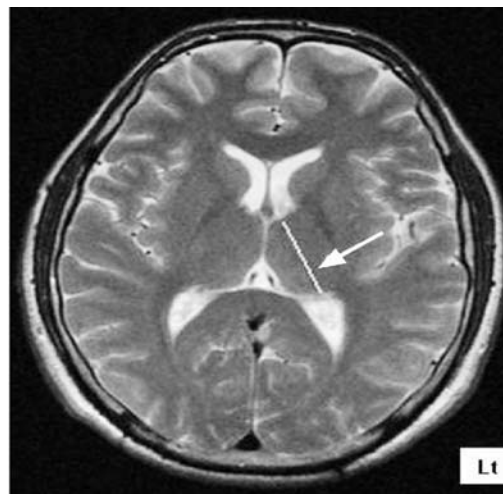


Figure 2 - Measurement of the anteroposterior length (arrow) of left thalamus in MR imaging.

of the interthalamic adhesion regarding gender. Also, there was no significant difference between the gender groups and dimensions of the interthalamic adhesion (Table 2). In the >51 years old group, the anteroposterior, transverse, and vertical lengths of the thalamus were measured as the shortest, and in the 31-40 years old group, the anteroposterior, transverse, and vertical lengths of the thalamus were measured as the longest. According to age, thalamic dimensions gradually increased a little until the 31-40 years group, and then decreased in older groups, however, there was no correlation between the sizes of the thalamus regarding age. Also, no significant differences were found between the age groups and anteroposterior, transverse, and vertical lengths of the interthalamic adhesion (Table 1).

Table 1 - Mean \pm SD of the dimensions of the thalamus and interthalamic adhesion in the groups by MR imaging (millimeter).

Gender	Anteroposterior Rt	Anteroposterior Lt	Transverse Rt	Transverse Lt	Vertical Rt	Vertical Lt	Adhesio AP	Adhesio Transverse	Adhesio Vertical
Male	33.86 \pm 1.36	33.84 \pm 1.46	22.37 \pm 1.03	22.49 \pm 1.09	16.88 \pm 1.11	16.89 \pm 1.15	7.59 \pm 1.89	3.18 \pm 0.43*	6.17 \pm 1.05
Female	33.00 \pm 1.53	33.03 \pm 1.73	21.69 \pm 1.14	21.80 \pm 1.06	16.23 \pm 1.09	16.24 \pm 1.16	7.71 \pm 1.53	2.60 \pm 0.52*	6.40 \pm 1.35
All	33.39 \pm 1.51	33.40 \pm 1.65	22.00 \pm 1.14**	22.11 \pm 1.12**	16.52 \pm 1.14	16.54 \pm 1.19	7.66 \pm 1.66	2.84 \pm 0.56	6.31 \pm 1.22

Rt - right, Lt - left, * $p=0.002$, transverse dimension of the interthalamic adhesion was significant according to gender ** $p=0.013$, thalamic transverse dimensions were significant according to side, MR - magnetic resonance, AP - anteroposterior

Table 2 - Mean \pm SD of the dimensions of the thalamus and interthalamic adhesion according to age by MR imaging (millimeter).

Age group	Anteroposterior Rt	Anteroposterior Lt	Transverse Rt	Transverse Lt	Vertical Rt	Vertical Lt	Adhesio AP	Adhesio Transverse	Adhesio Vertical
20 & under	33.30 \pm 1.42	33.31 \pm 1.72	21.60 \pm 1.25	21.68 \pm 1.29	16.51 \pm 1.07	16.46 \pm 1.15	8.86 \pm 1.69	2.88 \pm 0.44	6.18 \pm 1.29
21-30	33.42 \pm 1.53	33.47 \pm 1.73	22.16 \pm 0.84	22.23 \pm 0.84	16.60 \pm 1.15	16.51 \pm 1.19	7.55 \pm 1.44	2.83 \pm 0.54	6.08 \pm 0.67
31-40	33.53 \pm 1.34	33.61 \pm 1.36	22.36 \pm 1.13	22.40 \pm 1.14	16.83 \pm 1.27	16.86 \pm 1.32	6.64 \pm 1.96	2.84 \pm 0.40	7.20 \pm 1.49
41-50	33.44 \pm 1.54	33.32 \pm 1.74	22.03 \pm 0.99	22.32 \pm 0.85	16.33 \pm 0.86	16.38 \pm 0.96	6.69 \pm 1.00	2.86 \pm 0.93	6.10 \pm 1.87
51 & above	33.13 \pm 1.94	33.05 \pm 2.03	21.53 \pm 1.36	21.68 \pm 1.31	16.05 \pm 1.11	16.17 \pm 1.20	6.53 \pm 0.75	2.70 \pm 0.87	6.40 \pm 0.70

Rt - right, Lt - left, AP - anteroposterior, MR - magnetic resonance

To determine right-left side differences in the size of the thalamus, we calculated mean values of all patients without gender and age consideration (Table 2). The left transverse length was significantly longer. There were no significant differences between right and left sides of the thalamic anteroposterior and vertical lengths, however, the left anteroposterior, transverse, and vertical lengths were a little longer than the right side.

Discussion. The results of this study show that thalamic dimensions gradually increase a little with age until 31-40 years and after that decrease, however, these were not significant. Although in this study we did not determine the size of white and gray matter, however, in the study of Ge et al,⁸ this increasing and subsequent decreasing of thalamic dimensions according to aging, is dependent on gray and white matter development. The increasing period is due to white matter growth and the decreasing period is connected to both gray and white matter volume loss. Ge et al⁸ showed that gray matter volume loss appears to be a constant, linear function of age throughout adult life, whereas white matter volume loss seems to be delayed until middle adult life. Both appear to be independent of gender. Furthermore Smith et al,⁹ using MRI imaging indicated gray matter decreased with age at a rate of 2.4 cm³/year (-0.18%/year). Also, it has been reported that thalamic size and position vary considerably in various neuropsychiatric diseases such as schizophrenia,¹⁰ temporal lobe epilepsy,¹¹ and third

ventricle enlargement. Other research indicated that aging causes changes to the brain size, vasculature, and cognition.^{12,13} It has been widely found that the volume of the brain or its weight declines with age at a rate of around 5% per decade after age 40, with the actual rate of decline possibly increasing with age particularly over age 70.¹³ Conversely, in a study measuring the thalami, it was concluded that the thalamus does not undergo any significant changes with age, while the interthalamic adhesion becomes thin and lengthened.²

This study showed that the vertical thalamic dimensions of native Fars people in the north of Iran is similar to another study in Turkey,² however, other findings of thalamic dimensions such as anteroposterior and transverse are lower than the Turkish people.² This difference may be due to ethnic or geographic factors. In our observation thalamic dimensions in males were longer than females. This finding is similar to Sen et al.² In our study and that of Sen et al,² the anteroposterior and vertical dimensions of the interthalamic adhesion in females were higher than males and transverse dimension in males was higher than the females. In this study there was no correlation between age, gender, and dimensions of the interthalamic adhesion, however, Sen et al's study² reported that the anteroposterior and vertical lengths of the interthalamic adhesion decreases with age, and the transverse length increases. Also in our study, left sided thalamic dimensions were longer than the right, however, this difference was not significant,

and a study by Ettinger et al¹⁴ showed that the right thalamus was larger than the left thalamus. Based on our results we suppose there is a correlation between being right or left handedness and side differences of thalamus, but further investigation is required.

Acknowledgments. We are grateful to the personnel of Kowsar MRI center, especially Mr. Goldasteh, who assisted with the MR image preparation. Special thanks are due to Dr. Mortazavi Moghadam and Miss Sorayya Ghafari for their helpful advice.

References

1. Carpenter MB. Core text of Neuroanatomy. 4th ed. Baltimore (MD): Williams & Wilkins; 1991. p. 49-51.
2. Sen F, Ulubay H, Ozeksi P, Sargon MF, Tascioglu AB. Morphometric measurements of the thalamus and interthalamic adhesion by MR imaging. *Neuroanatomy* 2005; 4: 10-12.
3. Murphy DJ, DeCarli C, McIntosh AR, Daly E, Mentis MJ, Pietrini P, et al. Sex differences in human brain morphometry and metabolism: an in vivo quantitative magnetic resonance imaging and positron emission tomography study on the effect of aging. *Arch Gen Psychiatry* 1996; 53: 585-594.
4. Sullivan EV, Rosenbloom M, Serventi KL, Pfefferbaum A. Effects of age and sex on volumes of the thalamus, pons and cortex. *Neurobiol Aging* 2004; 25: 185-192.
5. Gopalipour MJ, Hosseinpour KR. Estimation of the cranial capacity and brain weight of Iranian female newborns. *Eur J Anat* 2006; 10: 49-52.
6. Gopalipour MJ, Jahanshahi M, Haidari K. The variation of head and face shapes in female newborns in the South-East of the Caspian Sea (Iran-Gorgan). *Eur J Anat* 2005; 9: 95-98.
7. Gopalipour MJ, Haidari K. Effect of the ethnic factor on cranial capacity and brain weight of male newborns in northern Iran. *Neuroembryol Aging* 2004; 3: 146-148.
8. Ge Y, Grossman RI, Babb JS, Rabin ML, Mannon LJ, Kolson DL. Age-related total gray matter and white matter changes in normal adult brain. Part I: Volumetric MR imaging analysis. *Am J Neuroradiol* 2002; 23: 1327-1333.
9. Smith CD, Chebrolu H, Wekstein D, Schmitt F, Markesbery W. Age and gender effects on human brain anatomy: A voxel-based morphometric study in healthy elderly. *Neurobiol Aging* 2006; 28: 1075-1087.
10. Erbagci H, Yildirim H, Herken H, Gmsburun E. A magnetic resonance imaging study of the adhesio interthalamica in schizophrenia. *Schizophr Res* 2002; 55: 89-92.
11. Natsume J, Bernasconi N, Andermann F, Bernasconi A. MRI volumetry of the thalamus in temporal, extratemporal, and idiopathic generalized epilepsy. *Neurology* 2003; 60: 1296-1300.
12. Malobabic S, Puskas L, Blagotic M. Size and position of the human adhesio interthalamica. *Gegenbaurs Morphol Jahrb* 1987; 133: 175-180.
13. Peters R. Ageing and the brain. *Postgrad Med J* 2006; 82: 84-88.
14. Ettinger U, Picchioni M, Landau S, Matsumoto K, van Haren NE, Marshall N, et al. Magnetic resonance imaging of the thalamus and adhesio interthalamica in twins with schizophrenia. *Arch Gen Psychiatry* 2007; 64: 401-409

STATISTICS

Excerpts from the Uniform Requirements for Manuscripts Submitted to Biomedical Journals updated November 2003.
Available from www.icmje.org

Describe statistical methods with enough detail to enable a knowledgeable reader with access to the original data to verify the reported results. When possible, quantify findings and present them with appropriate indicators of measurement error or uncertainty (such as confidence intervals). Avoid relying solely on statistical hypothesis testing, such as the use of *P* values, which fails to convey important information about effect size. References for the design of the study and statistical methods should be to standard works when possible (with pages stated). Define statistical terms, abbreviations, and most symbols. Specify the computer software used.