

Prolonged hemiplegic migraine

Hilana A. Hatoum, MD, Ahmed A. Hassan, MD, Youssef A. Al-Said, MD, FRCP

ABSTRACT

الشقيقة الفالجية البؤرية هي نمط نادر من أنماط الشقيقة. تتميز بصداع معاود، يترافق مع بؤادر بؤرية عصبية مؤقتة، عادة ما تكون فالجا نصفيا. وقد يكون من الصعب أحيانا التمييز بين تلك الحالات وحالات الشقيقة المعقدة التي تخلف وراءها جلطة دماغية. من هنا تكمن أهمية معرفة التاريخ المرضي والعائلي للمريض وإجراء كافة التحاليل المخبرية والإشعاعية. يتضمن هذا المقال حالة للشقيقة الفالجية البؤرية العينية، وقد تميزت هذه الحالة بطول مدة الأعراض البؤرية العصبية كما تميزت بتنقل الأعراض العصبية. وقد كان للرنين المغناطيسي الدور الهام في التشخيص.

Hemiplegic migraine is a rare form of migraine variant. It is characterized by recurrent attacks of headache associated with temporary neurological deficit, usually unilateral hemiparesis or hemiplegia. It can be difficult to distinguish from migrainous stroke clinically, and a full neurological work-up and careful review of medical history and symptoms are necessary for the diagnosis. Two forms of hemiplegic migraine are known: familial and sporadic, phenotypically similar, differentiated by the absence of family history of similar attacks in the sporadic form. We report a case of sporadic hemiplegic migraine with unusually prolonged deficit and progression to quadriplegia with complete return to baseline 7 days after onset. Diffusion weighted images helped in excluding infarction.

Neurosciences 2008; Vol. 13 (3): 302-304

From the Department of Neurosciences, King Faisal Specialist Hospital and Research Center, Jeddah, Kingdom of Saudi Arabia.

Received 20th September 2007. Accepted 12th December 2007.

Address correspondence and reprint request to: Dr. Hilana A. Hatoum, Department of Neurosciences, King Faisal Specialist Hospital and Research Center, PO Box 40047, Jeddah 21499, Kingdom of Saudi Arabia. Tel. +966 (2) 6677777 Ext. 5819. E-mail: hmmachmouchi@hotmail.com

Hemiplegic migraine is a rare form of migraine variants. It is characterized by paroxysmal episodes in which headache is associated with temporary motor deficit. Other associated symptoms may include aphasia, visual disturbance, altered consciousness, and even coma.^{1,2} The focal neurological deficit may precede or accompany the headache, which is usually less dramatic than the motor deficit.³ Prolonged hemiplegic migraine may be easily misdiagnosed clinically as migrainous stroke and poses much confusion. We report a case of paralytic migraine where MRI, particularly diffusion-weighted images (DWI) as well as magnetic resonance angiography (MRA) helped in excluding infarction and vasospasm. The importance of this case resides in the unusually prolonged symptomatology and in the spreading fashion of the neurological deficit resulting in quadriplegia.

Case Report. We present a 47-year-old woman, known to have migraine with aura, who had 3 attacks of migraine with reversible quadriplegia. The first attack was at the age of 42 years and was characterized by a hemiplegic migraine that progressed in less than an hour to quadriplegia. The whole picture resolved completely 48 hours after onset with no residual deficit. Detailed investigations at that time including MRI/MRA, and electroencephalogram were all negative as per the patient herself. She was started on calcium channel blockers, Verapamil, with no recurrence of similar attacks, but she had to stop it later on due to serious side effects (galactorrhea, hyperprolactinemia, hypertrophy of pituitary affecting her vision) all of which disappeared when she stopped Verapamil. The second attack occurred in November 2006 (5 years later) for which she was hospitalized in our hospital. Her symptoms started with her usual migrainous headache that awakened her from sleep, associated with nausea, and vomiting. The pain improved partially on simple analgesics, but a few hours after the onset and while she was at the hospital where she works, she had recurrence of her headache involving the left half of the head first, followed by right sided weakness involving first the right upper extremity, then the right lower extremity along with slurred speech. Eventually, her headache continued to worsen and started to affect the whole head and the weakness evolved in a spreading fashion and involved the left side also. No vertigo or dizziness was reported, and she denies tinnitus

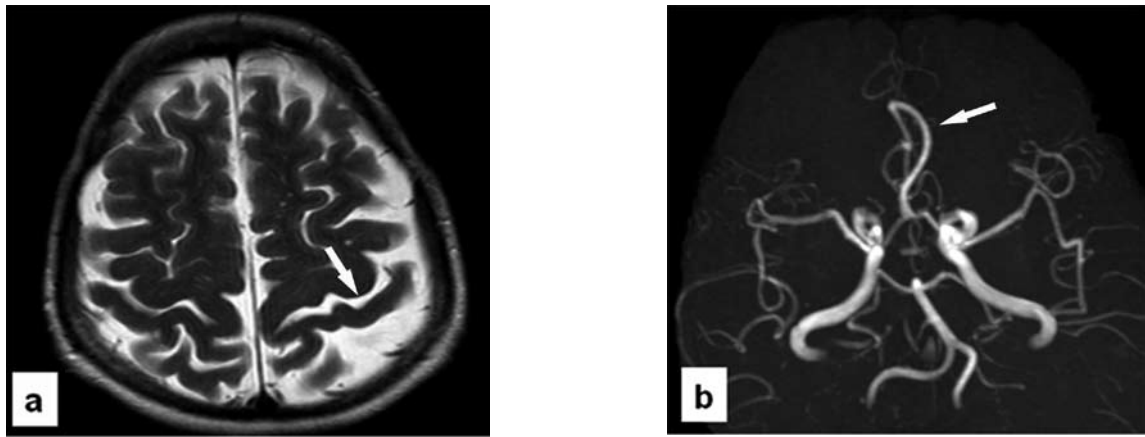


Figure 1 - Patient MR showing: a) T2-weighted images show prominence of cortical sulci out of proportion to the patient's age, b) MR angiography showing normal anatomic variant of a single anterior cerebral A2 segment with otherwise normal intracranial circulation and no evidence of spasm.

or diplopia. Review of system was unremarkable and she was in her usual condition recently. On examination she was awake, completely alert, well oriented, her speech was slurred and she had a complete flaccid quadriplegia, otherwise, her cranial nerve examination was normal, no nystagmus and remainder of the exam unremarkable. Past medical history includes other than her classical migraine, systemic lupus erythematosus (SLE) since 7 years as well as essential hypertension, she was on immunosuppressive treatment and antihypertensive medications. Family history is positive for migraine, but no history of similar attacks. All blood tests including those for a prothrombotic state were normal. C-reactive protein and erythrocyte sedimentation rate were normal. Her SLE state was inactive both clinically and biologically. An MRI brain and MRA for intra and extra cranial vessels were carried out on an emergency basis. The MRI, and mainly the DWI did not show any evidence of infarction, however, there was prominence in the cortical sulci and ventricles out of proportion to the patient's age, consistent with atrophic changes. The MRA of the carotid bifurcations demonstrated no evidence of carotid stenosis on either side, the intracranial circulation did not show evidence of stenosis (Figure 1). Therapeutic management consisted basically on intravenous steroids, 1g methylprednisolone for 5 days, hydration, analgesics, amitriptyline, and antiemetics. Her course in hospital was characterized by prolonged paralysis with very slow improvement. Repeated MRI/DWI at day 4 further confirmed the absence of infarction. Perfusion scan could not be carried out for technical issues. Clinically her speech improved markedly on the first day, her left sided weakness improved on day 3 with complete return to baseline on day 5, and her right sided weakness improved on day 4 and she was able to walk with

assistance first at day 4 then without assistance at day 6 with a full return to baseline by day 7. The third attack occurred in May 2007 and was almost similar to her previous one, but much shorter in duration with return to baseline in almost 12 hours. The MRI and MRA were unremarkable, and the patient herself elected to be discharged before further investigations.

Discussion. We describe a 47-year-old woman with 3 attacks, almost stereotyped, of migraine with aura associated with motor weakness. These attacks start with unilateral motor deficit, contralateral to the side of headache, that progress in a spreading fashion to quadriplegia in less than 2 hours. The clinical picture was completely reversible in the 3 attacks and there was no temporal relation between the 3 attacks and the activity of her SLE. However, she has a family history of migraine with aura, but no family history of similar events. We therefore believe that she fits the criteria of sporadic hemiplegic migraine (SHM) according to the International Classification of Headache Disorders.^{4,5}

Hemiplegic migraine may occur sporadically, as first described by Lieveing in 1873,⁶ and it may occur as a familial disorder as reported by Clarke in 1910.⁷ The symptoms of sporadic and familial hemiplegic migraine (FHM) are similar, but those with SHM, have no affected first or second-degree relatives. Genetics studies have established that many cases of FHM are linked to mutations in the CACNA1A gene, which encodes a P/Q type calcium channel, while only rare cases of SHM have mutations in the gene.^{8,9} This calcium channel is located on the presynaptic membranes and functions as a key controller and modulator of the release of both excitatory and inhibitory neurotransmitters throughout

the CNS. The most frequent inheritance of FHM is autosomal dominant.

The prevalence of SHM is estimated to be 0.01% according to an epidemiological survey of the Danish population of 5.2 million people.¹⁰ The pathophysiology of the neurological deficits in hemiplegic migraine remains unclear, however 2 hypotheses have been proposed: 1) regional ischemia due to vasospasm, 2) neuronal hypoexcitability caused by cortical spreading depression (CSD). In our case, the absence of increased signal on DWI-MRI, after several symptomatic days, argues against ischemia. The DWI-MRI has been shown to have a sensitivity of 100% in cases of persistent brain ischemia.¹¹ Rosenbaum¹² concluded that because the neurological deficits were reversible, they were likely produced by early vasospasm followed by edema. Our MRA, carried out within 2 hours of the motor deficit, did not show vasospasm, and in fact cerebral angiography is uniformly found to be normal in hemiplegic migraine.¹³ Perfusion weighted images would be helpful also for evaluation of the cerebral blood flow, but it was not carried out for our patient. Andersen et al¹⁴ found in 12 patients with migraine with aura, hemispheric hypoperfusion followed by hyperperfusion that eventually returned to normal. This temporal change in cerebral blood flow between hypo- and hyperperfusion may partly explain the absence of ischemia and explain the prolonged aura similarly to what is observed in hyperperfusion syndrome after carotid endarterectomy. However, Hayashi et al¹⁵ reported an MRI finding of cerebral hemiatrophy in a 44-year-old man believed to have hemiplegic migraine, this may raise the question in our case whether her repeated attacks with bilaterality of symptoms are behind the marked bilateral cortical atrophy out of proportion to her age.

In conclusion, hemiplegic migraine is still an obscure phenomenon and can be easily misdiagnosed as migrainous stroke posing a lot of confusion. In our case the use of MRI, DWI, and MRA were effective in excluding cerebral infarction.

References

1. Black DF. Sporadic and familial hemiplegic migraine: diagnosis and treatment. *Semin Neurol* 2006; 26: 208-216.
2. Ducros A, Denier C, Joutel A, Cecillon M, Lescoat C, Vahedi K, et al. The clinical spectrum of familial hemiplegic migraine associated with mutations in a neuronal calcium channel. *N Engl J Med* 2001; 345: 17-24.
3. Thomsen LL, Ostergaard E, Olesen J, Russel MB. Evidence for a separate type of migraine with aura. *Neurology* 2003; 60: 595-601.
4. Classification and diagnosis criteria for Headache disorders, cranial neuralgias and facial pain. Headache Classification Committee of the International Headache Society. *Cephalalgia* 1988; 8 Suppl 7: 1-96.
5. Headache Classification Committee of the International Headache Society. The International Classification of Headache Disorders. *Cephalalgia* 2004; 24 Suppl 1: 28-29.
6. Lieveing E. On Megrin, Sick-Headache, and some allied Disorders. London: Churchill; 1873.
7. Clarke JM. On recurrent motor paralysis in migraine: with report of a family in which recurrent hemiplegia accompanied the attacks. *BMJ* 1910; 1: 1534-1538.
8. Thomsen LL, Olesen J. Sporadic hemiplegic migraine. *Cephalalgia* 2004; 24: 1016-1023.
9. Terwindt G, Kors E, Haan J, Vermeulen F, Van den Maagdenberg A, Frants R, et al. Mutation analysis of the CACNA1A calcium channel subunit gene in 27 patients with sporadic hemiplegic migraine. *Arch Neurol* 2002; 59: 1016-1018.
10. Lykke Thomsen L, Kirchmann Eriksen M, Faerch Romer S, Andersen I, Ostergaard E, Keiding N, et al. An epidemiological survey of hemiplegic migraine. *Cephalalgia* 2002; 2: 361-375.
11. Barber PA, Darby DG, Desmond PM, Gerraty RP, Yang Q, Li T, et al. Identification of major ischemic change. Diffusion-weighted imaging versus computed tomography. *Stroke* 1999; 30: 2059-2065.
12. Rosenbaum HE. Familial hemiplegic migraine. *Neurology* 1960; 10: 164-170.
13. Rajput V, Kramer ED. Adult onset familial hemiplegic migraine. *Headache* 1995; 35: 423-427.
14. Andersen AR, Friberg L, Olsen TS, Olesen J. Delayed hyperemia following hypoperfusion in classic migraine. Single photon emission computed tomographic demonstration. *Arch Neurol* 1988; 45: 154-159.
15. Hayashi R, Tachikawa H, Watanabe R, Honda M, Katsumata Y. Familial hemiplegic migraine with irreversible brain damage. *Intern Med* 1998; 37: 166-168.