

Multiple sclerosis with recurrent meningitis

Mansour A. Al-Moallem, MBBS, ABIM, Radwan M. Zaidan, MD, PhD, Nura H. Alkali, FMCP, MSc, Abdulrahman Y. Taban, MBBS, FRCP

ABSTRACT

التصلب اللويحي المتعدد هو عبارة عن مرض مناعي ذاتي، يؤدي إلى تقشر في طبقة الميلين في الجهاز العصبي المركزي والعصب البصري، ونادرا ما يصاحبه التهاب سحائي لا جرثومي. هناك بعض المتلازمات قد تسبب التهابات سحائية وتكون مصحوبة بتقشر في مادة الميلين قد تحاكي مرض التصلب اللويحي المتعدد، وبالتالي هناك حاجة للبحث عنها حيث أن بعضها قابل للعلاج بالرغم من صعوبة التشخيص في بعض الأحيان. نستعرض هنا حالة سيدة تعاني من مرض مشابه للتصلب اللويحي مع تكرار الالتهاب السحائي خلال سبعة أعوام. وبعد الفحوصات المكثفة توصلنا إلى إن الالتهاب السحائي المتكرر قد يكون ظاهرة غير نموذجية لمرض التصلب اللويحي المتعدد. ومن هذا المنطلق، يمكن تحاشي الكثير من الفحوصات عند ظهور حالة مشابهة والبدء بالعلاج المبكر.

Multiple sclerosis is an autoimmune demyelinating disease that is rarely associated with aseptic meningitis. However, certain syndromes causing aseptic meningitis are often associated with central nervous system demyelination that mimics multiple sclerosis (MS). Since many of these syndromes are potentially treatable, unmasking an alternative diagnosis is essential whenever an MS-like illness and recurrent meningitis are encountered in the same patient. Yet, the search for an alternative diagnosis may be elusive sometimes, despite extensive and appropriate investigations. We present a young woman with an MS-like illness associated with recurrent meningitis over a 7-year period. After an exhaustive evaluation, we conclude that recurrent meningitis is an atypical manifestation of MS. If neurologists would appreciate this point, unrewarding and costly investigations may be avoided and appropriate therapy instituted when similar cases are encountered in clinical practice.

Neurosciences 2008; Vol. 13 (3): 310-313

From the Neurology Unit, Department of Medicine, King Khalid University Hospital, Riyadh, Kingdom of Saudi Arabia.

Received 31st December 2007. Accepted 31st March 2008.

Address correspondence and reprint request to: Dr. Nura H. Alkali, Neurology Unit, Department of Medicine, King Khalid University Hospital, PO Box 2925, Riyadh 11461, Kingdom of Saudi Arabia. Tel: +966 557236237, +966 (1) 4671532. Fax: +966 (1) 4672424. E-mail: nalkali@yahoo.com

Multiple sclerosis (MS) is an autoimmune disease of the central nervous system (CNS) in which the pathologic hallmark is a demyelinating white matter plaque.¹ Meningeal inflammation has been reported rarely in MS,²⁻⁴ whereas other diseases commonly cause CNS demyelination as well as recurrent meningitis. While it is necessary to exclude other demyelinating diseases whenever an MS-like illness manifests with recurrent meningitis, an occasional patient poses a diagnostic challenge. Here, we present a girl with an MS-like illness and recurrent meningitis occurring over a 7-year period. Our main objective is to alert neurologists to recognize this atypical presentation of MS.

Case Report. A 15-year-old girl presented in June 2000 with diplopia and weakness of all 4 limbs that progressed over one week. She gave no history of fever, skin rash, orogenital ulcers or joint pains, and she had no family history of a connective tissue disorder. On examination, she had normal fundi, left third nerve palsy, left lower motor neuron facial palsy, and bilateral pyramidal signs with power of grades 0-1/5. She received IV methylprednisolone for 5 days and was discharged home. One month later, she returned with optic neuritis of her left eye. She was now diagnosed as MS, for which she had IV methylprednisolone and was started on interferon-beta treatment. Four months later, she presented with fever, headache, and neck rigidity. On examination, she had signs of meningeal irritation, but facial weakness had resolved completely and power had improved to 3-4/5 in all limbs. She received Ceftriaxone for presumed bacterial meningitis and made a full recovery. Brain and spinal MRI at first presentation revealed multiple high signals in the periventricular white matter, medulla, and cervical cord, which subsequently became more diffuse (Figures 1a-1f). Visual, auditory, and somatosensory evoked potentials

Disclosure. We hereby declare that the patient signed informed consent and this report conforms to the Ethical Committee guidelines of our institution.

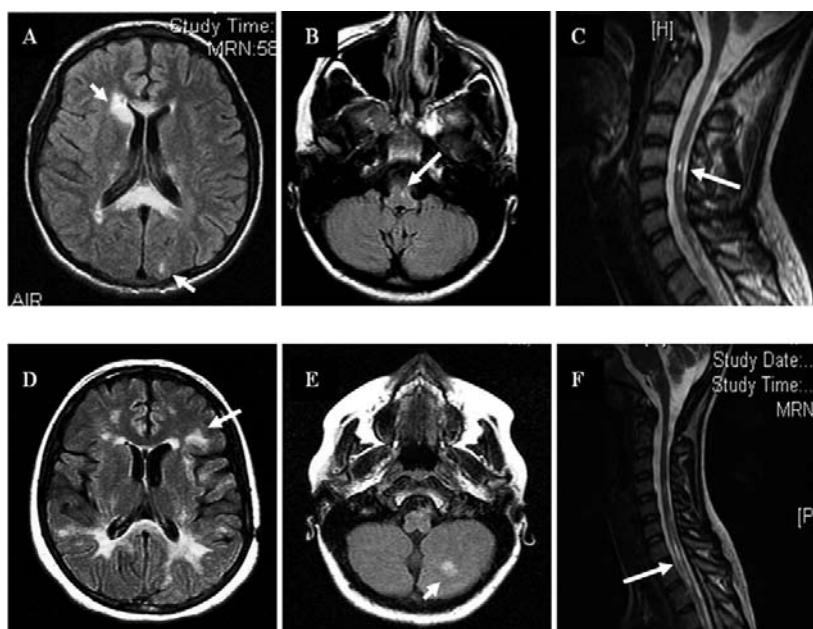


Figure 1 - Brain and spinal MRI images showing high intensity signals (indicated by white arrows) involving a) the periventricular white matter and corpus callosum, b) medulla, and c) cervical spinal cord at first presentation in June 2000. By June 2007, high intensity signals have involved more subcortical areas d), cerebellum e), and the thoracic spinal cord f).

Table 1 - Summary of clinical and CSF findings during 7 episodes of meningitis in a patient with multiple sclerosis.

Clinical or laboratory findings	November 2000	July 2001	August 2001	September 2002	June 2005	October 2006	June* 2007
<i>Clinical features</i>							
Fever, Headache	+	+	+	+	+	+	+
Photophobia	NA	+	NA	+	-	NA	-
Neck rigidity	+	-	+	+	+	+	+
Kerning's sign	+	+	+	+	+	+	+
CSF WBC	100	280	2000	120	650	50	0
Polymorphs (%)	70	20	90	10	70	0	-
Lymphocytes (%)	30	80	10	90	30	100	-
Protein (g/L)	1.41	0.93	2.53	0.43	1.5	0.68	0.22

*In June 2007, lumbar puncture was performed 7 days after presentation, when symptoms of meningitis had resolved, NA - information not available, CSF - cerebrospinal fluid, WBC - white blood cell count

all showed delayed latencies. Analysis of cerebrospinal fluid (CSF) at first admission showed normal glucose and protein, microscopy showed 28 white cells, 90% lymphocytes, while cultures were negative. Oligoclonal bands were positive in the CSF, with raised CSF IgG index. Coagulation profile, complete blood count, erythrocyte sedimentation rate, liver function tests, electrolytes, and urea were all normal. Serum Brucella, VDRL, antinuclear antibodies, ds-DNA, and anticardiolipin titers were all negative. Over the subsequent 6 years, she was admitted 8 times, due to 4 relapses of MS and 5 episodes of meningitis, with the 2 overlapping at one admission. Relapses consisted of one attack each of optic neuritis,

paraparesis, right hemiparesis, and right hemiparesis with a left cerebellar syndrome. She made complete recovery after each relapse, except for paraparesis that has persisted. Her second meningitis was treated with Ceftriaxone and Vancomycin, but subsequent episodes resolved spontaneously. A summary of her CSF findings during episodes of meningitis is shown in Table 1. Other findings including cytology, Gram and ZN stains, India ink, and bacterial and fungal cultures were all negative in the CSF. Herpes simplex virus (HSV) DNA was negative by polymerase chain reaction (PCR), as were IgM and IgG antibodies to HSV I and II, cytomegalovirus, Epstein-Barr virus, mycoplasma, legionella, and brucella. Serum

IgM and IgG antibodies to *Borrelia*, and CSF PCR for *Borrelia burgdorferi* DNA were negative. Radioisotope cisternography performed twice did not show CSF leakage. Serum calcium and phosphate, angiotensin converting enzyme, chest x-rays and CT sinuses were all normal. She had a pathergy test, which was negative, and she was reviewed by an ophthalmologist, who excluded uveitis. Histocompatibility leukocyte antigen typing excluded the B51 haplotype, HIV screening was negative by ELISA, and serum immunoglobulin electrophoresis, and complements assay were normal. Two weeks after her sixth meningitis, she underwent a meningeal biopsy, which showed congested blood vessels but normal histology, with no evidence of inflammation or granuloma. A trial of immunosuppressive therapy was suggested, but the patient declined. In June 2007, she presented with fever, headache, and a positive Kerning's sign. She had been bedridden for 2 years and her fundi showed bilateral optic atrophy. By the fifth day of admission, her meningitis had resolved with IV fluids and analgesics. She had a lumbar puncture on the seventh day, which revealed normal CSF parameters (Table 1). She now consented to immunosuppressive treatment and was started on Mycophenolate mofetil. Nine months later, her clinical condition remained stable.

Discussion. Our patient is a young female who had 5 attacks of focal neurologic deficits and 7 episodes of meningitis over a 7-year period. At first presentation, her brain, and spinal MRI scans showed multiple demyelinating lesions, while CSF studies revealed normal glucose and protein in association with a mild lymphocytic pleocytosis, findings that are consistent with MS.⁵ Her CSF parameters were normal during 3 relapses when she did not have meningitis, again supporting the diagnosis of MS and excluding the possibility of chronic meningitis. However, the episodes of meningitis associated with elevated CSF protein and white cell counts indicated intense meningeal inflammation, probably of an infective etiology. Yet, CSF glucose was always normal and extensive investigations failed to isolate any organism. These findings strongly supported a diagnosis of aseptic meningitis.⁵ A CSF leukocyte count of 35 cells/ μ L or more has been shown to discriminate aseptic meningitis from MS, with 91% sensitivity and 90% specificity, while CSF lymphocyte counts of 20 cells/ μ L or more has a sensitivity and a specificity of 82% and 83%.⁵ Other potential tests that may discriminate between MS and aseptic meningitis include CSF interleukin-6, CSF interleukin-8, and CSF QAlbumin,⁵ but these were not measured in our patient.

A common cause of recurrent aseptic meningitis is Mollaret's meningitis due to persistent HSV-2 virus

infections. It is associated with a CSF lymphocytic or polymorphonuclear pleocytosis that sometimes exceed several thousand cells per microliter, and the presence of large activated macrophages, or Mollaret cells.⁶ However, absence of the Mollaret cell and the persistently negative CSF PCR for HSV1 and 2, together with the normal histology on meningeal biopsy argues against this disease in our patient. Neurologic involvement has been reported in up to 25% cases of Behçet's syndrome, a relatively common disease in Asia.⁷ However, our patient lacked even a single diagnostic feature of this syndrome, as she had none of the oral ulcers seen in over 96% of patients, the skin or eye lesions seen in over 2/3, or the positive pathergy test seen in 1/3.⁸ She, also lacked the HLA B51 haplotype, a risk factor for Behçet's disease in 81% of Asian patients.⁸ Systemic lupus erythematosus (SLE) and Vogt Koyanagi Harada syndrome are also unlikely in this patient, who throughout the course of her illness had neither the serum antibodies characteristic of SLE, nor the classical uveitis and sensorineural deafness of Vogt Koyanagi Harada syndrome.^{9,10} Renal involvement or peripheral neuropathy that would suggest a primary vasculitis were also lacking in this patient.

Neurological involvement is seen in 5-15% of patients with sarcoidosis,¹¹ commonly causing cranial neuropathies, and occasionally CNS white matter lesions and recurrent meningitis.¹² Indeed, when she presented initially with third and seventh cranial nerve palsies, neurosarcoidosis was strongly suspected. However, throughout her history she did not manifest other features of sarcoidosis such as erythema nodosum, lymphadenopathy or lung involvement, and the normal serum calcium and ACE, together with normal result of meningeal biopsy make this disease a slim possibility. Lyme disease due to infection with *Borrelia burgdorferi* in the United States or other *Borrelia* species in Europe and Asia, rarely causes CNS demyelination and recurrent meningitis, especially among children and adolescents.¹³ However, Lyme disease has not been reported on the Arabian Peninsula, and our patient has never traveled abroad. Nevertheless, she had serological tests for *Borrelia* antibodies and CSF PCR for *Borrelia burgdorferi* DNA, all of which proved negative. Drug-induced meningitis is rarely associated with non-steroidal anti inflammatory agents and other medications, but our patient took only interferon beta-1a on a regular basis, and this was discontinued when she developed a peripheral neutropenia a few days after her second meningitis. Although neutropenia is a known complication of interferon therapy, aseptic meningitis has not been reported with this drug in the literature. In any case, she had further attacks of meningitis while she was off interferon therapy.

Reports in the literature have described patients with multiple sclerosis presenting with aseptic meningitis.²⁻⁴

Yoshihara et al² described a 13-year-old girl with MS whose initial presentation was recurrent optic neuritis and silent lesions on brain MRI, but who later developed meningitis associated with new MRI signals. Due to relapses and remissions of optic neuritis, the authors favored MS over acute disseminated encephalomyelitis, and suggested that meningitis associated with MS might be peculiar to children. Drory and Nisipeanu³ described a 20-year-old man with a prior history of optic neuritis who presented with fever, meningeal signs, a CSF picture of aseptic meningitis, and brain MRI changes compatible with MS. An unusual presentation of MS was described by Bornke⁴ and others, who reported a 58-year-old man with chronic progressive encephalomyelitis with polyneuritis and recurrent aseptic meningitis. In this patient, brain biopsy showed a pathologic appearance consistent with MS, but meningeal biopsy showed no active inflammation, similar to the findings in our own patient.

Multiple sclerosis is predominantly a disease of CNS white matter, but occasional findings include the presence of inflammatory changes affecting meninges close to demyelinating lesions,¹⁴ as well as collagenous thickening of leptomeninges found at autopsies of patients with long-standing disease.^{15,16} However, the possible mechanisms underlying these changes have not been described. We conclude that aseptic meningitis is an atypical presentation of MS, and if appreciated by clinicians, unrewarding investigations could be avoided and timely treatment started when such instances are encountered in clinical settings.

Acknowledgment. We wish to thank Dr. Ahmed A. Daif from King Khaled University Hospital for assisting in data summary, and Dr. Majed M. Aldosari of King Fahad Medical City for assisting in the literature search.

References

1. Frohman EM, Racke MK, Raine CS. Multiple sclerosis – the plaque and its pathogenesis. *N Engl J Med* 2006; 354: 942-955.
2. Yoshihara A, Yamanoi T, Takahashi S, Yamamoto T. A case of childhood multiple sclerosis presented with meningitis and multiple silent plaques [Abstract]. *Rinsho Shinkeigaku* 2003; 43: 98-101.
3. Drory VE, Nisipeanu P. Aseptic meningitis: an unusual presentation of multiple sclerosis. *Eur Neurol* 1995; 35: 240-241.
4. Börnke C, Przuntek H, Postert T, Schwechheimer K, Büttner T. Atypical multiple sclerosis presenting as chronic progressive encephalomyelitis with polyneuritis and recurrent aseptic meningitis. *J Neurol* 1999; 246: 136-139.
5. Kleine TO, Zwerenz P, Zofel P, Shiratori K. New and old diagnostic markers of meningitis in cerebrospinal fluid (CSF). *Brain Res Bull* 2003; 61: 287-297.
6. Dylewski JS, Bekhor S. Mollaret's meningitis caused by herpes simplex virus type 2: case report and literature review. *Eur J Clin Microbiol Infect Dis* 2004; 23: 560-562.
7. Barnes CG, Yazici H. Behcet's syndrome. *Rheumatology* 1999; 38: 1171-1174.
8. Sakane T, Takeno M, Suzuki N, Inaba G. Behcet's disease. *N Engl J Med* 1999; 341: 1284-1291.
9. Jennings JE, Sundgren PC, Attwood J, McCune J, Maly P. Value of MRI of the brain in patients with systemic lupus erythematosus and neurologic disturbance. *Neuroradiology* 2004; 46: 15-21.
10. Kitamura M, Takami K, Kitaichi N, Namba K, Kitamei H, Kotake S, et al. Comparative study of two sets of criteria for the diagnosis of Vogt-Koyanagi-Harada's disease. *Am J Ophthalmol* 2005; 139: 1080-1085.
11. Jarnier D, Series C. Neurosarcoidosis – Review of the literature. *Neurochirurgie* 1999; 45: 214-218.
12. Marangoni S, Argentiero V, Tavolato B. Neurosarcoidosis. Clinical description of 7 cases with a proposal for a new diagnostic strategy. *J Neurol* 2006; 253: 488-495.
13. Halperin JJ. Nervous system Lyme disease. *J Neurol Sci* 1998; 153: 182-191.
14. Adams CW, Poston RN, Buk SJ, Sidhu YS, Vipond H. Inflammatory vasculitis in multiple sclerosis. *J Neurol Sci* 1985; 69: 269-283.
15. Barnard RO, Triggs M. Corpus callosum in multiple sclerosis. *J Neurol Neurosurg Psychiatry* 1974; 37: 1259-1264.
16. Prineas JW, McDonald WI, Franklin RJM. Demyelinating diseases. In: Graham DI, Lantos PL, editors. Greenfield's neuropathology. Vol. 2. 7th ed. London: Arnold; 2002.

NEW PEER REVIEWERS

Join our team of expert peer reviewers for the Neurosciences Journal by sending an enquiry and summarized CV to info@smj.org.sa. Note that NSJ reviewers, whose reviews are returned on time and are judged satisfactory by the Editors, may receive 1 CME credit per review, with a maximum of 5 credits per year, from the Saudi Council for Health Specialties.