

# Accompaniment of Tourette syndrome and neuropsychiatric symptoms

*Murat Gulsun, MD, M. Alpay Ates, MD, Ayhan Algul, MD, Cengiz Basoglu, MD.*

## ABSTRACT

متلازمة تورتي (TS) عبارة عن اضطراب نفسي عصبي تم تصنيفه بواسطة الحلجات المتعددة للجهاز الحركي وبخلجة واحدة بؤرية أو أكثر. قد تكون حالة نقص الانتباه والاضطراب الوسواسي القهري ومشاكل الشخصية والاندفاعية مصاحبة لمتلازمة تورتي (TS). حددت الدراسات التصويرية العصبية والوظيفية أن منطقة المخطط البطني أكثر المناطق المتأثر من الدماغ في متلازمة تورتي (TS). لقد أبلغنا عن حالة تعاني من متلازمة تورتي والتي تعاني من ضمور مخيخي وجيب عنكبوتي مخيخي وخاصة (غياب الشعر) مثلثة خلقية على الجانبين وحول على الجانبين و تدبب الرأس. لم يتم وصف العلاقة بين هذه الأعراض ومتلازمة تورتي (TS) حتى الآن. يجب دراسة فحص احتمالية علاقة هذه الأعراض عن طريق القيام بالمزيد من الدراسات.

Tourette syndrome (TS) is a neuropsychiatric disorder characterized by multiple motor tics and one or more vocal tics. Attention deficit, obsessive-compulsive disorder, personality problems, and impulsivity may be associated with TS. Functional neuro-imaging studies indicate that the ventral striatum is the most affected brain area in TS. We report a case with TS who had cerebellar atrophy, cerebellar arachnoid cyst, bilateral congenital triangular alopecia, bilateral strabismus, and oxycephaly. The association among these symptoms and TS is rare, and the possible relationship of these symptoms should be investigated with further studies.

*Neurosciences 2009; Vol. 14 (3): 287-289*

*From the Psychiatry Service (Gulsun), Isparta Military Hospital, Isparta, and the Psychiatry Service (Ates, Algul, Basoglu), Gata Haydarpaşa Training Hospital, Istanbul, Turkey.*

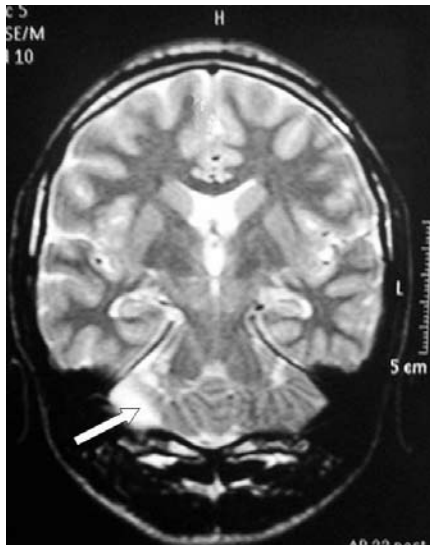
*Received 14th June 2008. Accepted 28th February 2009.*

*Address correspondence and reprint request to: Dr. Murat Gulsun, Psikiyatri Servisi, Isparta Asker Hastanesi, Isparta, Turkey. Tel. +90 (246) 2241165. E-mail: mgulsun@gmail.com*

**T**ourette Syndrome (TS) is a neurobehavioral condition that can be diagnosed if an individual exhibits multiple motor tics and at least one vocal tic, if the tics started before the age of 18 years, and if the tics are not due to substance use or a general medical condition. The tics occur many times a day (usually in bouts), nearly every day or intermittently throughout a period of more than one year, and there was never a tic-free period of more than 3 consecutive months.<sup>1</sup> Patients with TS exhibit higher rates of other disorders, such as attention-deficit hyperactivity disorder (ADHD),<sup>2</sup> obsessive-compulsive disorder (OCD),<sup>3</sup> learning disabilities,<sup>4</sup> anxiety and depressive disorders.<sup>5</sup> However, some studies have suggested that the imaging methods have revealed volume changes and asymmetries in the basal ganglia of these patients.<sup>6</sup> We report a case with TS who had cerebellar atrophy, cerebellar arachnoid cyst, and bilateral congenital triangular alopecia, bilateral strabismus, and oxycephaly. In this article, we aim to point out the necessity of the further investigations including the possible relationship of these symptoms.

**Case Report.** A 21-year-old, single, right-handed male patient was diagnosed with TS at age 11 following a febrile disease. His family history was non-specific, and he also had an attention deficit hyperactivity disorder (ADHD). He was uncomfortable in social situations and had immense anxiety about having tics, especially when meeting people he never met before. In addition, he suffered from obsessive thought, vocal, and motor tics in his face and neck for years. He had problems with falling asleep, and usually could only sleep after lots of compulsive acts. He constantly moved his head in an attempt to make it feel better while walking, and

**Disclosure.** Written consent was obtained from the patient for publication of his details. This report did not receive any funding and the authors have no potential conflicts of interest that are directly relevant to the contents of this report.



**Figure 1** - Cranial MRI showing disorganization, and interdigitation in the cerebellum. There was remarkable elongation in his hypogenetic vermis (arrow) and fourth ventricle.

this action bothered him. In his medical history, he experienced an ictal period due to an unknown febrile disease when he was 2 years old. He was hospitalized when he was 11 years old because of his motor and vocal tics, learning and concentration disability, and was diagnosed as TS and ADHD 10 years ago. At the same time, subarachnoid cysts were shown on his brain MRI (1.5 x 3 cm), and he was treated with haloperidol (0.5 mg per oral). However, he did not receive adequate medication until later. In our clinic, physical examination revealed that his physical appearance was consistent with his chronological age. He had an oxycephaly, bilateral strabismus, and bilateral congenital triangular alopecia (CTA) (2 x 4 cm). Blood, hematological, and endocrinological tests yielded normal results. His cranial MRI showed disorganization, and interdigitation in the cerebellum. There was remarkable elongation in his hypogenetic vermis and fourth ventricle. These findings were consistent with cerebellar dysplasia. (Figure 1) There were no pathologic findings on his EEG; however; there were occasional occipital deceleration signs. With these above findings, the consultant neurologist did not diagnose any specific neurological disorder. His initial Hamilton Anxiety Score (17-Item HAM-A)<sup>7</sup> was 36. The total score of the Yale-Brown Obsessive Compulsive Scale (Y-BOCS)<sup>8</sup> was 28. Our diagnosis was TS, OCD, and ADHD according to the Diagnostic and Statistical Manual of Mental Disorders. We started therapy with quetiapine 100 mg/day and sertraline 50 mg/day. The quetiapine dose was kept constant, and the sertraline dose was increased to 100 mg/day within a 2-month period. Two months later, The HAM-A score regressed

from 36 to 16, and the total YBOCS score regressed from 28 to 11. His vocal tics and motor tics were significantly diminished.

**Discussion.** Classically, the cerebellum has been known to play a role in the coordination of voluntary movement, speech, and gait, especially in motor functions and posture.<sup>9,10</sup> In the last decade, some authors have suggested that the cerebellum may have a role to play in cognition, behavior, and psychiatric disorders. Functional neuro-imaging studies point out that the ventral striatum is the most affected brain area in TS. Leckman et al<sup>11</sup> pointed out that cortico-striato-thalamo-cortical circuit may play role in the pathobiology of TS. In addition, there are studies that demonstrate volume changes in the basal ganglia. The cerebellar vermis abnormalities in patients with TS and ADHD were also reported,<sup>12</sup> like in our patient. Cerebellar cortical atrophy, and especially cerebellar atrophy may easily play a role in learning disability, motor discoordination, tic symptoms, and dysarthric speech in our patient. Additionally, the patient had bilateral CTA, also called temporal triangular alopecia, comprising of a hairless patch involving the temporal region in a triangular shape;<sup>13</sup> CTA were reported in association with neurological defects.<sup>14</sup> The aforementioned neurological deficits in our patients were compatible with this knowledge. Moreover, he had bilateral strabismus, and the oxycephaly attracted attention. Literature on the relationship of these symptoms including strabismus, oxycephaly, CTA, cerebellar atrophy, cerebellar arachnoid cyst, and TS, is rare, and the possible association of these conditions should be investigated.

In conclusion, the etiology of TS has not been clarified yet. Tourette's syndrome is known as a neurological based disorder, but we do not have conclusive evidence which lesion causes which symptoms in TS. Therefore, the neurological and abnormal MRI findings of the patient may be an inspiration for researchers in this field.

**Acknowledgment.** *We would like to thank Dr. Sebahattin Sari for evaluating the MRI photographs used in this case report.*

## References

1. American Psychiatric Association. Diagnostic and Statistical Manual of Mental Disorders 4th ed. Washington (DC): American Psychiatric Association; 2000.
2. Comings DE, Comings BG. Tourette syndrome: clinical and psychological aspects of 250 cases. *Am J Hum Genet* 1985; 37: 435-450.
3. Dedmon R. Tourette Syndrome in children: knowledge and services. *Health Soc Work* 1990; 15: 107-115.
4. Zohar AH, Apter A, King RA, Pauls DL, Leckman JF, Cohen DJ. Epidemiological studies. In: Leckman JF & Cohen DJ, editors. *Tourette's Syndrome: Tics, Obsessions, Compulsions: Developmental Psychopathology and Clinical Care* New York (NY): John Wiley; 1999. p. 23-41.

5. Pitman RK, Green RC, Jenike MA, Mesulam MM. Clinical comparison of Tourette's Disorder and obsessive-compulsive disorder. *Am J Psychiatry* 1987; 144: 1166-1171.
6. Moriarty J, Varma AR, Stevens J, Fish M, Trimble MR, Robertson MM. A volumetric MRI study of Gilles de la Tourette's syndrome. *Neurology* 1997; 49: 410-415.
7. Williams JB. A structured interview guide for Hamilton Depression Rating Scale. *Arch Gen Psychiatry* 1988; 45: 742-747.
8. Goodman WK, Price LH, Rasmussen SA, Mazure C, Fleischmann RL, Hill CL, et al. The Yale-Brown Obsessive-Compulsive Scale. I. Development, use, and reliability. *Arch Gen Psychiatry* 1989; 46: 1006-1011.
9. Botez MI, Botez T, Elie R, Attig E. Role of the cerebellum in complex human behavior. *Ital J Neurol Sci* 1989; 10: 291-300.
10. Ghez C, Fahn S. The cerebellum. In: Kandel ER, Schwartz JH, editors. Principles of Neural Science. 2nd ed. New York (NY): Elsevier; 1985. p. 502-522.
11. Leckman JF, Peterson BS, Anderson GM, Arnsten AF, Pauls DL, Cohen DJ. Pathogenesis of Tourette's syndrome. *J Child Psychol Psychiatry* 1989; 38: 119-142.
12. Mostofsky SH, Reiss AL, Lockhart P, Denckla MB. Evaluation of cerebellar size in attention-deficit hyperactivity disorder. *J Child Neurol* 1998; 13: 434-439.
13. Happle R. Congenital triangular alopecia may be categorized as a paradominant trait. *Eur J Dermatol* 2003; 13: 346-347.
14. Ruggieri M, Rizzo R, Pavone P, Baieli S, Sorge G, Happle R. Temporal triangular alopecia in association with mental retardation and epilepsy in a mother and daughter. *Arch Dermatol* 2000; 136: 426-427.

#### Related topics

Alhamad AM. Gilles de la Tourette syndrome treated effectively with clozapine. *Neurosciences* 2003; 8: 198-200.

Adeloye A, Alhamad A. Gilles de la Tourette syndrome treated effectively with Clozapine. *Neurosciences* 2004; 9: 129-129.

Dooley JM. Tics and Tourette syndrome in childhood. *Neurosciences* 2008; 13 (Suppl 1): 26.