Hypothalamic hamartoma presenting with gelastic seizures, generalized convulsions, and ictal psychosis

Hassan J. Al-Hail, *MBBS, Facharzt,* ***Tag-Eldin O. Sokrab,*** *MD, PhD,* ***Nasir J. Al-Moslamani,*** *MBBS, Facharzt,*
Francisco R. Miyares, *MD.*

ABSTRACT

في هذا التقرير نقدم حالة نادرة من ورم نسيج الهمارتوما المقترن بالهيبوثلاماس عند أنثى بالغة بدت أعراضها السريرة بهجمات ضحك قهري صرعى وتشنجات صرعيه عامة مصحوبة أحيانا بنوبات ذهانية عقلية صرعيه تتميز بتصرفات عدائية شرسة. لم تنجح العقاقير المهدئة ولا مضادات الصرع في السيطرة على الحالة المرضية. أجريت لها عملية جراحية بعد 3 عقود من بداية المرض بعد التحقق من وجود الورم باستخدام التصوير بالرنين المغناطيسي ونتج عن ذلك تحسن ملحوظ في جميع الأعراض المرضية. هذا التقرير يبين أن التأخر في تشخيص المرض يمكن أن يطيل معاناة المريض من مرض يتوفر علاجه.

We report a case of hypothalamic hamartoma in an adult female who presented with gelastic seizures, generalized convulsions, and ictal aggressive psychotic behavior. Anticonvulsant treatment was ineffective in controlling the epileptic seizures. Surgical excision after accurate imaging diagnosis 3 decades after the onset of symptoms markedly ameliorated her condition. Delayed and erroneous diagnosis had unnecessarily prolonged the suffering of our patient.

Neurosciences 2010; Vol. 15 (1): 43-45

From the Department of Neurology (Al-Hail, Sokrab, Miyares) Hamad General Hospital, Doha, and the Department of Radiology (Al-Moslamani), Al-Khor Hospital, Al-Khor, Qatar.

Received 6th July 2009. Accepted 8th September 2009.

Address correspondence and reprint request to: Dr. Hassan J. Al-Hail, Department of Neurology, Hamad General Hospital, PO Box 3050, Doha, Qatar. E-mail: Qat710@yahoo.com

Hypothalamic hamartomas (HH) are rare tumor-like heterotopic masses commonly found in the hypothalamus or tuber cinereum.[1] They typically present in childhood with gelastic seizures and precocious puberty. Occasionally the condition can be associated with intractable convulsive epilepsy and behavioral abnormalities.[2] The most effective treatment is surgical removal of the HH.[3] The aim of this case report is to alert the physician to early diagnosis of the condition and to prevent suffering in a manageable disease.

Case Report. This case is a 30-year-old right-handed Qatari female patient. The epileptic symptoms started at the age of 3½ years. Her preceding childhood development was unremarkable. In school, her performance was poor and she discontinued school in the second year after admission because of the seizures and cognitive difficulties. The clinical symptoms started with bouts of involuntary and irresistible laughter and dropping to the floor (gelastic seizures). Later in adulthood she started to develop other seizures of different semiology. Those seizures typically started with a brief period of oro-facial automatism in the form of repeated smiling followed by loss of consciousness and generalized tonic clonic convulsions. The ictus duration was usually less than 10 minutes and recurred up to 4 times per month. She had sustained many body injuries related to the seizures. Infrequently, she had minor seizures limited to an episode of repeated smiling for a few seconds or a drop to the ground. The seizures were not controlled by antiepileptic drugs despite taking twice daily doses of levetiracetam 1000 mg, carbamazepine 400 mg, and primidone (Mysoline) 250 mg. Occasionally, she developed sudden outbursts of aggressive and agitated behavior independently of the other seizures. She expressed rage, violence, and paranoid ideations. She destroyed furniture and TV apparatus in different violence incidences. The psychotic outburst might persist for up to one hour. After the attack had settled, she had no recall of how she had acted during the event. In-between the attacks, she depicted a quiet

Disclosure. The authors declare that they have no conflicting interests and they are not funded or supported by any drug company.

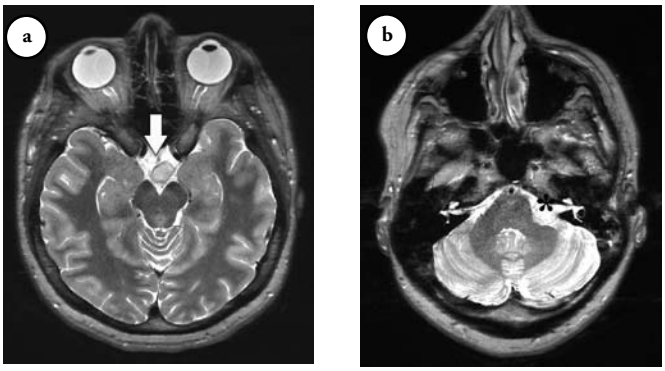

Figure 1 - Patient MRI **a**) T2 weighted showing a hypothalamic hamartoma (arrow) and **b**) 3T showing an incidental small left vestibular schwannoma (asterisk).

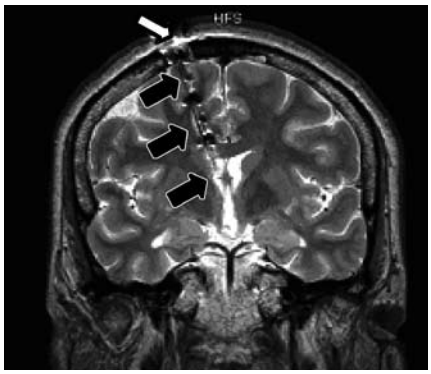

Figure 2 - An MRI of the brain after surgical resection of the hamartoma showing the left craniotomy (white arrow) and the transcallosal endoscopy tract (black arrows).

and a pleasant character. Erroneously she was thought to have a primary psychotic disorder and was treated by a psychiatrist for a long time, which had greatly delayed the right diagnosis. Psychotropic agents were ineffective in suppressing the aggressive psychotic symptoms. All other forms of seizures were refractory to drug treatment. Her neurological examination was unremarkable except for a moderate cognitive impairment. Video-EEG demonstrated non-localizing ictal pattern with maximum amplitude in bifrontal regions. The 3T-MRI demonstrated an oblong 1.2 x 2.5 mm, well demarcated soft tissue mass, iso-intense to the grey matter, in the region of the hypothalamus (**Figure 1**). The lesion was partly intrahypothalamic with an extension below the hypothalamus. No enhancement was seen on the post-gadolinium images. An incidental small left vestibular schwannoma was seen on the MRI (**Figure 1**). Based on the characteristic imaging features, lack of enhancement and typical location, the diagnosis of HH was considered. The tumor was surgically reached and resected by a transcallosal endoscopic approach via a left craniotomy (**Figure 2**). Histopathological examination of the surgical material confirmed that the mass was a hamartoma. She developed a transient diabetes insipidus as a complication of the surgery. Postoperatively, she was regularly seen at the outpatient epilepsy clinic for neurological assessment and treatment. By the time of writing this report, she was followed up for more than one year. The seizure frequency had regressed by more than 50% after surgery. The psychotic symptoms had completely subsided. She continued to take anticonvulsant drugs, and the dosages were adjusted as needed.

Discussion. Le Marquand and Russell[4] were the first to describe HH in a child with precocious puberty.[4] They are rare developmental heterotopic non-neoplastic tumor-like masses most commonly found in the region of the hypothalamus and the tuber cinereum. The HH are either intrahypothalamic (sessile), or parahypothalamic (pedunculated) attached to the hypothalamus. Morphologically, hamartomas are composed of glial cells and neurons that morphologically resemble the normal cells of the hypothalamus and tuber cinereum. The intrathalamic hamartoma usually presents with epilepsy, while the pedunculated variety presents with precocious puberty.[1] The location of the tumor, iso- or slight hypointensity on T1-weigted images, hyperintensity on T2-weighted images, and lack of gadolinium enhancement are characteristic MR features that strongly support the diagnosis of HH.[5] Our patient presented with gelastic seizures in her early childhood, which is the typical early clinical presentation of sessile HH. Later in the course of epilepsy, the gelastic component often becomes less prominent and other types of generalized or partial seizures may appear. The epileptic syndromes that may develop in adolescence or adulthood include generalized tonic clonic, secondary generalized tonic clonic, tonic, atonic, and complex partial seizures.[2] The HH can lead to impairment of cognition, which may interfere with the learning process and schooling.[6] Gelastic epilepsy in HH is known to be associated with ictal and interictal behavioral abnormalities mainly aggression, paranoid ideation, and major affective disorders. Ictal psychosis is usually episodic and associated with generalized seizures.[6-8] Interictal psychosis is more chronic however; it has a benign course and better response to treatment.[8] The seizures associated with HH are often described as catastrophic because of its refractoriness to treatment with anticonvulsants. However, the progressive epilepsy, behavioral, and cognitive deterioration can be ameliorated by surgical intervention. Several surgical procedures are used to reach the HH.[9] The tumor was successfully removed in our patient by endoscopic

resection, resulting in a remarkable improvement in epileptic seizures and psychotic symptoms after several decades of suffering.

In conclusion, the HH is a rare tumor that has characteristic clinical features and can cause intractable epilepsy of multiple semiologies. Unfortunately the diagnosis of HH, a condition that can be ameliorated by surgical intervention, is often delayed particularly in developing countries.[10] A protracted course of suffering can be avoided if the condition is considered in every case of gelastic seizures or precocious puberty.

References

1. Coons SW, Rekate HL, Prenger EC, Wang N, Drees C, Ng Y, et al. The histopathology of hypothalamic hamartomas: study of 57 cases. ***J Neuropathol Exp Neurol*** 2007; 66: 131-141.
2. Castro LH, Ferreira LK, Teles LR, Jorge CL, Arantes PR, Ono CR, et al. Epilepsy syndromes associated with hypothalamic hamartomas. ***Seizure*** 2007; 16: 50-58.
3. Téllez-Zenteno JF, Serrano-Almeido C, Moien-Afshari FM. Gelastic seizures associated with hypothalamic hamartomas. An update in the clinical presentation, diagnosis, and treatment. ***Neuropsych Dis Treat*** 2008; 4: 1021-1031.
4. Le Marquand HS, Russell DS. A case of pubertas praecox in a boy associated with a tumour in the floor of the third ventricle. ***Royal Berkshire Hospital Report*** 1934; 3: 31-61.
5. Freeman JL, Coleman LT, Wellard RM, Kean MJ, Rosenfeld JV, Jackson GD, et al. MR Imaging and spectroscopic study of epileptogenic hypothalamic hamartomas: analysis of 72 cases. ***AJNR Am J Neuroradiol*** 2004; 25: 450-462.
6. Prigatano GP. Cognitive and behavioral dysfunction in children with hypothalamic hamartoma and epilepsy. ***Semin Pediatr Neurology*** 2007; 14: 65-72.
7. Veendrick-Meekes MJ, Verhoeven WM, van Erp MG, van Blarikom W, Tuinier S. Neuropsychiatric aspects of patients with hypothalamic hamartomas. ***Epilepsy Behav*** 2007; 11: 218-221.
8. Kanner AM. Recognition of the various expressions of anxiety, psychosis, and aggression in epilepsy. ***Epilepsia*** 2004; 45 Suppl 2: 22-27.
9. Ng YT, Rekate HL, Prenger EC, Wang NC, Chung SS, Feiz-Erfan I, et al. Endoscopic resection of hypothalamic hamartomas for refractory symptomatic epilepsy. ***Neurology*** 2008; 70: 1543-1548.
10. Papayannis CE, Consalvo D, Seifer G, Kauffman MA, Siva W, Kochen S. Clinical spectrum and difficulties in management of hypothalamic hamartoma in a developing country. ***Acta Neurol Scand*** 2008; 118: 313-319.

ILLUSTRATIONS, FIGURES, PHOTOGRAPHS

Four copies of all figures or photographs should be included with the submitted manuscript. Figures submitted electronically should be in JPEG or TIFF format with a 300 dpi minimum resolution and in grayscale or CMYK (not RGB). Printed submissions should be on high-contrast glossy paper, and must be unmounted and untrimmed, with a preferred size between 4 x 5 inches and 5 x 7 inches (10 x 13 cm and 13 x 18 cm). The figure number, name of first author and an arrow indicating "top" should be typed on a gummed label and affixed to the back of each illustration. If arrows are used these should appear in a different color to the background color. Titles and detailed explanations belong in the legends, which should be submitted on a separate sheet, and not on the illustrations themselves. Written informed consent for publication must accompany any photograph in which the subject can be identified. Written copyright permission, from the publishers, must accompany any illustration that has been previously published. Photographs will be accepted at the discretion of the Editorial Board.