

Malignant cutaneous melanoma associated with cerebral venous sinus thrombosis

Keivan Basiri, MD, Masoomeh Dashti, MD, Farzad Fatehi, MD.

ABSTRACT

يعد تخثر الجيب الوريدي الدماغى (CVST) مرض نادر يسجل حوالي 1% من حالات الجلطات. يظهر عن طريق تخثر الدم في الوريد الدماغى، أو الجيوب الجافورية مثل الأوردة القشرية. نصف هنا حالة نادرة لورم خبيث مع تخثر جيبي وريدي دماغى (CVST). كان تشخيص الحالة مشبوّه به طبقاً للنتائج السريرية، والتصوير المقطعي للدماغ CT، وأخيراً تم تأكيد التشخيص بواسطة أشعة الرنين المغناطيسى MRI. بدأ العلاج بحقن الهيبرين بالوريد مباشرة، ولكن لسوء الحظ توفي المريض بعد أسبوع من إدخاله المستشفى. نشير أن حالة فرط التخثر الناتجة عن الورم الخبيث والتي أنتجت تخثر جيبي وريدي دماغى (CVST) حيث أن أشعة الرنين المغناطيسى MRI للدماغ لم تشير إلى أي دليل لثقيلة الدماغ. لهذا حدث الانقسام المباشر لجيب الورم النادر الحدوث. ومن ناحية أخرى، يجب أن لا نحذف الدور المحتمل لثقيلة المنظار الجيبية.

Cerebral venous sinus thrombosis (CVST) is an infrequent disease (representing around 1% of all strokes) manifested by clotting of blood in cerebral venous or dural sinuses as well as cortical veins. Herein, we describe an unusual case of malignant melanoma presenting with CVST in whom the diagnosis of CVST was suspected on the basis of clinical findings along with brain CT scan, and finally was confirmed by brain MRI and magnetic resonance venography. Intravenous heparin treatment was started immediately; but unfortunately the patient died one week after hospitalization. We suggest that the hypercoagulable state provoked by malignant melanoma generated the CVST as brain MRI did not indicate any evidence of brain metastasis; therefore, direct invasion of the sinus by the tumor is less likely; on the other hand, we should not omit the possible role of microscopic sinus metastasis.

Neurosciences 2010; Vol. 15 (3): 190-192

From the Neurology Department (Basiri, Dashti, Fatehi), and the Isfahan Neurosciences Research Center (Basiri, Fatehi), Isfahan University of Medical Sciences, Isfahan, Iran.

Received 15th November 2009. Accepted 18th January 2010.

Address correspondence and reprint request to: Dr. Farzad Fatehi, Neurology Department, Isfahan Neurosciences Research Center and Medical Education Research Center, Isfahan University of Medical Sciences, Isfahan, Iran. Tel. +98 (913) 3186330. E-mail: fatehi@edc.mui.ac.ir / farzad_fatehi@yahoo.com

Cerebral venous sinus thrombosis (CVST) is an infrequent disease representing around 1% of all strokes, manifested by clotting of blood in the cerebral venous or dural sinuses as well as cortical veins; noticeably, the day-by-day list of CVST causes is increasing.¹⁻³ Herein, we describe an unusual case of malignant melanoma presenting with CVST; the diagnosis of CVST was suspected on the basis of clinical findings and brain CT scan, and finally was confirmed by brain MRI and magnetic resonance venography (MRV). Noticeably, CVST has been described accompanying a great many of the malignancies; however, description in association with melanoma has been scarce.

Case Report. A 47-year-old man presented with a one week history of headache, dysarthria, and focal seizure in his left hand. He had a history of cutaneous melanoma for the previous year, which had started on the plantar aspect of his right foot and had progressed to his upper thigh, lower abdomen, and scrotum. General physical examination (excluding skin examination), vital signs, as well as mental status examination were normal. Cranial nerves were intact except for mild bilateral papilledema. Reduced strength and extensor plantar reflex were detected on the left side of the body. On skin examination, multiple hyperpigmented giant macules, papules, and nodules over the entire right foot, leg, lower area of abdomen, and scrotum were detected (Figure 1). Some of the lesions had eroded and had discharge. For the evaluation of seizure and headache, brain CT scan was performed and showed an extensive hypodense lesion in the right temporoparietal area with mild mass effect. Further brain MRI (FLAIR sequence) demonstrated a high signal lesion in the right temporoparietal lobe in conjunction with mild mass effect (Figure 2a), and hyper-signal foci on T1W image indicating hemorrhagic infarction. On brain MRV, filling defects in both transverse sinuses with superficial cortical vein thrombosis, mostly on the right side was noted (Figure 2b). These findings confirmed hemorrhagic infarction due to cerebral venous thrombosis. Laboratory evaluations showed no evidence of a thrombophilic

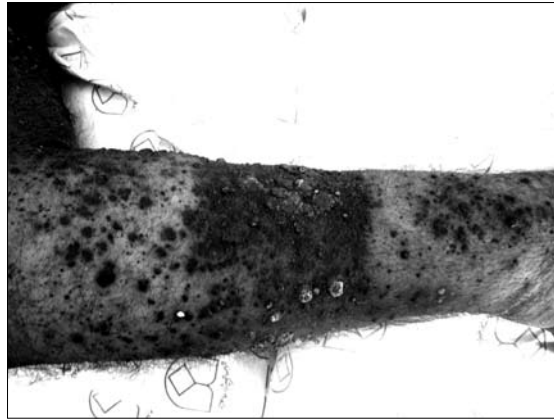
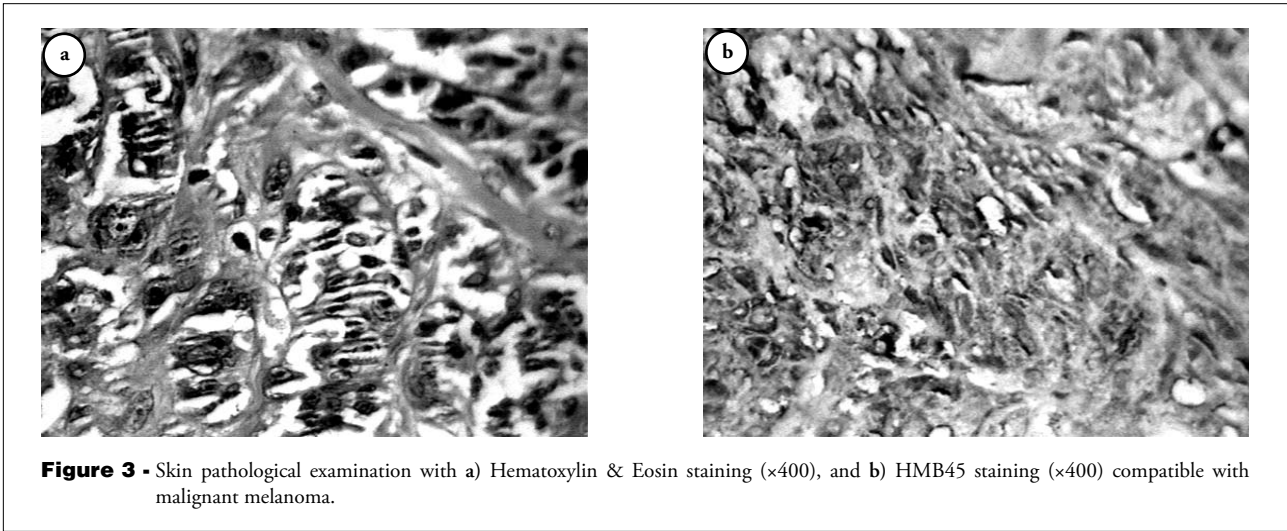
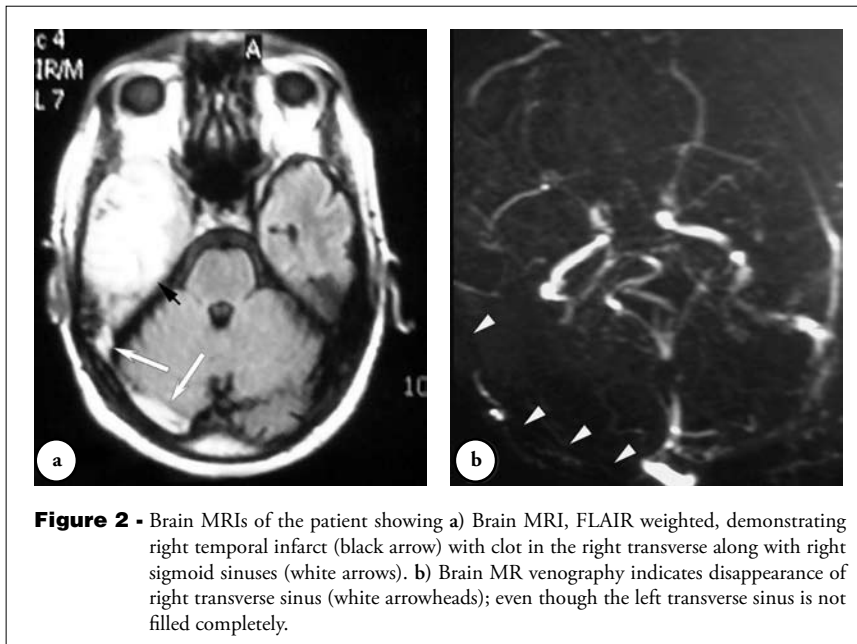


Figure 1 - Extensive melanoma of the right leg.



coagulopathy. Intravenous heparin treatment was started immediately to keep partial thromboplastin time at 60-70 seconds. His level of consciousness reduced on day 3, and he went into a deep coma on day 4, and unfortunately died one week after hospitalization. A brain CT scan on day 3 did not reveal any new gross lesion, such as new hemorrhage, and the death might have been attributed to the progression of the CVST itself. Further pathological examination of the skin was compatible with malignant melanoma (Figure 3). A brain autopsy was not performed, as the family did not consent.

Discussion. The earliest detailed description of CVST appeared in 1825, in France, which was attributed to systemic malignancy.⁴ Systemic thrombosis is well recognized in patients with malignancy,¹ and around one-fifth of patients with cancer have cerebrovascular lesions stemming from direct effects of the tumor itself, coagulation disorders, or therapeutic interventions.¹ It is significant that the demonstration of an underlying prothrombotic condition in CVST could have imperative consequences in terms of prevention, since prompt management of the etiology could save the patient's life and avert further disabilities.^{1,5}

The CVST can be accompanied by many types of malignancies including squamous cell metastatic cervical mass, non-Hodgkin's lymphoma, bilateral glomus tumor, colorectal cancer, epidermoid carcinoma of the tongue, dysgerminoma, and Ewing's sarcoma.¹ It is noticeable that CVST has also been described in association with brain tumors, particularly meningioma and oligodendroglioma, due to local invasion by the tumor itself.^{1,6} Schnittger et al⁷ described a 20-year-old woman with neurocutaneous melanoblastosis presenting with CVST.

Brain metastasis is frequent in patients with malignant melanoma and represents a significant cause of morbidity and mortality. Almost one-third of patients with malignant melanoma finally suffer from brain metastasis, and autopsy reports demonstrate that 75% of those who died of melanoma developed brain metastasis.⁸

Our patient had thrombosis of the transverse sinuses associated with superficial cortical vein thrombosis.

We suggest that the hypercoagulable state provoked by malignant melanoma generated the CVST; as brain MRI did not indicate any evidence of brain metastasis; therefore, direct invasion of the sinus by the tumor is less likely; however, we should not omit the possible role of microscopic sinus metastasis.

In conclusion, in patients suffering from a malignancy or brain tumor, the diagnosis of CVST might be intricate; however, a high level of clinical suspicion in combination with the assistance of neuroimaging, such as brain MRI and MRV, could guide us to the prompt and proper diagnosis. Furthermore, it is crucial to exclude CVST in any patient presenting with new neurological deficits and history of malignancy; in other words, it seems plausible not only to exclude brain metastasis in a patient with the history of malignancy and neurological deficits, but also to investigate for the possibility of CVST as the ominous cause for the patient's neurological manifestations.

References

1. Saadatnia M, Fatehi F, Basiri K, Mousavi SA, Mehr GK. Cerebral venous sinus thrombosis risk factors. *Int J Stroke* 2009; 4: 111-123.
2. Fatehi F, Saadatnia M, Zare M. Cerebral venous sinus thrombosis following tamoxifen prescription. *Neurosciences* 2008; 13: 320.
3. Kajtazi NI, Zimmerman VA, Arulneyam JC, Al-Shami SY, Al-Senani FM. Cerebral venous thrombosis in Saudi Arabia. Clinical variables, response to treatment, and outcome. *Neurosciences* 2009; 14: 349-354.
4. Ribes FM. Des recherches faites sur la phlébitis. *Rev Med Franc Etrang* 1825; 3: 5-41.
5. Mouton S, Nighoghossian N, Berruyer M, Derex L, Philippeau F, Cakmak S, et al. Hyperthyroidism and cerebral venous thrombosis. *Eur Neurol* 2005; 54: 78-80.
6. Fatehi F, Basiri K, Saadatnia M, Koleini N. Cerebral venous thrombosis associated with oligodendroglioma and pregnancy. *Neurosciences* 2009; 14: 277-279.
7. Schnittger C, Kolbe H, Fedorowski A, Heidenreich F. Neurocutaneous melanoblastosis associated with cerebral sinus venous thrombosis. *J Neurol* 1999; 246: 218-220.
8. Sloan AE, Nock CJ, Einstein DB. Diagnosis and treatment of melanoma brain metastasis: a literature review. *Cancer Control* 2009; 16: 248-255.

Related topics

Idris MA, Sokrab TO, Ibrahim EA, Mirgani SM, Elzibair MA, Osman RR, Abdalatif M. Cerebral venous thrombosis. Clinical presentation and outcome in a prospective series from Sudan. *Neurosciences* 2008; 13: 408-411.

Fatehi F, Saadatnia M, Zare M. Cerebral venous sinus thrombosis following tamoxifen prescription. *Neurosciences* 2008; 13: 320.

Gowri V, Mathew M, Galaal KA, Jain R. Postpartum cerebral vein thrombosis. *Neurosciences* 2005; 10: 93-95.