

# Thyroiditis of Hashimoto and myotonia

*Aouatef El-Midaoui, MD, Saïd A. Boujraf, MD, PhD, Mohammed F. Belabsen, MD, Ouafae Messouak, MD.*

## ABSTRACT

يرتبط القصور الدرقي عادة ببعض الاضطرابات العصبية والعضلية؛ إلا أن أعراض الميوتونيا العضلية والعصبية (myotonia) نادرة ما تكشف عن هذا المرض. نستعرض في هذا المقال حالة سيدة تبلغ من العمر 45 عاما كانت تعاني من قصور في الغدة الدرقية وذلك بعد إصابتها بالتهاب الدرقية هاشيموتو وبأعراض الميوتونيا في مراحلها المتطورة. كشفت اختبارات الدم عن وجود قصور درقي محيطي (peripheral hypothyroidism) ناتج عن التهاب الدرقية هاشيموتو حيث كان معدل هرمون الثيروكسين الحر (FT4) منخفضا، بينما كان معدل هرمون الغدة الدرقية (TSH) مرتفعا، كما أن الأجسام المضادة للأنتيزيم الدرقي ثيروبيروكسيديز كانت مرتفعة، ولهذا تلقت المريضة علاجاً بديلاً لهرمون الثيروكسين مما أدى إلى تحسن حالتها. يعد التهاب الدرقية هاشيموتو من أكثر الأمراض التي تسبب القصور الدرقي، فيما تتراوح نسبة حدوث أعراض الميوتونيا العصبية والعضلية خلال هذا المرض ما بين 30-80%. تتمثل الأعراض الرئيسية التي تكشف عن المرض في الشعور بالإرهاق، وشد وآلام عضلية، وقد تكشف أعراض الميوتونيا عن المرض غير أن آليتها ومراحل تدرجها لا تزال مبهمة. يؤدي العلاج الهرموني إلى تحسن حالات المرضى المصابين بالقصور الدرقي الناتج عن التهاب الدرقية هاشيموتو وهذا يحتم علينا القيام بفحص الدم دورياً لقياس معدل هرمونات الغدة الدرقية وخصوصاً إذا كانوا مصابين ببعض الأعراض العصبية والعضلية.

Hypothyroidism is frequently associated with different neuromuscular disorders. However, myotonia is rarely a revealing feature. We report a case of hypothyroidism secondary to Hashimoto's thyroiditis and myotonia. The patient is a 45-year-old woman who consulted for a progressive myotonia. Blood and thyroid assessments revealed peripheral hypothyroidism with low free thyroxine, high thyroid-stimulating hormone levels and high titers of anti-thyropoxidase antibodies. Outcome was favorable with thyroid hormone substitution. Hashimoto's thyroiditis is a common cause of hypothyroidism. The frequency of myopathy during hypothyroidism ranges from 30-80%. The main symptoms related are weakness, muscular cramps, and myalgia. Myotonia may reveal hypothyroidism. The pathogenic mechanism of this myotonia is still unknown. Good outcome of hypothyroid manifestations with thyroid hormone substitution requires systematic thyroid hormone screening in patients presenting with neuromuscular manifestations.

*Neurosciences 2010; Vol. 15 (4): 284-286*

*From the Department of Neurology (El-Midaoui), Laboratory of Biophysics and Clinical MRI Methods (Boujraf, Belabsen, Messouak), and the Laboratory of Clinical Neurosciences (Boujraf), Faculty of Medicine and Pharmacy, University of Fez, Fez, Morocco.*

*Received 12th April 2010. Accepted 15th August 2010.*

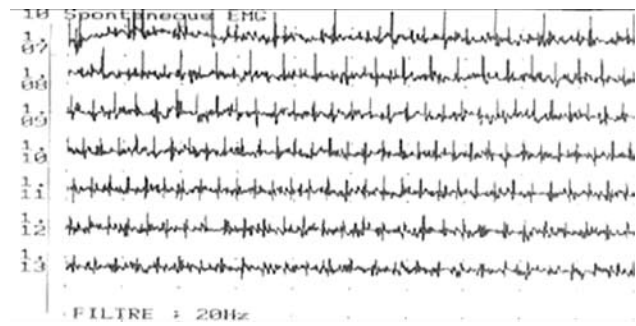*Address correspondence and reprint request to: Prof. Saïd A. Boujraf, Department of Biophysics and Clinical MRI Methods, Faculty of Medicine and Pharmacy, University of Fez, BP 1893, Km 2.200, Sidi Hrazem Road, Fez 30000, Morocco. Tel. +212 (667) 780442. Fax. +212 (535) 619321. E-mail: sboujraf@gmail.com*

The thyroiditis of Hashimoto also known as chronic auto-immune thyroiditis is the most frequent cause of hypothyroidism in countries that are not suffering from iodine deficiency. This thyroid affection is characterized by lymphocytes infiltration especially dominant T lymphocytes; it might be diffuse or localized in the thyroid gland with alteration of thyroidal follicles associated with a fibrosis. The revealing elements are variable and might consist of goiter, nodule, clinical or sub-clinical signs of dysthyroid evidence.<sup>1</sup> The neurological complications of the hypothyroidism were described a long time ago and have been known to be dependent on the thyroidal state. Although the neuromuscular manifestations are frequent during the evolution of hypothyroidism, myotonia exceptionally reveals such affection.<sup>2</sup> We report a case of hypothyroidism secondary to a thyroiditis of Hashimoto revealed by myotonic manifestations, and we also discuss associated diagnostic and therapeutic features, considering the none classical revelation of hypothyroidism by myotonic symptoms.

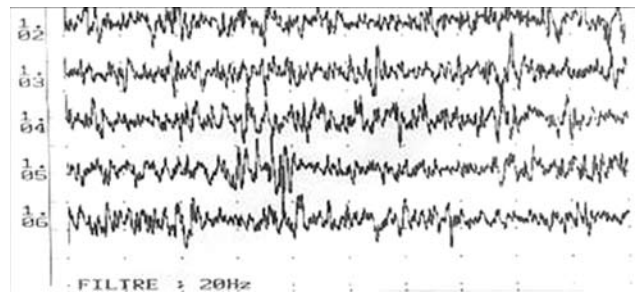
**Case Reports.** The patient is a 45-year-old female without personal and family history of noticeable neurological pathology. She was hospitalized for assessment of muscular relaxation delay without muscle cramps or myalgia, this symptomatology had evolved along the last 5 years, and affected all 4 limbs. The symptoms appeared once the movement was initiated, worsened with cold, improved with heating, and disappeared after repetitive movements.

She had no clinical signs in favor of encephalopathy or cranial nerve palsies. In addition, she reported asthenia and hoarseness of voice. The findings of her physical examination showed a pseudo-athletic aspect. There was also a spontaneous and mechanical myotonia that was activated by direct muscular percussion at the level of hands, masticators, tongue, and limbs. The muscular strength was normal, and the osteotendinous reflexes were present and symmetrical. The patient had no cranial nerve palsies. The blood count, serum electrolytes, renal balance assessment, and lipid assessment were all normal. The serum creatine phosphokinase (CPK) was increased to 1590 U/l (normal range: 24-170 U/l), electromyography (EMG) showed a myotonic discharge at rest (Figure 1) and myogenic pattern when effort is run (Figure 2). The motor and sensitive neuroconduction did not reveal any abnormalities. Considering the myotonia association and the pseudo muscular hypertrophy, the diagnosis of Becker's myotonia was suspected; however, the absence of any family history and the late age of occurrence indicated that this diagnosis was less probable. For this reason, a genetic study was not carried out. The thyroidal assessment was realized and confirmed a peripheral hypothyroidism; this showed a decreased free thyroxine (FT4) of 0.17 ng/dL (normal limit: 0.58-1.64), free triiodothyronine (FT3) was decreased to 2.37 pg/mL (normal limit: 2.50-3.90) and the serum thyrotropin (TSH) was increased to 99.86 mIU/mL (normal limit: 0.34-5.60). The anti-thyroid antibodies test was positive, anti-thyroglobulin antibody was 1000 U/L (normal range: <115 U/ml) and antithyropoxidase antibody was 815 U/L (normal range: <12 U/ml). The thyroid ultrasound showed an aspect evoking a thyroiditis. The thorax radiography, electrocardiogram, and trans-thoracic ultrasound were all normal. The diagnosis of Hashimoto's thyroiditis associated to myotonia was retained, and she was treated using a progressive dose of thyroid hormone therapy (maximum dose of levothyroxine sodium is 125 microgram/day). The evolution was favorable with disappearance of the myotonic phenomena after one year of treatment, and improvement in the thyroidal assessment. The TSH decreased to 2.1 mIU/mL, FT4 increased to 0.58 ng/dL, and FT3 to 3.36 pg/mL. The anti-thyroglobulin antibody was decreased to 207 U/L. The serum creatine phosphokinase (CPK) was increased to 450 U/L. She refused repeat EMG.

**Discussion.** Hypothyroidism is the most common thyroidal affection. It occurs in 3.5/1000/year in women and 0.6/1000/year in men.<sup>3</sup> The autoimmune etiology and mainly the Hashimoto's thyroiditis is the main cause of acquired and spontaneous hypothyroidism in adults. Considering the unspecific character of the clinical manifestations of hypothyroidism, the diagnosis of autoimmune hypothyroiditis is usually



**Figure 1** - Myotonic discharge in first dorsal interosseus muscle at rest in the electromyography.



**Figure 2** - Myogenic pattern recorded in deltoid muscle during exercise in the electromyography.

approved with consequential delay. Hashimoto's thyroiditis is an autoimmune chronic thyroiditis, which mostly arises in women with a female to male gender ratio of 6:1, it occurs in adults aged 30-60 years. This pathology is characterized by a family background, a genetic predisposition, environmental factors, and possibility of associating other autoimmune diseases. Hashimoto's thyroiditis is characterized by the presence of circulating antibodies, which are directed against thyroid antigens particularly antithyroid peroxidase antibodies.<sup>1</sup> Patients might be carriers of a firm and elastic goiter, that was initially described by Hashimoto, or an atrophic thyroid. In the initial stage, the thyroid function is mostly preserved, with 15% of cases having moderate hypothyroidism. Exceptionally, 5% of patients show a transitional thyrotoxic phase that is quickly declining or evolving towards hypothyroidism. Over time, evolution manifests towards an obvious hypothyroidism and a progressive atrophy of the thyroid gland.<sup>1</sup> The presence of considerably increased antithyroid peroxidase antibodies is characteristic of the disease. These antithyroid peroxidase antibodies and antithyroglobulin are found in >90% of cases. Thyroid-stimulating hormone receptor-blocking antibodies are rarely found in only 10-15% of cases.<sup>4</sup> The deficiency of the thyroid hormones in the auto-immune thyroiditis might have serious consequences on both the central and the peripheral nervous systems. The affection of the

central nervous systems would manifest clinically by a cerebellar ataxia, convulsive seizure,<sup>5</sup> and encephalopathy dementia.<sup>6</sup> The affection of the peripheral nervous system with neuropathy and/or myopathy is also usual (52% of cases), mostly it manifests in axonal sensory-motor polyneuropathy,<sup>5</sup> and rarely is found in carpal canal syndrome or multifocal neuropathy.<sup>6</sup> Muscular affection during the hypothyroidism is often shown in 30-80% of cases.<sup>5</sup> However, it is rare to be the only demonstration of the hypothyroidism such was the case of our patient. The typical clinical manifestations of hypothyroid myopathy consist of muscular fatigability (52% of cases),<sup>6</sup> cramps of lower limbs (42%), myalgia, and a predominant sensation of stiffness of limbs.<sup>3</sup> In most developed forms, the myalgia may be so expressive that it mimics polymyositis.<sup>6</sup> This might yield a modification of the muscular masses, which would become hypertrophied or atrophied. Four forms of hypothyroid myopathy were described: the Kocher-Debré-Semelaigne syndrome, Hoffmann's syndrome, atrophic form, and myasthenic syndrome.<sup>3</sup> Some rare observations of myotonia were previously described.<sup>1,3,6</sup> Tredici and Coletti<sup>7</sup> reported 2 cases of hypothyroidism associated with dystrophic myotonia that did not improve on hormonal substitution therapy.<sup>7</sup> Venables et al<sup>8</sup> published a case of hypothyroidism associated with pure myotonia that completely recovered after thyroid hormone therapy. Sansone et al<sup>9</sup> reported 3 patients from different families who have clinical manifestations of hyperthyroidism revealing myotonic myopathy.

The reported case in this paper is of particular interest as it showed a very poor initial clinical profile of the hypothyroidism and also very invalidating character of the myotonia. Indeed, the age of the patient when symptoms started, and the absence of familial cases make the genetic pathology hypothesis less probable. This myogenic affection is often accompanied with an increase muscular enzymes without corresponding severity of the muscular affection, and the CPK seems to be the most sensitive marker.<sup>2</sup> The EMG has a slight contribution since it often shows the normal pattern. The histology shows none specific alterations such as the loss of the myofibril striation, fibers atrophy of type II, mitochondrial abnormalities, and accumulation of glycogen and polysaccharides.<sup>3</sup> The relationship between the thyroidal hormones and muscular affection remain unclear. The good evolution of the myotonia using thyroid hormone therapy allows the evoking of a shared physiopathological mechanism, and supports the theory that this myotonia might be secondary to hypothyroidism since asymptomatic under treatment. Indeed, thyroid hormones would have a regulating role in the transcription of various genes (thyroid-hormone-responsive muscle genes) coding myofibril proteins, and calcic regulatory proteins. Regarding the skeletal muscles, studies have shown modifications in the expression of the

gene of the heavy chain of myosin during dysthyroidies. Hence, thyroid hormones control the differentiation of myocytes, and breaking this equilibrium would yield long-standing muscular degeneration. The biochemical data provide information on modifications of myosin and the activity of the pump Na/K+ATPase, as well as a decrease in carnitine.<sup>10</sup> The collected arguments show that myotonia is due to hypothyroidism that is secondary to Hashimoto's thyroiditis. The diagnosis of the thyroid myopathy is not difficult when the hypothyroidism is revealed. However, it becomes less obvious when the myopathy is foundational, and such is the case of our patient that presented with an isolated invalidating myotonia evolving for 5 years without significant clinical signs of hypothyroidism. The prognosis of the muscular manifestations during the hypothyroidism is generally good after thyroid hormone therapy. The reported case illustrates this typical favorable evolution. Thus, an early diagnosis and an adapted treatment are imperative to reach a normalization of the thyroid function, and consequently a regression of the neuromuscular symptoms.

In conclusion, myotonia is a muscular affection rarely revealing a hypothyroidism of auto-immune origin. Good prognosis using thyroidal hormones therapy motivates a systematic requirement of thyroid assessment while a myopathy is reported.

## References

1. Cardot-Bauters C, Wémeau JL. Thyroidites. In: EMC (Elsevier Masson SAS), Encyclopédie Médico-chirurgicale. Paris (France): Traité de Médecine AKOS; 2009.
2. Mrabet H, Masmoudi S, Mrabet A. [Myotonia and hypothyroidism]. *Rev Neurol (Paris)* 2007; 163: 837-839. French.
3. Hassikou H, Tabache F, Safi S, Baaj M, Hadri L. [A case of myopathy associated with hypothyroidism and hyperprolactinaemia]. *Rev Med Interne* 2007; 28: 429-431.
4. Archambeaud F, Galinat S, Regouby Y, Magy L, Rebeyrotte I, Vallat JM, et al. [Hashimoto encephalopathy. Analysis of four case reports]. *Rev Med Interne* 2001; 22: 653-659. French
5. Vasconcellos LF, Peixoto MC, de Oliveira TN, Penque G, Leite AC. Hoffman's syndrome: pseudohypertrophic myopathy as initial manifestation of hypothyroidism. Case report. *Arg Neuropsiquiatr* 2003; 61: 851-854.
6. Duyff RF, Van den Bosch J, Laman DM, van Loon BJ, Linsen WH. Neuromuscular findings in thyroid dysfunction: a prospective clinical and electrodiagnostic study. *J Neurol Neurosurg Psychiatry* 2000; 68: 750-755.
7. Tredici G, Coletti A. Dystrophia myotonica and hypothyroidism. *J Neurol* 1978; 218: 215-218.
8. Venables GS, Bates D, Shaw DA. Hypothyroidism with true myotonia. *J Neurol Neurosurg Psychiatry* 1978; 41: 1013-1015.
9. Sansone V, Griggs RC, Moxley RT 3rd. Hypothyroidism unmasking proximal myotonic myopathy. *Neuromuscul Disord* 2000; 10: 165-172.
10. Klein I, Ojamaa K. Thyroid (neuro)myopathy. *Lancet* 2000; 356: 614.