

Hemangiopericytoma of the pineal region

Askin E. Hasturk, MD, Mehmet Basmaci, MD, Nazan Bozdogan, MD, Suat Canbay, MD.

ABSTRACT

نستعرض في هذا المقال حالة فريدة من نوعها لشابة تبلغ من العمر 37 عاماً، وتعاني من ورم الخلايا الحوطية في المنطقة الصنوبرية، وقد تم استئصال الورم بنجاح بعد إجراء العملية الجراحية. يعد ورم الخلايا الحوطية من الأورام الوعائية الخبيثة التي تنشأ من خلايا اللحمية المتوسطة مع ظهور تمايز حول الشريينات، وغالباً ما تظهر مثل هذه الأورام في الأطراف، والحوض، والرأس، والرقبة، ولكن أكثرها يظهر في الأنسجة العضلية. تعد هذه الأورام من الآفات الخطيرة حيث أنها تحدث في سن مبكرة وذلك عند المقارنة مع الأورام السحائية الأخرى، كما أنها قد تنتقل خارج القحف، وتعد نسبة تكررها عالية. تمثل أورام الخلايا الحوطية أقل من 1% من مجمل أورام الجهاز العصبي المركزي، وتظل العملية الجراحية العلاج الأمثل لمثل هذه الحالات، في حين يعد كلاً من العلاج الكيميائي والإشعاعي من الخيارات المتاحة للعلاج.

We report a unique case of a 37-year-old female suffering from hemangiopericytoma of the pineal region, successfully excised by surgery. Hemangiopericytomas are rare malignant vascular tumors arising from mesenchymal cells with pericytic differentiation. These tumors usually develop in the limbs, pelvis, head, neck, and mostly in the muscle tissue. They are aggressive lesions that tend to occur at an earlier age than other meningeal tumors, recur with high frequency, and metastasize extracranially. Hemangiopericytomas represent less than 1% of all CNS tumors. Surgery remains the mainstay treatment. Radiotherapy and/or chemotherapy are the other treatment options.

Neurosciences 2011; Vol. 16 (2): 159-161

From the Departments of Neurosurgery (Hasturk, Basmaci, Canbay) and Pathology (Bozdogan), Dr. Abdurrahman Yurtaslan Oncology Training and Research Hospital, Ankara, Turkey.

Received 27th October 2010. Accepted 8th February 2011.

Address correspondence and reprint request to: Dr. Askin E. Hasturk, Department of Neurosurgery, Dr. Abdurrahman Yurtaslan Oncology Training and Research Hospital, Vatan Caddesi, 06200 Yenimahalle, Ankara, Turkey. Tel. +90 (312) 3360909. Fax. +90 (312) 3454979. E-mail: aehasturk@yahoo.com

Hemangiopericytoma (HPC) is a soft tissue tumor derived from mesenchymal cells with pericytic differentiation.¹ It was initially described by Stout and Murray² in the omentum region in 1942. Begg and Garret³ were the first authors who reported an HPC in an intracranial location in 1954. Tumor cells also known as "pericytes" are tightly packed cells located around thin-walled and endothelial-lined vascular channels. They cover the exterior surface of the basal membrane and have the ability of contraction.⁴ These cells have been separated from meningiomas in the recent WHO classification and reclassified among mesenchymal tumors.⁴ An HPC may occur anywhere in the body, the most common anatomic locations being the lower extremities, the pelvis, the head and neck.⁴⁻⁶ They usually settle to the falx, tentorium, cerebral convexity, and sphenoid ridge intracranially.^{4,6-8} In this study, we report a unique case, hemangiopericytoma of the pineal region, successfully excised by surgery.

Case Report. A 37-year-old female patient presented to our outpatient clinic with the complaints of headache, memory loss, and vomiting for 2 days. Neurological examination revealed minimal anisocoria, optic atrophy, and optic disc edema. A cranial MRI showed a mass lesion covering the pineal region and extending into the central plate and both parietal sites with perifocal edema (Figures 1a & 1b). She underwent surgery. Gross total tumor resection was performed without any complications (Figure 2). Histopathology revealed oval-round, spindle like cells consisting of excessive mitotic figures. The HPC sites that are rich from branching vascular structures were seen around the tumor tissue. The tumor was diffusely stained with vimentin while epithelial membrane antigen (EMA), glial fibrillary acidic protein (GFAP) staining was negative. Vascular structures were stained with CD31, also known as PECAM-1 (platelet endothelial cell adhesion molecule-1). Proliferated reticular fibers were noted between the reticulin and tumor tissue (Figures 3a-c). She received postoperative radiotherapy. Follow-up MRIs did not show any recurrence.

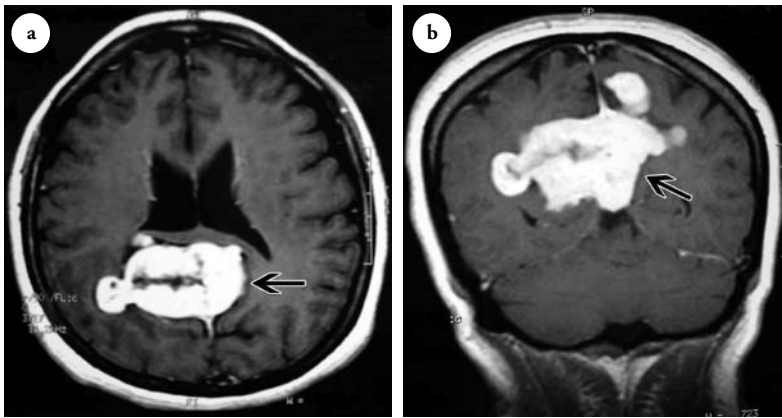


Figure 1 - Axial a) and coronal b) postcontrast MR images show a mass lesion that covered the pineal region and extended into the central plane and both parietal sites causing peripheral edema. Homogeneous contrast enhancement is noted.

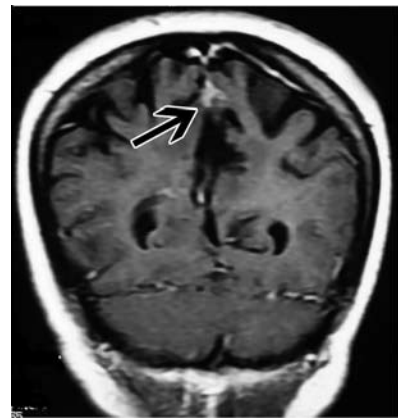


Figure 2 - Mass lesion appears to be totally resected in the control T1W MR images.

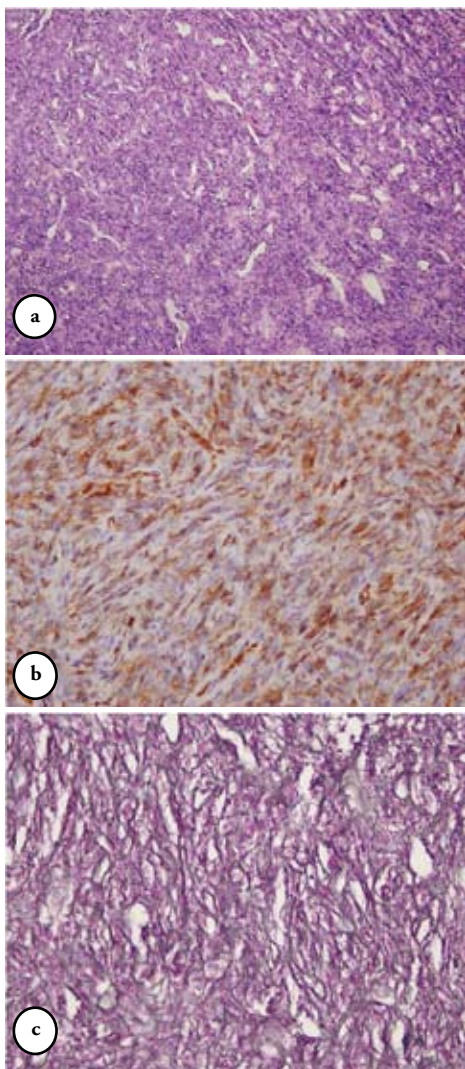


Figure 3 - Histopathological appearance of the tumor showing a) hypercellular tumor with slit like vascular channels (HE, original magnification x100) b) CD34 reactivity is noted in tumoral cells (CD34, original magnification x400), c) A rich network of reticular fibers (reticulin, original magnification x400).

Discussion. The HPC is a rare vascular tumor originating from the pericytes of the capillary wall. It forms less than 1% of the CNS tumors.⁴ It was firstly described in an intracranial location by Begg and Garret in 1954³ and was initially considered as a variant of meningioma (angioblastic meningioma, hemangiopericytic type). However, due to its different clinical course, immunohistochemical, and structural characteristics, HPC was reclassified by the WHO.⁴ The HPC is a deep soft tissue tumor with insidious growth. It may originate from any part of the body, most frequently seen in the lower extremities, pelvic, and head-neck region. A dermal and subcutaneous HPC is uncommon when compared to the other types.^{1,4,9,10} Clinical presentation is non-specific with seizure, vomiting, focal neurological deficit, headache, papilledema, and intracranial hemorrhage rarely.^{1,6,10} Radiological findings are also not specific. Despite the advances in neuroradiology, the differentiation of HPC is still difficult. They consist of a well-circumscribed, radiopaque soft tissue mass that often displaces neighboring structures.^{6,9,10} Cystic deformations are not uncommon, but calcification is rare. These tumors are generally seen as non-hyperostotic masses enhancing heterogeneously with clear margins.^{6,10} The proliferation of myoinositol rate on magnetic resonance spectroscopy is pathognomonic for HPC. The common characteristics are reductions of N-acetyl aspartate amount and phosphocreatine/creatinine rate.^{6,10} Histopathology exhibits vesicular or hyper chromatic oval-round cells that consist of excessive mitotic figures. Branching vascular areas are commonly seen inside the tumor tissue. Reticular fibers generally surround the tumor cells. Light microscopy reveals cells called ‘pericytoma,’ which are tightly aligned and ordered around the vascular ducts of the small capillaries and venules.⁴ Immunohistochemical studies contribute to

the description of neoplastic pericytes to some extent. The tumor is diffusely stained positive with vimentin, CD34, factor XIIIa antigen while it is not stained with factor VIII-related antigen.^{4,6,9,10} The muscle cell markers like desmin and actin are focally located at the normal pericytes. These are rarely seen in HPC cells. Approximately two-thirds of the synovial sarcomas are keratin and EMA positive. The HPC generally does not produce EMA and no keratin staining was reported. In light of these histological findings, the differentiation of low and high grade is difficult. Mitotic activity, cellularity, bleeding, and necrosis may provide information on tumor grade.^{4,6,9} Cytogenetic abnormalities were also found in some HPC cases. Recurrent t (12; 19) (q13; q13) translocations in the HPC and breaks in 12q13, 12q24, and 19q13 are frequently seen.^{6,9,10} The HPC is capable of both local recurrence and distant metastases. The most common sites of secondary disease are lungs and bones.^{5,6} Complete surgical resection is the mainstay of treatment, but may not always be performed according to the location. Both radiotherapy and chemotherapy are recommended in all patients with incomplete resection and/or large, locally invasive tumors.⁶⁻⁸ Better prognosis is seen in infants with HPC compared to adults.^{4,6,10} Although metastatic forms are reported, they respond well to chemotherapy.^{5,8} Maximum 10 years of life has been reported to be 70% in the literature. Two and 5 years of life have recently been reported to be 93% and 86% in the series of Espot et al.¹⁰ Although malignant HPC causes local recurrence and distant metastasis, patients die secondary to the bone and lung involvement.⁵ Since local and distant metastases have been reported to occur even in the remission period, long term follow-up is needed.^{6,8,10}

In conclusion, the pineal region consists of pineal glandular tissue, glial cells, arachnoid cells, ependymal lining, sympathetic nerves, germ cells, and remnants of ectoderm. A striking feature is the diversity of the tumors that may occur in this location due to the

variety of tissues. The vast majority of the tumors are germ cell tumors and pineal cell tumors. Astrocytomas, oligodendrogliomas, glial cysts, meningiomas, arachnoid cysts, ependymomas, chemodectomas, epidermoid-dermoid cysts and metastases are less frequently seen in this region.⁴ Hemangiopericytomas should also be kept in mind in the differential diagnosis of pineal region tumors.

References

1. Das P, Haresh KP, Suri V, Sharma MC, Sharma BS, Sarkar C. Malignant hemangiopericytoma of pituitary fossa. *Indian J Pathol Microbiol* 2010; 53: 109-111.
2. Stout AP, Murray MR. Hemangiopericytoma: A vascular tumor featuring Zimmerman's pericytes. *Ann Surg* 1942; 116: 26-33.
3. Begg CF, Garret R. Hemangiopericytoma occurring in the meninges: case report. *Cancer* 1954; 7: 602-606.
4. Giannini C, Rushing EJ, Hainfellner JA. Hemangiopericytoma. In: Louis DN, Ohgaki H, Wiestler OD, Cavenee WK, editors. WHO classification of tumours of the central nervous system. Lyon: International Agency for Research on Cancer 2007; p: 178-180.
5. Suzuki H, Haga Y, Oguro K, Shinoda S, Masuzawa T, Kanai N. Intracranial hemangiopericytoma with extracranial metastasis occurring after 22 years. *Neurol Med Chir (Tokyo)* 2002; 42: 297-300.
6. Alén JF, Lobato RD, Gómez PA, Boto GR, Lagares A, Ramos A, et al. Intracranial hemangiopericytoma: study of 12 cases. *Acta Neurochir (Wien)* 2001; 143: 575-586.
7. Soyuer S, Chang EL, Selek U, McCutcheon IE, Maor MH. Intracranial meningeal hemangiopericytoma: the role of radiotherapy: report of 29 cases and review of the literature. *Cancer* 2004; 100: 1491-1497.
8. Sheehan J, Kondziolka D, Flickinger J, Lunsford LD. Radiosurgery for treatment of recurrent intracranial hemangiopericytomas. *Neurosurgery* 2002; 51: 905-911.
9. Hayashi Y, Uchiyama N, Hayashi Y, Nakada M, Iwato M, Kita D, et al. A reevaluation of the primary diagnosis of hemangiopericytoma and the clinical importance of differential diagnosis from solitary fibrous tumor of the central nervous system. *Clin Neurol Neurosurg* 2009; 111: 34-38.
10. Espot NJ, Lewis JJ, Leung D, Woodruff JM, Antonescu CR, Shia J, et al. Conventional hemangiopericytoma: modern analysis of outcome. *Cancer* 2002; 95: 1746-1751.

COPYRIGHT

Whenever a manuscript contains material (tables, figures, etc.) which is protected by copyright (previously published), it is the obligation of the author to obtain written permission from the holder of the copyright (usually the publisher) to reproduce the material in Neurosciences. This also applies if the material is the authors own work. Please submit copies of the material from the source in which it was first published.