

# Paranglioma of the sacral spinal canal

Mohamed Lmejjati, MD, Fabrice Parker, MD, PHD, Catherine Lacroix, MD, Marc Tadié, MD, PHD.

## ABSTRACT

يعد ورم المستقمتات من الأورام التي تنشأ في منطقة المستقمتات، غير أن حدوثها في العمود الفقري يعد من الأمور النادرة إذ أنها عادة ما تظهر على شكل انضغاط في ذيل الحصان داخل الجافية. نستعرض في هذا المقال حالة نادرة لمريض يبلغ من العمر 60 عاماً وقد دخل المستشفى بعد إصابته بألم حاد ومتكرر في المنطقة العجزية والعجزية، وقد صاحب ذلك إصابته بنقص الحس في منطقة العجان والنباييت. لقد أجريت له عملية جراحية باستئصال الصفيحة الفقرية للفقرات إس1 وإس2، بالإضافة إلى قطع جملة الورم من المنطقة المصابة. وكشفت الاختبارات التي أجريت على العينة النسيجية للورم عن وجود ورم المستقمتات، وقد كانت حالة المريض بعد إجراء العملية خالية من الاضطرابات، كما أن المرض لم يظهر مرة أخرى بعد مرور عام واحد من العملية. نستنتج من هذه الحالة أنه بالرغم من ندرة حدوث ورم المستقمتات في القناة الفقرية العجزية إلا أنه يجب أخذها بالحسبان عند تشخيص الأورام المختلفة التي تحدث في العمود الفقري.

Parangliomas are tumors arising in the paraganglia. Involvement of the spine is less common, and usually takes the form of intradural compression of the cauda equina. We report here a case of a 60-year-old man with recurrent and progressive pain of his sacral and perineal area, accompanied by occasional rod and perineal hypoesthesia on admission. He underwent laminectomies of the vertebral bodies S1 and S2, and an en bloc resection of the tumor. Postoperative histopathological examination revealed a paranglioma. Postoperative staging showed no pathological abnormalities, and no tumor recurrence after one year. Even though rare, the paranglioma of the sacral spinal canal should be considered in the differential diagnosis of tumors occurring in the spine.

*Neurosciences 2011; Vol. 16 (3): 270-272*

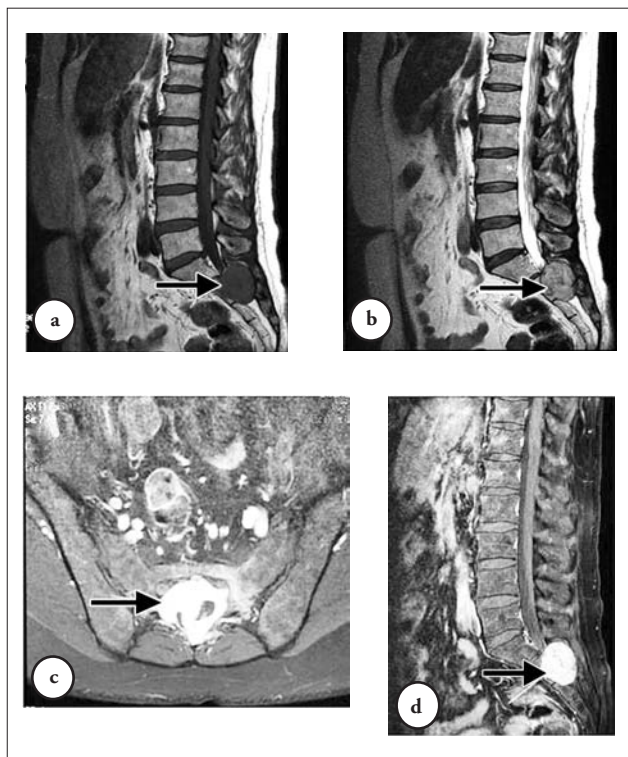
From the Department of Neurosurgery (Lmejjati), Cadi Ayyad University, Marrakesh, Morocco, and the Departments of Neurosurgery (Parker, Tadié), and Neuropathology (Lacroix), University Hospital Kremlin Bicêtre, Paris, France.

Received 29th December 2010. Accepted 4th April 2011.

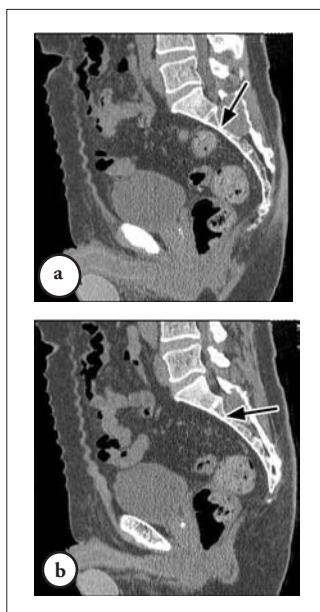Address correspondence and reprint request to: Dr. Mohamed Lmejjati, Department of Neurosurgery, Faculty of Medicine, Cadi Ayyad University, BP 7010 Sidi Abbad 40000, Marrakesh, Morocco. Tel +212 (661) 306761. Fax. +212 (524) 432887. E-mail: oalmejjati@yahoo.fr

Parangliomas are tumors originating from the paraganglial cells, which are embryologically derived from the neural crest tissue,<sup>1</sup> and account for 0.3% of all neoplasms.<sup>2</sup> Iwt has been identified in multiple sites, in which paraganglia normally occur, such as the head and neck, thorax, intestinal tract, bladder, and retroperitoneum.<sup>3</sup> Spine involvement is much less common, and usually takes the form of intradural compression of the cauda equina.<sup>3</sup> Parangliomas involving the sacral spinal canal are a very rare occurrence, and few cases have been published as a localization in the terminal filum extending to S1, and a case of intraosseous paranglioma of the sacrum.<sup>4,5</sup> These cases illustrate the characteristic finding of the paranglioma of the sacral spinal canal, and the potentially aggressive nature of this disease.

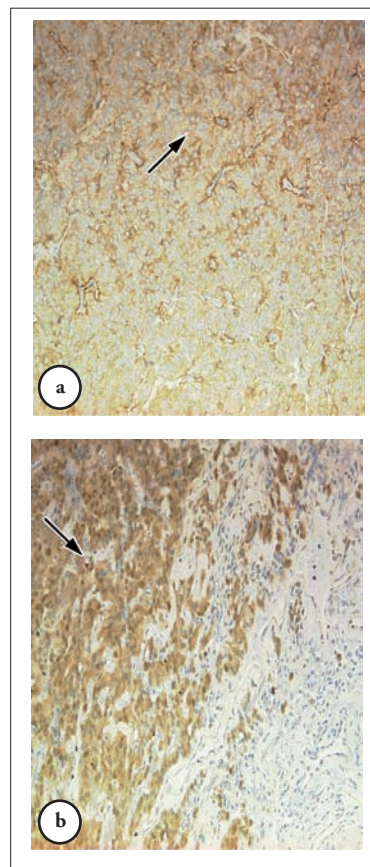
**Case Report.** A 60-year-old man was admitted with a 3-month history of progressive pain of his sacral and perineal area, accompanied by occasional rod, and perineal hypoesthesia. The pain was increased in the seating position. He was treated 3 months before his hospitalization by surgery and chemotherapy by carboclatine for a testicular seminoma, with no metastasis. Neurological examination was normal. Examination of the spine did not reveal any abnormalities. Perineal sensation and anal tone were normal. The MRI scan of the entire spine revealed a solitary epidural space occupying lesion, opposite the S2 and S3 vertebrae completely filling and enlarged in the sacral space of the S2 and S3. The mass was hypointense on T1-, and heterogenic on T2-weighted images (Figures 1a & 1b), with intense contrast enhancement after injection of gadolinium (Figures 1c & 1d). A CT scan of the sacrum showed an intracanalicular sacral expansive mass eroding the body (scalloping S2 and S3), and posterior arc of S2 and S3 (Figures 2a & 2b). The diagnosis of chordoma or metastasis was evoked. Surgical management was performed via a laminectomy of the S2 and S3 with total excision of the intracanalicular lesion. At surgery, an irregular shaped nodule was found. The lesion was vascular, well encapsulated, and not attached to other structures. This lesion was clearly extradural, and although it encroached upon the S2 and S3 nerve roots



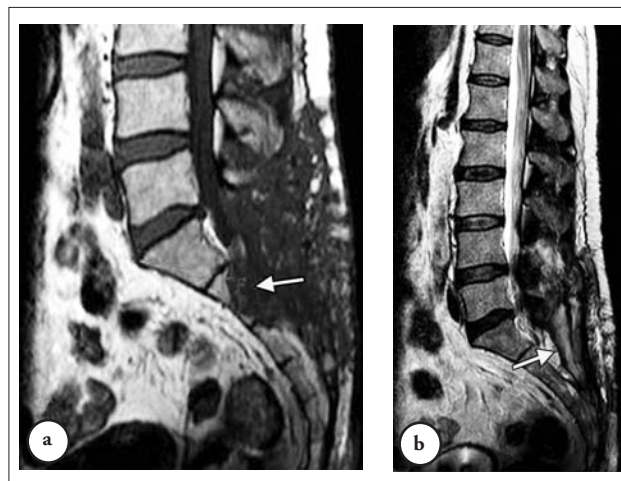
**Figure 1** - Patient MRI a) T1-weighted and b) T2-weighted sagittal images of the lumbosacral spine show a roundish intracanal mass opposite S2 and S3 (arrows). The axial c) and sagittal d) T1-weighted images show that the mass is well defined with intense enhancement (arrows).



**Figure 2** - A CT scan of the lumbosacral spine showed an intracanal mass involving the a) posterior arch and b) causing a scalloping S2 and S3 (arrows).



**Figure 3** - Photomicrograph demonstrating a well-differentiated paraganglioma containing a) typical Zell-Ballen clusters of epithelioid cells (hematoxylin and eosin; original magnification, x400) and b) occasional mitoses (arrows).



**Figure 4** - Patient MRI a) T1-weighted and b) T2-weighted sagittal magnetic resonance images control show no residual tumor (arrows).

posteriorly, it did not appear to arise from the sacral nerve roots, or the filum terminale. On histological studies, the tumor's histology picture was also consistent with that of a paraganglioma (Figures 3a & 3b). Tumor cells were large, epithelioid with ovoid eosinophilic cytoplasm containing round nuclei, and arranged in clusters separated by fine fibrovascular septae with many dilated blood vessels. There were occasional mitoses (3/10 fields x400). The tumor infiltrated the osseous tissue. Immunocytochemistry showed widespread reactivity with synaptophysin, focal reactivity with glial fibrillary acidic protein, and equivocal results with S-100. He had a good recovery, with complete resolution of his pain. Months after surgery, he has no evidence of recurrence, and there was a complete resolution of his symptoms. Due to the aggressive histological pattern of the tumor, he underwent a course of adjunctive postoperative radiation therapy consisting of a total dose of 45 Gy to the spinal column. The MRI scan did not demonstrate any obvious residual tumor (Figures 4a & 4b).

**Discussion.** Parangliomas are neoplasms derived from neurosecretory cells believed to be of neural crest origin,<sup>4</sup> and account for 0.3% of all neoplasms.<sup>2</sup> Most reported spinal paraganglioma are intradural tumors involving the cauda equina and thoracic cord.<sup>5</sup> Extradural paragangliomas are still rare; only few cases involving the dorsolumbar spine have been reported.<sup>2</sup> Parangliomas involving the sacral spinal canal are a very rare occurrence, except one case of the localization in the terminal filum extending to S1, and another case of intraosseous paraganglioma of the sacrum,<sup>3</sup> with intracanal extension. This is a report of an intracanal sacral spinal paraganglioma.

A paraganglioma is usually benign.<sup>6</sup> However, malignant metastatic lesions have also been reported with both synchronous and metachronous metastasis presenting at varying time intervals.<sup>5</sup> Reports of familial occurrence and association with other tumors such as leiomyosarcomas, chordomas (the "Carney triad"), or pituitary adenomas suggests a genetic basis for the tumor.<sup>6</sup> A wide range of age at presentation of between 13-74 years with a mean age of 46 years has been reported with a slight male predominance (2:1).<sup>7</sup> A paraganglioma of the spinal canal is generally characterized by low back and/or sciatic pain, there may also be sensory, or motor deficits in the lower extremities, and occasionally, sphincteric and erectile function. The prevalence of one of the symptoms depends on the intracanal localization of the tumor. In most cases, the MRI appearance of paraganglioma is not distinguishable from neurinoma.<sup>1</sup>

Images of a paraganglioma of the spine revealed a well-defined mass with low to intermediate intensity

on T1-weighted images, and intermediate to high signal intensity on T2-weighted images, compared to paravertebral muscles. Contrast-enhanced MR images showed intense heterogeneous enhancement. Multiple punctuate and serpiginous areas of signal void due to high velocity flow are noted around and within the tumors on all sequences.<sup>8</sup> These may be the characteristic findings of spinal paraganglioma.<sup>8</sup> The diagnosis of paraganglioma was based on clinical symptoms, MRI, and especially on the histology, in that the tumor cells exhibited granular eosinophilic cytoplasm, and round or ovoid nuclei. There is positive staining for synaptophysin; chromogranin A, S100, and tumor-specific antigen. Malignancy cannot be determined with histological assessment, but is demonstrated by metastases and invasion.<sup>9</sup> In most cases, total removal of the paraganglioma can be achieved. Once this lesion has been removed completely, it does not recur, and does not produce metastases.<sup>1</sup> Prognosis is dependent on the ability to achieve complete removal of the lesion. In case of incomplete removal, radiotherapy is an option, although radioresistance has been reported.<sup>6</sup> The median time for recurrence following primary resection is approximately 6 years,<sup>10</sup> although there are reports of time intervals of up to 20 years between the initial diagnosis and the appearance of either local recurrence, or metastases. Hence, long term follow up is needed particularly in cases of incomplete excision.<sup>5</sup>

In conclusion, in spinal tumors, the possibility of paraganglioma should be included in the differential diagnosis.

## References

- Caruso R, Wierzbicki V, Marroccco L, Salvati M. Parangliomas of the cauda equina: Report of one case and review of the literature. *J Exp Clin Cancer Res* 2006; 25: 269-275.
- Ojha BK, Sharma MC, Rastoqi M, Chaudra A, Husain M, Husain N. Dumbbell-shaped paraganglioma of the cervical spine in a child. *Pediatr Neurosurg* 2007; 43: 60-64.
- Cybulski GR, Nijensohn E, Brody BA, Meyer PR Jr, Cohen B. Spinal cord compression from a thoracic paraganglioma: case report. *Neurosurgery* 1991; 28: 306-309.
- Coles CP, Alexander DI, Gross M, Holness RO, Covert AA, Murray SK. Intraosseous paraganglioma of the sacrum: a case report. *Can J Surg* 2000; 43: 137-139.
- Makhdoumi R, Nayil K, Santosh V. Primary Spinal Parangliomas: A review. *Neurosurgery Quarterly* 2009; 19: 196-199.
- Sousa J, O'Brien D, Crooks D. Paranglioma of the filum terminale. *J Clin Neurosci* 2005; 12: 584-585.
- Aghakhani N, George B, Parker F. Paranglioma of the cauda equina region--report of two cases and review of the literature. *Acta Neurochir (Wien)* 1999; 141: 81-87.
- Gallivan MV, Chun B, Rowden G, Lack EE. Intrathoracic paravertebral malignant paraganglioma. *Arch Pathol Lab Med* 1980; 104: 46-51.
- Shin JY, Lee SM, Hwang MY, Sohn CH, Suh SJ. MR Findings of the Spinal Paranglioma: Report of three cases. *J Korean Med Sci* 2001; 16: 522-526.
- Jeffs GJ, Lee GY, Wong GT. Functioning paraganglioma of the thoracic spine: case report. *Neurosurgery* 2003; 53: 992-995.