

# Endovascular treatment of ruptured peripheral intracranial aneurysms

Zhi Chen, MD, Yunfeng Yang, MD, PhD, Hongpin Miao, MD, Jingyu Chen, MD, Chunxia Luo, MD, PhD, Hua Feng, MD, PhD, Gang Zhu, MD, PhD.

## ABSTRACT

**الأهداف:** تقييم مدى سهولة والنتائج المترتبة عن العلاج من داخل الشرايين بعد الإصابة بتمزق تمدد الأوعية الدموية الطرفية داخل القحف.

**الطريقة:** أُجريت هذه الدراسة الاسترجاعية في قسم الجراحة العصبية، مستشفى ساوث ويست، شونغ كينغ، الصين، حيث قمنا باسترجاع وتقييم نتائج العلاج من داخل الشرايين لقرابة 18 مريض مصاب بتمدد الأوعية الدموية القاصية داخل القحف وذلك خلال الفترة من يناير 2005م إلى يونيو 2010م. ولقد قمنا باستخدام العديد من الطرق العلاجية وذلك اعتماداً على شكل وموقع التمدد الدموي، وكانت هذه الطرق كالتالي: الوشيعية الاختيارية لتمدد الأوعية الدموية، إطباق الشريان الأم للتمدد الدموي، والوشيعية بمساعدة الدعامات، والوشيعية بمساعدة القسطرة الدقيقة.

**النتائج:** لقد كان الإنصمام من داخل الشرايين ناجحاً من الناحية التقنية في كافة المرضى. وأشارت نتائج الدراسة إلى علاج 5 مرضى بالوشيعية الاختيارية لتمدد الأوعية الدموية، وعلاج 5 مرضى بالإنصمام باستخدام الوشيعية بمساعدة القسطرة الدقيقة أو بمساعدة الدعامات. أما بقية المرضى الثمانية فقد عولجوا بإطباق الشرايين الأم، أو إطباق الشرايين مع تمدد الأوعية الدموية وذلك باستخدام الوشيعية أو الصمغ. ولم تؤدي العمليات الجراحية إلى أي من المضاعفات المتمثلة بالتمزق أو تمزق تمدد الأوعية الدموية. لقد عانى اثنان من المرضى الذين عولجوا بالإطباق من أعراض حادة أو متأخرة من الإقفار الدموي غير أنهما شفيا بعد ذلك. ولم يعاني أي من المرضى من النزيف بعد إجراء العملية الجراحية خلال فترة المتابعة التي تراوحت ما بين 5-66 شهر وبالمتوسط 22.2 شهر.

**خاتمة:** أظهرت هذه الدراسة مدى أمان وسهولة طرق العلاج من داخل الشرايين بعد الإصابة بتمدد الأوعية الدموية الطرفية داخل القحف.

**Objectives:** To assess the feasibility and result of endovascular treatments for ruptured peripheral intracranial aneurysms.

**Methods:** We retrospectively reviewed our experience and results of endovascular treatments for a series of 18 consecutive patients with ruptured distal intracranial aneurysms at the Department of Neurosurgery, Southwest Hospital, Chongqing, China between January 2005 and June 2010. Depending on the location and shape of the aneurysms, we used various therapeutic strategies including selective aneurysmal coiling, parent artery (and aneurysm) occlusion, stent-assisted coiling, and microcatheter-assisted coiling.

**Results:** Endovascular embolization was technically successful in all patients. Five patients were treated by selective aneurysm coiling; 5 patients were embolized with the stent-assisted technique or microcatheter-assisted technique. In the remaining 8 patients, the parent arteries, or together with the aneurysms were occluded using coils or glue. No procedure complication such as thrombosis or aneurysmal rupture was encountered during treatment. Two patients treated with parent artery occlusion developed acute or delayed transient ischemic symptoms, but they eventually made a good recovery. No patient has experienced postprocedural hemorrhage during the follow-up period (5-66 months; mean, 22.2 months).

**Conclusion:** Endovascular treatment is a feasible and effective therapeutic alternative for peripheral intracranial aneurysms.

*Neurosciences 2012; Vol. 17 (2): 133-138*

*From the Department of Neurosurgery (Chen Z, Miao, Chen J, Luo, Feng, Zhu), Southwest Hospital, Third Military Medical University, Chongqing, and the Department of Neurosurgery (Yang), Sichuan Provincial Crops Hospital, Chinese People's Armed Police Forces, Leshan, China.*

*Received 29th October 2011. Accepted 13th February 2012.*

*Address correspondence and reprint request to: Prof. Gang Zhu, Department of Neurosurgery, Southwest Hospital, Third Military Medical University, Gaotanyan Street, Shapingba District, Chongqing 400038, China. Tel. +86 (23) 68765759. Fax. +86 (23) 65463954. E-mail address: a65427851@cta.cq.cn*

**Disclosure.** The authors declare no conflicting interests, support or funding from any drug company.

Intracranial aneurysms tend to arise at the arterial branch points around the circle of Willis, while peripheral intracranial aneurysms are rare and have been less commonly reported. Most reported cases have been treated by open surgery including direct clipping, wrapping, proximal clipping, trapping, or resection with or without vascular anastomosis.<sup>1-3</sup> However, surgical treatment procedures sometimes carry risks of neurological complications, especially in the aneurysms of posterior circulation because of the close relationship of these aneurysms with the brain stem and cranial nerves.<sup>4-6</sup> An alternative treatment for those lesions may be endovascular embolization, but only a limited number of published studies have been reported. In the present study, we retrospectively reviewed our endovascular management of distal intracranial aneurysms in 18 patients, with an assessment of its efficacy and safety.

**Methods.** From January 2005 to June 2010, 18 consecutive patients with peripherally located intracranial aneurysms were included in this study carried out at the Department of Neurosurgery, Southwest Hospital, Chongqing, China. As suggested before, only truly peripheral intracranial aneurysms were included in our study.<sup>3</sup> Infectious aneurysms and aneurysms associated with an arteriovenous malformation or moyamoya disease, as well as distal anterior cerebral artery (ACA) aneurysms arising at the origin of the pericallosal artery, were not included.<sup>3</sup> This study was approved by the Ethics Committee of the Southwest Hospital and was carried out under the tenets of the Helsinki declaration.

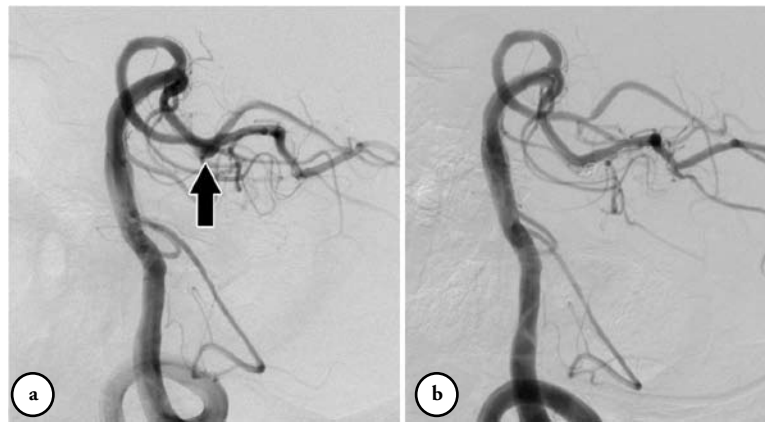Our patient group consisted of 8 females and 10 males with a mean age of 45 years (range, 31–75 years). All patients presented with subarachnoid hemorrhage or intraventricular hemorrhage caused by ruptured aneurysms. Aneurysms were located at the posterior inferior cerebellar artery (PICA) in 6 cases, the posterior cerebral artery (PCA) in 5 cases, the middle cerebral artery (MCA) in 3 cases, the ACA in 2 cases, the posterior communicating artery (PCoA) in one case, and the anterior choroidal artery (AChA) in one case.

Endovascular treatment was performed under general anesthesia. Systemic heparinization was given during the procedure. Angiograms were assessed for size, shape, and location of the aneurysm. Depending on the location and shape of the aneurysm, various therapeutic strategies were chosen including selective aneurysmal coiling, parent artery occlusion (PAO), stent-assisted coiling, and microcatheter-assisted coiling. For saccular aneurysms with a narrow neck, selective aneurysmal coiling was attempted. Stent-

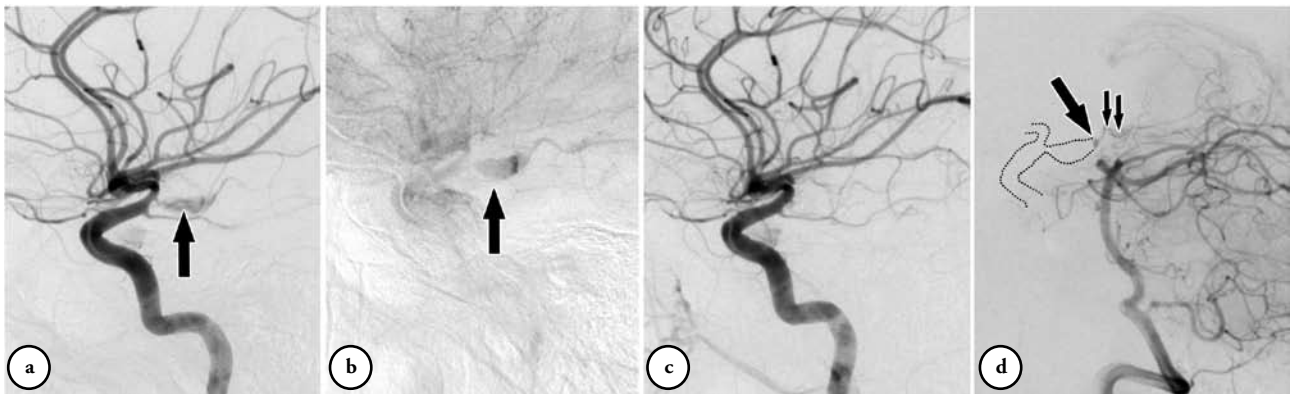assisted coiling or microcatheter-assisted coiling was used for wide-necked aneurysms with preservation of the parent artery. The parent artery, or together with the aneurysm were occluded using coils or glue in fusiform aneurysms and those with very small parent arteries. Standard methods of aneurysm coiling, stent-assisted coiling, or microcatheter-assisted coiling were used as described in the literature.<sup>1,7,8</sup> The Enterprise self-expanding stent (Cordis, Miami Lakes, FL, USA) was used for stent-assisted coiling. Detachable coils used for embolization included Sapphire coils (ev3, Irvine, CA, USA) and MicroPlex coils (MicroVention, Aliso Viejo, CA, USA). After endovascular treatment, patients with a stent placement were given dual antiplatelet therapy (75 mg clopidogrel and 100 mg aspirin once a day) orally for at least one month. Heparinization was continued for 48 hours in patients who underwent parent artery occlusion. The follow-up evaluation was based on physical examination and imaging studies, including conventional angiography or magnetic resonance angiography.

**Results.** Endovascular embolization was technically successful in all patients. In 5 of 9 patients with saccular aneurysms, microcatheters were successfully inserted into the aneurysms sac and the aneurysms were completely occluded. Of the 4 wide-necked aneurysms, 2 aneurysms (one MCA aneurysm, and one PCA aneurysm) were treated by the stent-assisted technique, and one aneurysm was treated by the microcatheter-assisted technique. In one patient with a wide-necked PCoA aneurysm, the planed balloon-assisted technique failed for the balloon microcatheter could not be navigated across the aneurism neck. This aneurysm was selectively embolized under the protection of an additional microcatheter.

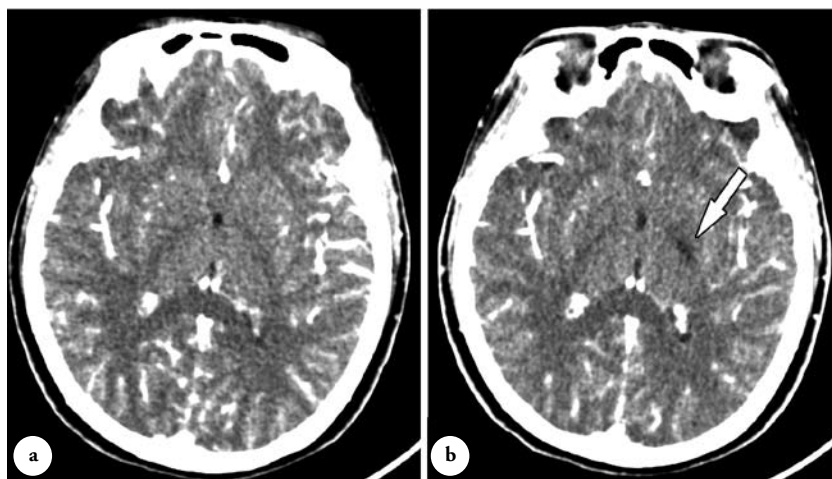
In 8 of the 9 patients with fusiform aneurysms, the parent arteries or together with the aneurysms were occluded (4 PICA, 2 PCA, one ACA, and one AChA aneurysm). In an aneurysm on the anterior-medullary segment of PICA, we attempted preservation of the parent artery by the stent-assisted technique. However, the stent catheter could not be navigated into the PICA due to the stenosis at the origin of the PICA. The aneurysm and parent artery were then occluded with coils. The parent vessel occlusions were performed with coils in 5 aneurysms, and with Onyx (ev3 Inc., Irvine, CA, USA) in 3 aneurysms (2 PICA aneurysms and one ACA aneurysm). In the remaining PCA fusiform aneurysm, stent-assisted coiling was chosen with preservation of the parent artery (Figure 1).



**Figure 1** - A 57-year-old male with a ruptured peripheral posterior cerebral artery (PCA) aneurysm. a) Preoperative angiogram of the right vertebral artery shows a fusiform aneurysm (arrow) arising from the distal PCA. b) Postembolization angiogram of the right vertebral artery shows the occlusion of the aneurysm by stent-assisted coiling.



**Figure 2** - A 36-year-old female with a distal ruptured anterior choroidal artery (AChA) aneurysm. a) Preoperative angiogram of the left internal carotid artery (ICA) shows an large fusiform aneurysm (arrow) arising from the distal AChA. b) Venous phase of the digital angiogram shows stasis of contrast in the aneurysm (arrow). c) Postembolization angiogram of the left ICA shows the occlusion of the aneurysm together with the AChA. d) Postembolization angiogram of the left vertebral artery shows the distal AChA (short arrows) filled in a retrograde fashion. The dashed line indicates the location of the aneurysm and the left ICA. A very slight residual filling of the aneurysm (long arrow) is also noted.



**Figure 3** - The CT scan obtained from a 36-year-old female with a distal ruptured anterior choroidal artery aneurysm. a) Enhanced CT scan 2 weeks after embolization shows no abnormalities, but b) one month after embolization shows delayed infarction (arrow) in the posterior limb of the internal capsule.

No procedural complications, such as thrombosis or aneurysmal rupture were encountered during treatment. There was complete obliteration in 16 patients, and nearly complete occlusion in the remaining 2 patients. Imaging, including CT angiography, MR angiography, or DSA and clinical follow-up (5-66 months; mean, 22.2 months) was available for all patients. No patient experienced postprocedural hemorrhage, but 2 patients were involved in postoperative ischemic complications. The first patient is a 46-year-old man with a dissecting aneurysm on the anterior-medullary segment of the left PICA, whose existing partial Wallenberg's syndrome got worse after treatment. He recovered gradually with moderate dysphagia and ataxia. The second patient is a 33-year-old woman with a large fusiform aneurysm arising from the cisternal segment of the left AChA. As the microcatheter could only be navigated to the origin of the AChA, coiling was then performed (Figures 2a & 2b). Postembolization angiogram revealed occlusion of the aneurysm together with the AChA, although vertebral angiogram showed slight residual filling of the aneurysm through the AChA in a retrograde fashion (Figures 2c & 2d). The patient did not develop any neurological deficit after embolization. Unfortunately, she suffered right hemiparesis with dysarthria one month after embolization. Repeated CT scan revealed infarction in the posterior limb of the internal capsule (Figure 3). The patient was treated with anti-coagulation therapy and had good neurological recovery. Her hemiparesis and dysarthria resolved almost completely during the clinical follow-up period of 3 months.

**Discussion.** Peripheral intracranial aneurysms are rare and tend to be fusiform and large.<sup>1-3</sup> Of the 18 aneurysms in the present study, 9 (50%) were fusiform, and 5 (28%) were large in shape. These morphological characteristics make endovascular treatment with preservation of the parent artery difficult in a substantial percentage of cases. Recently, with the development of endovascular devices and techniques, endovascular treatment has become a standard method for the treatment of intracranial aneurysms. In 2005, the results of a one-year clinical outcome from the multicenter International Subarachnoid Aneurysm Trial (ISAT) were reported.<sup>9</sup> The study compared the efficacy of endovascular treatment with surgical treatment in 2143 patients with ruptured aneurysms and found obvious advantage of endovascular coiling over neurosurgical clipping in terms of death and severe disability.<sup>9</sup> A decrease of surgical treatment and an increase of endovascular treatment in some neurosurgical centers has been reported after publication of the

ISAT results,<sup>10</sup> although the recently published 5-year results of the ISAT showed no significant difference in either disability or mortality between the 2 treatment modalities.<sup>10,11</sup> Traditionally, most of the peripheral intracranial aneurysms have been treated with PAO when selective embolization was not available.<sup>1,3,6</sup> Andreou et al<sup>1</sup> reported 27 patients with distally located aneurysms who underwent endovascular treatment. Nineteen patients in their series (6 PCA, 4MCA, 5 SCA, 2 ACA, and 2 PICA aneurysms) underwent PAO, and 5 patients developed neurological deficits, but only 2 patients had permanent neurological deficits during the follow-up. The authors suggested that PAO should be considered a therapeutic option for distal cerebral aneurysms because it is relatively safe and effective and carries acceptable morbidity and mortality.

According to the location of the aneurysms in our 8 patients who underwent PAO (4 PICA, 2 PCA, one ACA, and one AChA aneurysm), we briefly reviewed the results of PAO for peripheral aneurysms from some previous reports. Peripheral PICA aneurysms usually have a fusiform shape or wide neck, making saccular coiling with parent artery preservation difficult or impossible.<sup>6</sup> The PAO was thought to be a relatively safe and reliable alternative to surgery for aneurysms of the PICA. Maimon et al<sup>12</sup> reported 6 patients with dissecting aneurysms of the distal PICA, and reviewed 4 additional cases from the literature. All patients obtained complete occlusion of the diseased PICA segment, and only 2 patients had transient postoperative neurological deficits. In another consecutive series of 12 patients harboring peripheral PICA aneurysms allocated for endovascular treatment, 6 patients underwent PAO, and transient ischemic symptoms appeared in 2 patients.<sup>4</sup> However, occlusion at the first 3 proximal segments of the PICA (anterior-medullary, lateral medullary, and tonsillomedullary) carries potential risks of brain stem ischemia, which was also seen in one of our patients. In this circumstance, distal revascularization may not also avoid brain stem ischemia, because the anastomosis could only collateralize circulation to the hemispheric branch of the PICA and do nothing to compensate for the loss of perforators in the segment of PICA that is trapped.<sup>2</sup> Similarly, fusiform or large aneurysms have also been commonly seen in distal PCA aneurysms, and the P2 segment was the most common location of those aneurysms.<sup>6</sup> Roh et al<sup>6</sup> reported successful endovascular treatment of 13 patients with 17 PCA aneurysms. Among 7 patients treated by occlusion of the aneurysm and parent artery together, only one patient with a ruptured P2 aneurysm developed transient amnesia, although infarctions were found in 3 patients. Andreou

et al<sup>1</sup> reported the results of endovascular treatment of 9 patients with distal PCA aneurysms. Six patients were treated with PAO, and 2 patients had residual visual field defects. The low incidence of visual field defects complicating PAO might be related to the rich anastomotic collaterals that exist between the PCA and other arteries.<sup>5</sup> This has been our experience as well, and in our series, 2 of the 6 patients with PCA aneurysms were treated with PAO, and no new neurological defects were observed.

Compared with distal aneurysms of posterior circulation, PAO has been less reported in ACA and MCA aneurysms. Andreou et al<sup>1</sup> treated 2 patients with peripheral ACA aneurysms by PAO without procedure-related neurological deficits. However, Nussbaum et al<sup>3</sup> reported an 86-year-old man with a giant, ruptured ACA aneurysm, who underwent PAO without revascularization and suffered a significant ischemic injury to his dominant premotor cortex, resulting in transient but severe hemiparesis and aphasia. In our series, only one patient with very distally located ACA aneurysm underwent PAO uneventfully. When endovascular treatment is limited to PAO for peripheral ACA and MCA aneurysms, we agreed with the suggestion by Nussbaum et al,<sup>3</sup> that open surgery might be considered because many of those aneurysms can be reconstructed with preservation of the parent artery. We treated an infectious aneurysm involving 2 distal branches of the MCA. Considering the better rate of parent artery preservation by open surgery as well as the intracranial hematoma, the decision to perform surgery was preferred and direct clipping was successfully carried out in the patient.<sup>13</sup> Distal AChA and PCoA are even rarer. There was one aneurysm of the cisternal segment of AChA, and one aneurysm of the distal PCoA in our series. Considering the difficulties to preserve the patency of the parent artery either by surgery or endovascular treatment due to the fusiform character of the aneurysm, the parent artery was chosen in the AChA aneurysm. The occlusion of AChA from the cisternal segment frequently resulted in various neurological deficits including hemiplegia, hemianesthesia, and hemianopia.<sup>14</sup> This patient was also interesting as she suffered a delayed ischemic stroke one month after compromise of the AChA. Delayed ischemia 4-36 hours after treatment has been noticed after surgical and endovascular treatment of AChA aneurysms.<sup>15,16</sup> The authors suggested that collateralization may be sufficient to prevent an acute ischemia after impairment of AChA flow, but insufficient to maintain adequate perfusion over time for unknown mechanisms such as compromised marginal collateralization, vasospasm and/or thrombosis. To the best of our knowledge, a large

distal AChA aneurysm and the associated long delayed ischemia after compromise of AChA has not been reported before. In this unique patient, the retrograde filling of the AChA from the angiogram explained her avoidance of initial ischemia, and supported at least partly that her delayed ischemic stroke might be due to the extending thrombus from the large aneurysm. Therefore, delayed ischemia should be kept in mind for those patients who underwent endovascular PAO despite uneventful immediate results.

Recently, with the introduction of flexible intracranial stents, intravascular stent technology has been successfully used in distal small vessels.<sup>17</sup> We met no difficulty in navigating and deploying the Enterprise self-expandable stents in 3 aneurysms, but failed in an aneurysm at the origin of the PICA. The microcatheter protective technique is another alternative to the stent or balloon-assisted technique for wide-necked aneurysms, which means positioning an additional microcatheter in the parent or side-branching artery to protect it.<sup>8</sup> We treated one PCoA aneurysm using this technique after the failure of the balloon-assisted technique. It is easier to navigate a 10 or 14 microcatheter through the distal small arteries than a balloon or stent delivery microcatheter.<sup>8</sup> Moreover, compared with a stent-assisted technique, pre- or postprocedural antiplatelet aggregation therapy is not necessarily required for the microcatheter-assisted technique, which reduces the potential hemorrhagic risk of further surgical procedures. Therefore, the microcatheter protective technique may offer a promising therapeutic alternative for wide-necked peripheral aneurysms, which are not suitable for stent or balloon-assisted technique.

In summary, endovascular treatment may be a feasible and effective therapeutic alternative for peripheral intracranial aneurysms. Further follow-up and more experience are necessary to determine the long-term results.

## References

1. Andreou A, Ioannidis I, Mitsos A. Endovascular treatment of peripheral intracranial aneurysms. *AJNR Am J Neuroradiol* 2007; 28: 355-361.
2. Ali MJ, Bendok BR, Tawk RG, Getch CC, Batjer HH. Trapping and revascularization for a dissecting aneurysm of the proximal posteroinferior cerebellar artery: technical case report and review of the literature. *Neurosurgery* 2002; 51: 258-263.
3. Nussbaum ES, Madison MT, Goddard JK, Lässig JP, Nussbaum LA. Peripheral intracranial aneurysms: management challenges in 60 consecutive cases. *J Neurosurg* 2009; 110: 7-13.
4. Isokangas JM, Siniluoto T, Tikkakoski T, Kumpulainen T. Endovascular treatment of peripheral aneurysms of the posterior inferior cerebellar artery. *AJNR Am J Neuroradiol* 2008; 29: 1783-1788.

5. Ciceri EF, Klucznik RP, Grossman RG, Rose JE, Mawad ME. Aneurysms of the posterior cerebral artery: classification and endovascular treatment. *AJNR Am J Neuroradiol* 2001; 22: 27-34.
6. Roh HG, Kim SS, Han H, Kang HS, Moon WJ, Byun HS. Endovascular treatment of posterior cerebral artery aneurysms using detachable coils. *Neuroradiology* 2008; 50: 237-242.
7. Peluso JP, van Rooij WJ, Sluzewski M, Beute GN. A new self-expandable nitinol stent for the treatment of wide-neck aneurysms: initial clinical experience. *AJNR Am J Neuroradiol* 2008; 29: 1405-1408.
8. Lee JY, Seo JH, Cho YD, Kang HS, Han MH. Endovascular treatment of wide-neck intracranial aneurysms using a microcatheter protective technique: results and outcomes in 75 aneurysms. *AJNR Am J Neuroradiol* 2011; 32: 917-922.
9. Molyneux AJ, Kerr RSC, Yu LM, Clarke M, Sneade M, Yarnold JA, et al. International subarachnoid aneurysm trial (ISAT) of neurosurgical clipping versus endovascular coiling in 2143 patients with ruptured intracranial aneurysms: a randomised comparison of effects on survival, dependency, seizures, rebleeding, subgroups, and aneurysm occlusion. *Lancet* 2005; 366: 809-817.
10. Gnanalingham KK, Apostolopoulos V, Barazi S, O'Neill K. The impact of the international subarachnoid aneurysm trial (ISAT) on the management of aneurysmal subarachnoid haemorrhage in a neurosurgical unit in the UK. *Clin Neurol Neurosurg* 2006; 108: 117-123.
11. Molyneux AJ, Kerr RSC, Birks J, Ramzi N, Yarnold J, Sneade M, et al. Risk of recurrent subarachnoid haemorrhage, death, or dependence and standardised mortality ratios after clipping or coiling of an intracranial aneurysm in the International Subarachnoid Aneurysm Trial (ISAT): long-term follow-up. *Lancet Neurol* 2009; 8: 427-433.
12. Maimon S, Saraf-Lavi E, Rappaport ZH, Bachar G. Endovascular treatment of isolated dissecting aneurysm of the posterior inferior cerebellar artery. *AJNR Am J Neuroradiol* 2006; 27: 527-532.
13. Chen Z, Miao H, Feng H, Zhu G. Rupture of an infectious intracranial aneurysm involving two parent arteries after surgical treatment of infective endocarditis. *Neurosciences (Riyadh)* 2011; 16: 72-75.
14. Rousseaux M, Cabaret M, Serafi R, Kozlowski O. An evaluation of cognitive disorders after anterior choroidal artery infarction. *J Neurol* 2008; 255: 1405-1410.
15. Kang HS, Kwon BJ, Kwon OK, Jung C, Kim JE, Oh CW, et al. Endovascular coil embolization of anterior choroidal artery aneurysms. Clinical article. *J Neurosurg* 2009; 111: 963-969.
16. Friedman JA, Pichelmann MA, Piepgras DG, Atkinson JL, Maher CO, Meyer FB, et al. Ischemic complications of surgery for anterior choroidal artery aneurysms. *J Neurosurg* 2001; 94: 565-572.
17. Turk AS, Niemann DB, Ahmed A, Aagaard-Kienitz B. Use of self-expanding stents in distal small cerebral vessels. *AJNR Am J Neuroradiol* 2007; 28: 533-536.

#### Related articles

Chen Z, Miao H, Feng H, Zhu G. Rupture of an infectious intracranial aneurysm involving two parent arteries after surgical treatment of infective endocarditis. *Neurosciences (Riyadh)* 2011; 16: 72-75.

Yoko K, Chen L, Hirotohi S, Takeya W, Sadayoshi W, Tetsuo K. Combined microsurgical and endovascular modalities for complex intracranial aneurysms. *Neurosciences (Riyadh)* 2008; 13 (Suppl): 28.

Sami AS. Aneurysm coiling in sub-arachnoid hemorrhage. *Two years Egyptian experience and follow-up. Neurosciences (Riyadh)* 2003; 8 (Suppl): 45.