

Ruptured giant middle cerebral artery aneurysm in infancy

Reem A. Al-Youbi, MBChB, Mohammed S. Binmahfoodh, MBChB, FRCSC, Hayat Z. Kamfar, MBBCh, CABP, Mohammed M. Jan, MBChB, FRCPC.

ABSTRACT

يعد توسع الأوعية الدموية في الدماغ نادر الحدوث لدى الأطفال مع العلم أن انفجارها يعد أكثر ندرة حتى في دراسات ما بعد الوفاة. نقدم في هذه الورقة العلمية تقرير عن حالة انفجار لتوسع دموي ضخم بالدماغ لدى طفلة تبلغ من العمر 11 شهراً فقط. وقد أحضرت الطفلة نظراً لأصابتها بغيبوبة مفاجئة و تشنجات عصبية. وقد تم إيقاف التوسع الدموي جراحياً بعد إزالة النزيف. وقد تحسنت حالتها تدريجياً مع وجود ضعف عضلي بالجانب الأيمن من الجسم. لقد تم التأكد من علاج التوسع بواسطة أشعة الأوعية الدموية باستخدام الصبغة. وتبين من خلال متابعة حالة الطفلة أنها تعاني من تأخر حركي وتشنجات عصبية جزئية متكررة. وبعد ذلك تمكنت الطفلة تدريجياً من المشي بصورة مستقلة عند السنة الثالثة من العمر بعد تقديم العلاج الطبيعي لها والتأهيل. نستنتج من هذه الحالة أن توسع الأوعية الدموية بالدماغ يجب أن يتم التأكد من حدوثه لدى الأطفال المصابين بعلامات ارتفاع ضغط الدماغ الحاد حيث أنه من الممكن علاجه بالمستشفيات التي تمتلك وحدة لجراحة الأعصاب.

Intracranial aneurysms are uncommon in children. Rupture of giant intracranial aneurysms is extremely uncommon in infants even in autopsy studies. In this report, we present an unusual case of ruptured giant middle cerebral artery aneurysm in an 11-month-old female infant who presented acutely with unresponsiveness and seizures. The aneurysm was clipped during an urgent craniotomy for evacuation of an associated hematoma. She recovered slowly with mild residual right-sided weakness. Follow up arterial angiography revealed no residual or other aneurysms. Further follow up revealed motor delay and recurrent partial seizures. Active physiotherapy was performed and she could walk independently by 3 years of age. We conclude that intracranial aneurysms have to be considered in the differential diagnosis of infants presenting with acute raised intracranial pressure. Favorable outcome is noted in children who are managed promptly in hospitals with neurosurgical units.

Neurosciences 2012; Vol. 17 (2): 161-164

From the Department of Pediatrics (Al-Youbi, Kamfar, Jan), Faculty of Medicine, King Abdul-Aziz University, and the Department of Neurosciences (Binmahfoodh), King Faisal Specialist Hospital & Research Center, Jeddah, Kingdom of Saudi Arabia.

Received 28th August 2011. Accepted 14th November 2011.

Address correspondence and reprint request to: Prof. Mohammed M. Jan, Professor and Consultant of Pediatric Neurology, Department of Pediatrics, Faculty of Medicine, King Abdul-Aziz University, PO Box 80215, Jeddah 21589, Kingdom of Saudi Arabia. Tel. +996 (2) 6401000 Ext. 20208. Fax. +996 (2) 6403975. E-mail: mmsjan@yahoo.ca

Intracranial aneurysms are rare in children and represent less than 5% of the total population of patients who have undergone surgery for aneurysms.^{1,2} The proportion of ruptured aneurysms in children <15 years of age is even less common, and estimated at less than 1%. Rupture of intracranial aneurysms is potentially life threatening and frequently presents with subarachnoid rather than intracerebral hemorrhage.^{1,2} Aneurysms in infants are extremely uncommon even in autopsy studies. The most common location for such aneurysms in children includes the internal carotid artery (ICA) bifurcation (50%), middle cerebral artery (MCA) distal to the first major bifurcation (40%), and the vertebrobasilar system in 10%.³ Giant aneurysms occur in up to 50% of pediatric cases as compared to 27% in adults. However, multiple aneurysms are less common in children (3-5%) than in adults (10-20%). The occurrence of aneurysms is probably the result of an interplay between congenital factors (changes in the vessel wall) and hemodynamic stresses. Once discovered, the rebleeding rate in children is very high reaching up to 60%, which is more than double the adult figures.⁴ In this report we present an unusual case of ruptured giant MCA aneurysm in an infant who presented acutely and successfully treated by surgical evacuation and clipping.

Case Report. An 11-month-old girl presented to the emergency unit with acute lethargy and

unresponsiveness followed by generalized tonic clonic seizures. She was previously healthy with no recent history of fever or trauma. Her initial Glasgow coma scale was 6 with tense anterior fontanel and fixed dilated left pupil. She was immediately intubated, and an urgent brain CT scan revealed large left temporo-parietal intracranial hemorrhage extending to the sylvian fissure (Figure 1). She was mechanically ventilated, loaded with phenytoin, and received mannitol. She was then taken to the operating room for urgent craniotomy and evacuation of the hematoma. During the procedure, a giant left MCA aneurysm was evident. After consulting with the family, clipping of the giant aneurysm was performed. Post-operative CT demonstrated the successful evacuation of the intracerebral hematoma and clipping of the left MCA aneurysm with some ischemic changes involving the left sylvian region and temporal lobe (Figure 2). Magnetic resonance angiography (MRA) was also requested and revealed paucity of the left MCA branches with filling of the main MCA, both suggestive of successful clipping (Figure 3). She recovered slowly with mild residual right-sided weakness, including the face, and partial oculomotor nerve palsy. Follow up arterial angiography revealed no residual or other aneurysms. On further follow up, she had motor delay and recurrent partial seizures that required several antiepileptic drug trials. A brain MRI revealed a residual left MCA territory ischemic infarction. Active physiotherapy was performed and she could walk independently by 3 years of age. Visual and hearing assessments were within normal limits. On last follow up at age 3.5 years, she was functioning independently and remained seizure free for 7 months on topiramate and levetiracetam.

Discussion. Intracranial aneurysms are extremely uncommon in the pediatric population and their epidemiology is poorly understood, and certain features make them unique.¹⁻⁴ Aneurysms in children younger than 5 years of age are even less common, and most of these cases occur during the first 2 years of life.⁵ The incidence of aneurysms in children decreases with age: the proportion of ruptured aneurysms in patients younger than 20 years is approximately 3.5%, and that in patients younger than 15 years is less than 1%. In this report, we presented a more unusual case of an infant with ruptured giant MCA aneurysm. Most ruptured aneurysms in children (up to 52%) present with features

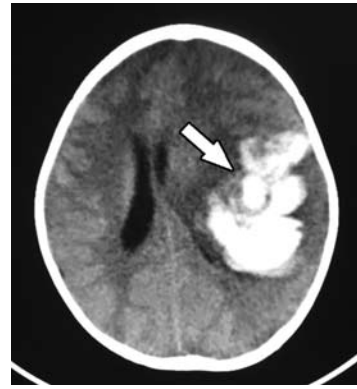


Figure 1 - Initial CT scan demonstrating the large parenchymal hematoma in the left temporo-parietal region with significant surrounding edema and ischemic changes.

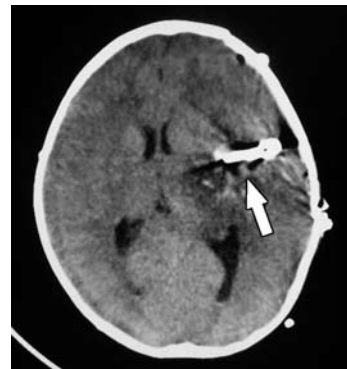

Figure 2 - Post-operative CT scan demonstrating the successful evacuation of the intracerebral hematoma and clipping of the left middle cerebral artery aneurysm. Some ischemic changes are noted in the left sylvian region and temporal lobe.

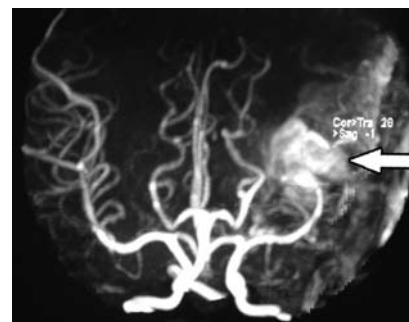

Figure 3 - Post-operative contrast enhanced 3-dimensional magnetic resonance angiography demonstrating the successful clipping of the left middle cerebral artery aneurysm with filling of the main artery and paucity of its branches.

of subarachnoid hemorrhage. Our patient presented with raised intracranial pressure (mass effect) as a result of the intracerebral hemorrhage. This is an extremely rare presentation that is potentially life threatening. Our infant is a girl; however, male preponderance in pediatric aneurysms has been reported.¹⁻⁵ This is different from adults where female predominance occurs, likely as a result of hormonal changes that affect collagen vascular support.

Several factors have been linked to the occurrence of aneurysms in children including congenital vascular wall changes and hemodynamic stresses. A congenital vascular wall defect could be the initiating factor.⁶ Intimal pathophysiological alteration by hemodynamic forces usually occurs at arterial bifurcations as a result of greater shearing forces. The pulsating blood pressure can produce structural fatigue in the arterial wall and degeneration of the internal elastic lamina. The role of hemodynamic factors is clearly illustrated by the preponderance of internal carotid artery (ICA) bifurcation aneurysms. Other possible etiologies, triggers, and associations with cerebral aneurysms include head injury (including birth trauma), infection (mycotic aneurysms), fibromuscular dysplasia, subacute bacterial endocarditis, and coarctation of the aorta, sickle cell anemia, collagen vascular disease, Ehlers-Danlos syndrome, Marfan syndrome, and autosomal dominant polycystic kidney disease. These conditions should be carefully excluded in children with symptomatic aneurysms. An infectious process and blunt trauma in particular can produce a tear in the internal elastic lamina with a higher incidence in children as compared to adults. Aneurysms due to direct trauma (pseudo aneurysms) lack an endothelial lining and are rare in children. Based on these multiple etiological factors, the development of cerebral aneurysms in children is an association between congenital predisposition, hemodynamic stresses, and other acquired factors affecting the vessel wall.

Radiologically, conventional angiography remains the gold standard for preoperative diagnosis, but CT, MRI, and MRA frequently reveal the aneurysm.⁷ In addition to associated hemorrhage, a focal hyperdense mass with or without enhancement may be seen on CT. A focal mass that is of different signal than the surrounding hemorrhage with or without flow void or enhancement can be seen on MRI. An MRA can define

aneurysms as small as 3-4 mm; however, no visualization of an aneurysm may be encountered secondary to adjacent vascular spasm. The ICA bifurcation is the main location of aneurysms in children in up to 50%, however, this location accounts for only 2% of cerebral aneurysms in adults. As in our patient, the main location on the MCA is the segment distal to the first major bifurcation (M2) in approximately 40% of cases. The frequency of aneurysms in the posterior circulation remains controversial. Some authors have described a proportion of <16% of aneurysms in the vertebrobasilar system and others have reported a rate of 30-57%.⁴ In contrast, an aneurysm in adults shows a predilection for proximal branch points and the anterior circulation. The prevalence of large (giant) aneurysms in children is around 50% compared with 27% in adults. On the other hand, multiple aneurysms are less common in children (3-5%) than in adults (10-20%).

Once diagnosed, rebleeding is very common, occurring in 52-60% of children.⁴ This incidence is significantly higher than the estimated 16-29% in adults. Therefore, surgical intervention is generally recommended at the time of diagnosis. A metal clip is typically used to obliterate the aneurysmal sac. However, other techniques can be used in young children including microanastomosis, bypass procedures, hypothermic arrest, and an endovascular approach in order to better handle the small size and fragility of their vessels.⁸ The post-operative morbidity and mortality are lower in children as compared with adults. Their vessels are healthier with less risk of vasospasm and lack of underlying atherosclerotic disease. The mortality in the first 48 hours following the first cerebral hemorrhage is 14-34% in adults compared with 11-12% in children with a percentage of good outcome reaching 75%.⁸ The combination of good outcome and high risk of rebleeding in children results in the recommendation of early surgical intervention.

We conclude that intracranial aneurysms have to be considered in the differential diagnosis of infants presenting with raised intracranial pressure, although the incidence of such cases is rare. Since no valid screening parameter is available, diagnosis is often made only after rupture, particularly with giant aneurysms. Favorable outcome is noted in children who are managed promptly in hospitals with neurosurgical units.

References

1. Buis DR, van Ouwerkerk WJ, Takahata H, Vandertop WP. Intracranial aneurysms in children under 1 year of age: a systematic review of the literature. *Childs Nerv Syst* 2006; 22: 1395-1409.
2. Pinto FC, Valiengo L, Santos PP, Matushita H, Plese JP. Intracranial arterial aneurysms in childhood: case report. *Arg Neuropsiquiatr* 2006; 64: 676-680.
3. Wojtacha M, Bazowski P, Manderka M, Krawczyk I, Rudnik A. Cerebral aneurysms in childhood. *Childs Nerv Syst* 2001; 17: 37-41.
4. Proust F, Toussaint P, Garnieri J, Hannequin D, Legars D, Houtteville JB, et al. Pediatric cerebral aneurysms. *J Neuro Surg* 2001; 94: 733-739.
5. Vaid VK, Kumar R, Kalra SK, Mahapatra AK, Jain VK. Pediatric intracranial aneurysms: an institutional experience. *Pediatr Neurosurg* 2008; 44: 296-301.
6. Giussani C, Mejdoubi M, Tremoulet M, Roux FE. The role of surgery when endovascular treatment is considered the first choice therapy for ruptured intracranial aneurysms. *J Neurosurg Sci* 2008; 52: 61-69.
7. Peron S, Jimenez-Roldán L, Cicuendez M, Millán JM, Ricoy JR, Lobato RD, et al. Ruptured dissecting cerebral aneurysms in young people: report of three cases. *Acta Neurochir (Wien)* 2010; 152: 1511-1517.
8. Lv X, Jiang C, Li Y, Yang X, Wu Z. Endovascular treatment for pediatric intracranial aneurysms. *Neuroradiology* 2009; 51: 749-754.

STATISTICS

Excerpts from the Uniform Requirements for Manuscripts Submitted to
Biomedical Journals updated November 2003.
Available from www.icmje.org

Describe statistical methods with enough detail to enable a knowledgeable reader with access to the original data to verify the reported results. When possible, quantify findings and present them with appropriate indicators of measurement error or uncertainty (such as confidence intervals). Avoid relying solely on statistical hypothesis testing, such as the use of *P* values, which fails to convey important information about effect size. References for the design of the study and statistical methods should be to standard works when possible (with pages stated). Define statistical terms, abbreviations, and most symbols. Specify the computer software used.