

# Chronic inflammatory demyelinating polyneuropathy following malignant melanoma

Mohamad B. Dbouk, MD, Shabriar Nafissi, MD, Askar Ghorbani, MD.

## ABSTRACT

يعد حدوث التزامن بين اعتلال الأعصاب المزيل للميالين مع سرطان الجلد (الورم الميلاني الخبيث) من الأمور النادرة الحدوث. على الرغم من أن هذا الاجتماع قد يكون ظاهرة مقبولة من الناحية البيولوجية نظراً للأصل المشترك جنينياً للخلايا الصبغية، وخلايا شوان، وثبوت التشابه في الأجسام المضادة إلا أنه لم يتم الإبلاغ سوى عن عدد قليل من مثل هذه الحالات حتى الآن. نستعرض في هذا التقرير حالتين جديدتين من اعتلال الأعصاب المزيل للميالين بالتزامن مع الورم الميلاني الخبيث، ونعتقد أن ذلك سوف يضيف المزيد من الأدلة على وجود ترابط بين هذين المرضين. ولقد تضمن تقريرنا أيضاً مراجعة قصيرة لحالات مماثلة.

Polyneuropathy has rarely been encountered in association with melanoma. Although this association may be a biologically plausible phenomenon considering the common embryonic origin of the melanocytes and Schwann cells with proven antibody cross reactivity, only few such cases have been reported so far. We report 2 new cases of chronic inflammatory demyelinating polyneuropathy in association with malignant melanoma, which we believe will add more evidence of this association. We also include a short review of the literature for similar cases.

*Neurosciences 2012; Vol. 17 (2): 167-170*

*From the Department of Neurology, Shariati Hospital, Tehran University of Medical Sciences, Tehran, Iran.*

*Received 22nd June 2011. Accepted 30th December 2011.*

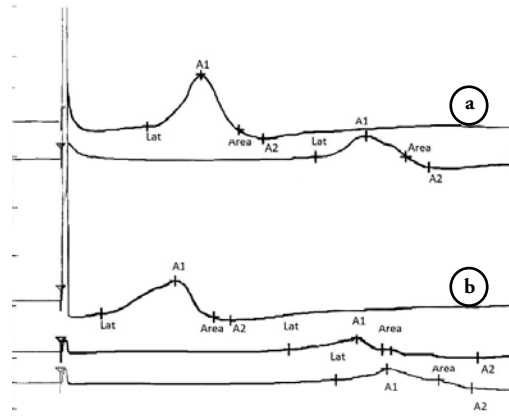
*Address correspondence and reprint request to: Dr. Mohamad B. Dbouk, Department of Neurology, Shariati Hospital, Tehran University of Medical Sciences, North Karegar Street, PO Box 19857-43453, Tehran 14114, Iran. Tel. +98 (218) 4902390. E-mail: Aly\_2024@yahoo.com*

Chronic inflammatory demyelinating polyneuropathy (CIDP), not an infrequent disease, has been reported to occur in association with some malignant diseases.<sup>1</sup> Its association with malignant

melanoma has been increasingly rare, despite the fact that this association may be a biologically justified phenomenon considering the common embryonic origin of the melanocytes and Schwann cells with proven antibody cross reactivity. We report 2 new cases of chronic inflammatory demyelinating polyneuropathy in association with malignant melanoma. In one of our patients, the melanoma was actually discovered during the workup of the neuropathy. Interestingly no primary skin tumor origin was detected. These cases, we believe, will add more evidence of the association between CIDP and malignant melanoma and perhaps justify the suspicion that similar cases are being missed. We also include a short review of the literature for similar cases.

**Case Report. Patient One.** This 52-year-old man was referred with severe progressive muscle weakness. His symptoms started 3 months earlier with pain and paresthesia in the feet. On examination he had dyspnea, bilateral facial weakness, and generalized and severe muscle weakness (1-2/5 Medical Research Council [MRC] scale). The clinical and electrophysiological (Table 1) findings fulfilled the criteria for CIDP.<sup>1</sup> Six years earlier, he was treated for ocular malignant melanoma with surgery and 12 sessions of chemotherapy using dacarbazine, cisplatin, and vinblastin with virtual remission. Three years later, liver metastasis was discovered and he had been receiving tamoxifen since that time. We started a course of plasmapheresis (5 every other day sessions) and 70 mg daily prednisone. He improved significantly and was discharged with muscle forces of 3-4/5. Two years follow-up with gradual tapering of prednisone showed definite improvement of all muscle forces, which were 5/5 in upper and lower limbs on the last examination. Repeated nerve conduction studies showed significant improvement in different indices.

**Patient 2.** This 58-year-old woman felt numbness and paresthesia of the legs 8 months before admission,



**Figure 1** - Conduction blocks in the median (a) and ulnar (b) nerves.

and gradually developed difficulty in walking. Clinical and electrophysiological (Table 1) findings fulfilled the criteria for CIDP.<sup>1</sup> Figure 1 illustrates conduction blocks in the median and ulnar nerves. She was treated with a course of plasmapheresis and 60 mg daily prednisone with significant improvement. We noticed right leg edema and performed leg Doppler and abdominopelvic sonographies for evaluation; multiple para-aortic lymph nodes were discovered. Biopsy of the largest node showed metastatic melanoma. Thorough inspection failed to reveal any skin origin for the tumor. Unfortunately, the underlying disease progressed despite several courses of chemotherapy and she died with severe pulmonary edema and respiratory failure after one year.

**Table 1** - Nerve conduction studies of patients with melanoma and chronic inflammatory demyelinating polyneuropathy.

Nerves studied	Patient 1				Patient 2			
	Md	Ul	Pero	Tib	Md	Ul	Pero	Tib
<i>Distal latency (m/s)</i>								
At presentation	13.9	10.8	NR	NR	8.6	3.3	3.1	NR
Follow-up study	4.4	3.9	NR	NR	ø	ø	ø	ø
<i>Conduction velocity (m/s)</i>								
At presentation	NR	12.3	NR	NR	12.5	10.3	17.1	NR
Follow-up study	32.9	34.6	NR	NR	ø	ø	ø	ø
<i>Amplitude (mV) distal/proximal</i>								
At presentation	1.3/NR	0.4/0.2	NR	NR	5.1/2.5	3.1/1.6	1.6/0.7	NR
Follow-up study	7.7/6.7	6.3/5.7	NR	NR	ø	ø	ø	ø
<i>Sensory: amplitude (µV) (conduction velocity, m/s)</i>								
At presentation	NR	NR	NR	NR	NR	NR	NR	NR
Follow-up study	12.9 (44)	18 (31)	NR	NR	ø	ø	ø	ø
<i>Duration (ms) distal/proximal</i>								
At presentation	13.9/NR	10.2/11.3	NR	NR	8.2/10	11.8/14	7/11.9	NR
Follow-up study	7/7.9	7.7/8.1	NR	NR	ø	ø	ø	ø

Md - median nerve, Ul - ulnar nerve, Pero - peroneal nerve, Tib - tibial nerve, Rd - radial nerve, NR - no response, ø - follow up study not made, numbers in italics are in the demyelinating range

**Table 2** - Previously reported cases of melanoma associated chronic inflammatory demyelinating polyneuropathy.

Patient (by author)	Gender	Primary tumor site/lesion discovered	Revealing symptoms: tumor versus neuropathy	Delay	Previous melanoma treatments	Associated diseases
Bird 1 <sup>2</sup>	Male	Unknown/axillary lymph node	Neuropathy		None	Patchy vitiligo Vitiligo
Bird 2	Male	Unknown/axillary lymph node	Neuropathy		None	
Bird 3	Male	Skin nodule over left breast	Tumor	1 year	Radiation	
Palma <sup>3</sup>	Male	Unknown/pulmonary nodule (metastatic)	Tumor	10 months	Interferon-α-2b	
Anthony <sup>4</sup>	Female	Upper arm lentigo malignant melanoma	Tumor	11 years	Surgery, interferon-α	
Weiss <sup>5</sup>	Female	Melanoma primary lesion site not reported	Tumor	12 years	Surgery, interferon-α IL-2 vaccine	
Rousseau <sup>6</sup>	Male	Skin nodule; melanomatous nature not diagnosed until start of neuropathy	Neuropathy	2 years	Liquid nitrogen	
Ben Simon <sup>7</sup>	Female	Cutaneous melanoma/uveitis	Tumor	1 month		
Antoine <sup>8</sup>	Male	Not mentioned	Neuropathy	10 years		

**Discussion.** Only 9 cases have been reported so far; in 3 of whom the tumor was actually discovered after the neuropathy. One of our patients developed CIDP, and melanoma was subsequently discovered, but no skin origin could be identified. Bird et al<sup>2</sup> described 3 patients who developed CIDP in association with malignant melanoma. In 2 patients, melanoma was discovered during the initial evaluation for neuropathy and no melanocytic skin lesions were found, while the third patient developed CIDP one year after a skin nodule proved to be a malignant melanoma. Another case was reported by Palma & Martin-Algarra,<sup>3</sup> a 66-year-old man whose neuropathy emerged after the treatment of a solitary pulmonary nodule (metastatic malignant melanoma) with interferon alpha-2b. Similarly, a 55-year-old woman who had a melanoma for more than 10 years before developing CIDP was reported by Anthoney et al.<sup>4</sup> Her neurological symptoms started shortly after she received a course of interferon- $\alpha$ . Weiss et al<sup>5</sup> searched for antibodies in a 73-year-old man whose CIDP started 3 years after remission from a malignant melanoma, which had been treated with excision, alpha interferon, IL-2, and vaccination over a 15-year-period. Rousseau et al's case<sup>6</sup> was a 32-year-old man whose melanoma was revealed 8 months after neuropathy. Furthermore, the enucleation of a 21-year-old patient's eye, which had malignant melanoma, led to remarkable improvement in neuropathy symptoms.<sup>7</sup> In a case series of 422 patients with peripheral neuropathy, one patient suffering from a very chronic CIDP with severely decreased conduction velocities and temporal dispersion developed a malignant melanoma with a 10-year delay period of the neuropathy onset.<sup>8</sup> This association is unlikely to be completely coincidental, despite the rarity. Similarity of the embryonic origin of melanoma and Schwann cells is believed to cause similarity of several surface antigens. In one patient, antibodies against the monosialoganglioside GM2, sulfoglucuronyl glycolipids, and sulfatide were detected. Interestingly, the antibodies against GM2 had a strong reaction with a biopsy of the patient's own melanomatous tissue.<sup>5</sup> Another patient's IgM reacted with many of her tumor cells and co-localized with the ganglioside GQ1b.<sup>9</sup> It has been stated that the anti-melanoma antibodies are classified as monoclonal antibodies reactive against related carbohydrate determinants shared by human myelin-associated glycoprotein, neural cell adhesion molecule, and several protein and lipid glycoconjugates of the peripheral nervous system.<sup>10</sup>

Nine such patients have so far been reported whose reported characteristic clinical findings are summarized in Table 2. With the addition of our patients, there

are 11 cases (7 males and 4 females). In 5 patients, the onset of neuropathy preceded the discovery of the tumor. This was 3-8 months for 4 of them, and 10 years for the fifth. Seven patients were already under melanoma treatment when they developed neuropathy. Six patients were tested for anti-gangliosides antibodies, and 3 had significantly elevated levels. Three patients received interferon- $\alpha$  as a treatment for melanoma before developing CIDP. Interferon has been associated with developing CIDP on several other occasions, and this may be the case in these 3 patients.<sup>11</sup> All patients, whose follow-up information was available, had a good response of the neuropathy to standard treatments of CIDP (IVIg, plasmapheresis, and prednisone). After reviewing the electrophysiological findings of the reported patients, we could not find any specific pattern for melanoma associated CIDP.

In conclusion, we present 2 new cases of CIDP occurring in association with malignant melanoma. Unfortunately, we were unable to check for antibodies. It is difficult to determine whether this is an incidental association or is it a real pathogenic one. The present literature adding these cases supports the latter. However, more research is still needed, and we recommend searching for subtle neuropathic findings and associated antibodies in a large cohort of melanoma patients. Another question is whether any cases of melanoma are being missed, as in some patients the metastatic tumor was discovered during workup for neuropathy with unknown primary skin origin?

## References

1. Van den Bergh PY, Hadden RD, Bouche P, Cornblath DR, Hahn A, Illa I, et al. European Federation of Neurological Societies/Peripheral Nerve Society guideline on management of chronic inflammatory demyelinating polyradiculoneuropathy: report of a joint task force of the European Federation of Neurological Societies and the Peripheral Nerve Society - first revision. *Eur J Neurol* 2010; 17: 356-363.
2. Bird JS, Brown MJ, Shy ME, Scherer SS. Chronic inflammatory demyelinating polyneuropathy associated with malignant melanoma. *Neurology* 1996; 46: 822-824.
3. Palma JA, Martin-Algarra S. Chronic inflammatory demyelinating polyneuropathy associated with metastatic malignant melanoma of unknown primary origin. *J Neurooncol* 2009; 94: 279-281.
4. Anthoney DA, Bone I, Evans TRJ. Inflammatory demyelinating polyneuropathy: a complication of immunotherapy in malignant melanoma. *Ann Oncol* 2000; 11: 1197-1200.
5. Weiss MD, Luciano CA, Semino-Mora C, Dalakas MC, Quarles RH. Molecular mimicry in chronic inflammatory demyelinating polyneuropathy and melanoma. *Neurology* 1998; 51: 1738-1741.

6. Rousseau A, Salachas F, Baccard M, Delattre JY, Sanson M. Chronic inflammatory polyneuropathy revealing malignant melanoma. *J Neurooncol* 2005; 71: 335-336.
7. Ben Simon GJ, McCann JD, Barth N, Goldberg RA, Glasgow BJ, Straatsma BR. Partial resolution of acute ascending motor polyneuropathy after enucleation of an eye with metastatic melanoma. *Br J Ophthalmol* 2004; 88: 847.
8. Antoine JC, Mosnier JF, Absi L, Convers P, Honnorat J, Michel D. Carcinoma associated paraneoplastic peripheral neuropathies in patients with and without anti-onconeural antibodies. *J Neurol Neurosurg Psychiatry* 1999; 67: 7-14.
9. Kloos L, Sillevs Smitt P, Ang CW, Kruit W, Stoter G. Paraneoplastic ophthalmoplegia and subacute motor axonal neuropathy associated with anti-GQ1b antibodies in a patient with malignant melanoma. *J Neurol Neurosurg Psychiatry* 2003; 74: 507-509.
10. Noronha AB, Harper JR, Ilyas AA, Reisfeld RA, Quarles RH. Myelin-associated glycoprotein shares an antigenic determinant with a glycoprotein of human melanoma cells. *J Neurochem* 1986; 47: 1558-1565.
11. Meriggioli MN, Rowin J. Chronic inflammatory Demyelinating polyneuropathy after treatment with interferon-alpha. *Muscle Nerve* 2000; 23: 433-435.

## ***CASE REPORTS***

---

Case reports will only be considered for unusual topics that add something new to the literature. All Case Reports should include at least one figure. Written informed consent for publication must accompany any photograph in which the subject can be identified. Figures should be submitted with a 300 dpi resolution when submitting electronically or printed on high-contrast glossy paper when submitting print copies. The abstract should be unstructured, and the introductory section should always include the objective and reason why the author is presenting this particular case. References should be up to date, preferably not exceeding 15.