

Intracranial calcifications, microcephaly, and seizure

If not congenital infection, what could it be?

Wafaa Eyaid, MD, FACMG, Ruqaiyah S. Al-Tassan, MD, Doha M. Al-Nouri, PhD.

ABSTRACT

تنتج تكلسات داخل القحف عن مجموعة متنوعة من المسببات، وبين تلك المسببات هي الاضطرابات البيئية والتمثيل الغذائي والتي تؤثر على توازن الكالسيوم. وأهم العوامل البيئية المؤدية إلى تكلسات داخل القحف هي التهابات داء المقوسات الحلقي، والفيروس المضخم للخلايا. ويوجد هناك تقارير متزايدة عن حالات تكلسات خلقية داخل القحف في غياب تحاليل تأكيدية لتحليل متلازمة تورنش وهناك العديد من الحالات المبلغ عنها في جميع أنحاء العالم، ووصفت مثل هذه الحالات التي تتقاسم نفس العرض التقديمي بأنها متلازمة مثل العدوى الرائية الخلقية المتنجحة أو متلازمة تورنش الزائفة (OMIM 600158).

Intracranial calcification has a variety of etiologies; among those are environmental and metabolic disturbances involving calcium homeostasis. The main environmental factors resulting in intracranial calcification are congenital infections with toxoplasmosis, and cytomegalovirus. There are increasing reports on cases showing pictures of congenital infection in the absence of confirmative positive TORCH screen, and there are many cases reported worldwide sharing the same presentation labeled as autosomal recessive congenital infection-like syndrome or pseudo-TORCH syndrome (OMIM 600158).

Neurosciences 2012; Vol. 17 (3): 248-252

From the Department of Pediatrics (Eyaid, Al-Tassan), King Abdulaziz Medical City, and the Food Sciences & Agriculture College (Al-Nouri), King Saud University, Riyadh, Kingdom of Saudi Arabia.

Received 1st January 2012. Accepted 21st May 2012.

Address correspondence and reprint request to: Dr. Wafaa Eyaid, Assistant Professor of Pediatrics, Department of Pediatrics, Mail Code 1510, King Fahad National Guard Hospital, King Saud Bin Abdulaziz University for Health Sciences, PO Box 22490, Riyadh 11426, Kingdom of Saudi Arabia. Tel. +966 (1) 2520088. Ext. 12282. Fax. +966 (1) 2520088. Ext. 11461. E-mail: eyaidw@ngba.med.sa

There are an increasing number of congenital disorders that resemble features of congenital TORCH (toxoplasma, rubella, cytomegalovirus [CMV], herpes simplex, and others) infection such as intracranial calcification, microcephaly, thrombocytopenia, hepatomegaly, and abnormal liver function tests. These disorders include pseudo-TORCH, Aicardi-Goutières, and Hoyeraal-Hreidarsson syndromes.¹ As these syndromes may overlap in some features, it is important to define each syndrome to provide appropriate patient counseling. Herein, we report 7 children who presented with congenital microcephaly, growth retardation, and generalized tonic-clonic seizures. They also had intracranial calcification, hepatosplenomegaly, abnormal liver function tests, petechial rash, and thrombocytopenia. We present the details of these cases to familiarize pediatricians, neonatologists, and neurologists with such syndromes, in order for them to provide the proper management.

Case Report. The families' pedigrees are shown in Figure 1 and demographics, physical, and laboratory findings are summarized in Table 1.

Family I. Patient 1. The first case was born at full term to first cousin parents. The birth weight was 2.5 kg (<10%), length was 50 cm (25%), and head circumference (HC) was 30 cm (<10%). Developmental delay was noted at the age of 5 months. Examination at that time revealed microcephaly, with a HC of 37 cm (50% for one month). There was no tracking of movements. There was marked spasticity of the upper limbs and scissoring of the legs. A head CT showed brain atrophy, prominent ventricles, and scattered areas of calcification in the periventricular (PV) region and the posterior

Disclosure. The authors declare no conflicting interests, support or funding from any drug company.

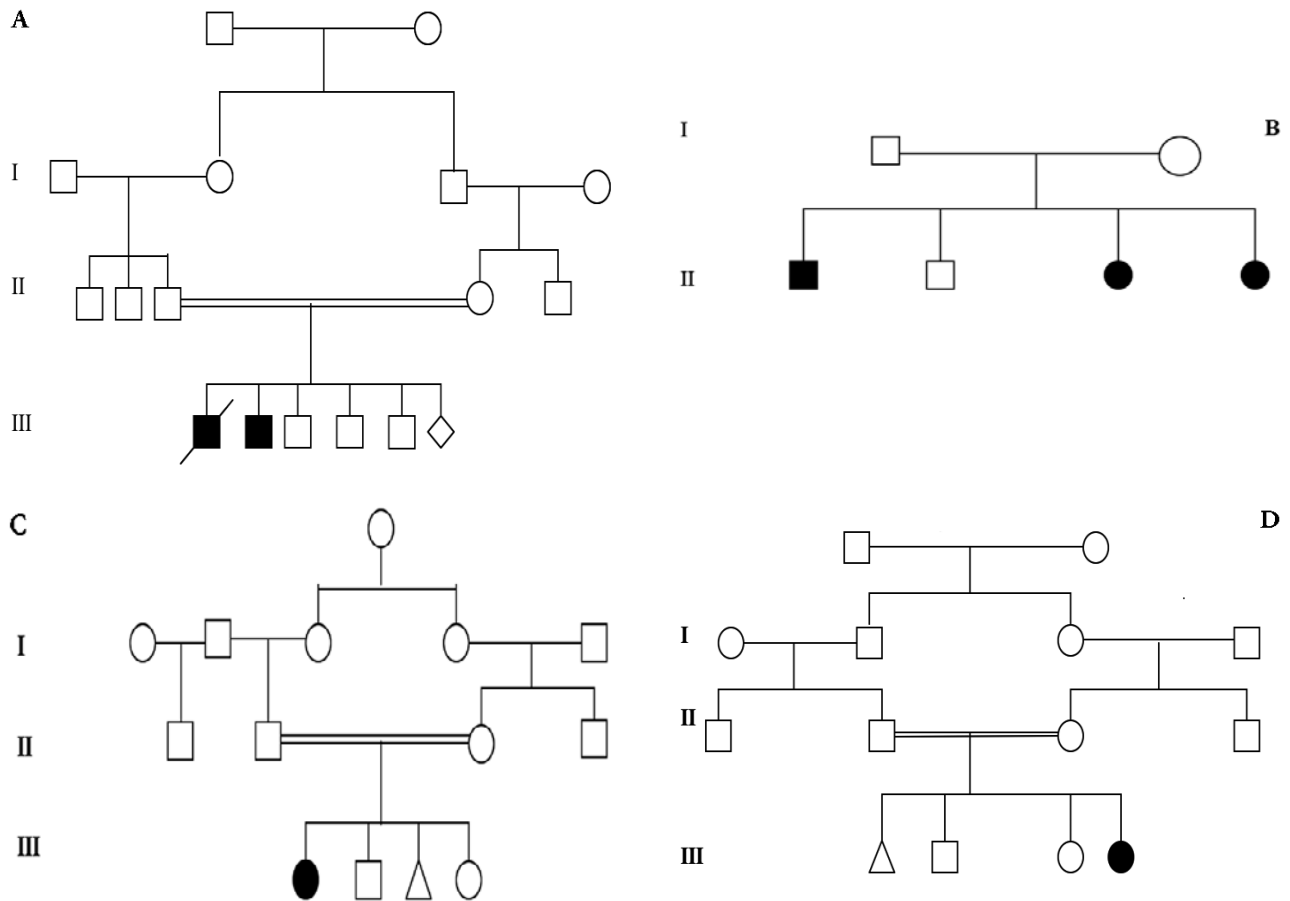


Figure 1 - The Family pedigrees of A) Family I; B) Family II; C) Family III; and D) Family IV.

Table 1 - Patients' demographics, physical, and laboratory findings.

Features	Family 1		Family 2			Family 3	Family 4
	Pt 1	Pt 2	Pt 1	Pt 2	Pt 3	Pt 1	Pt 1
Age at presentation	6 m	18 m	10 y	5 y	14 m	3 y	Birth
Consanguinity	+	+	+	+	+	+	+
Gender	M	M	M	F	F	F	F
Microcephaly	+	+	+	+	+	+	+
Spasticity	+	+	+	+	+	+	+
Seizure EEG	+	+	+	+	+	+	+
Calcification	+	+	+	-	+	+	+
Hepatosplenomegaly	-	+	-	-	-	-	-
Abnormal LFT	-	-	-	-	-	-	+
Petechial rash	-	+	-	-	-	-	-
Thrombocytopenia	-	+	-	-	-	-	+
Eye/optic fundi	myopic	N	squint	N	N	N	Cataract
CMV IgM	-	-	-	N	-	-	-
CMV IgG	-	+	+	-	+	-	-
Urine culture	-	+	-	-	-	-	-
Toxoplasma	-	-	-	-	-	-	-
Metabolic screen	N	N	N	N	N	N	N

LFT - liver function test, CMV - cytomegalovirus, IgM - immunoglobulin M, IgG - immunoglobulin G, Pt - patient, m - months, y - years, + - positive, - - negative, N - normal

fossa. The TORCH screening was negative. The visual evoked potential (VEP) and electroretinogram (ERG) tests were subnormal. The patient had a febrile illness at 6.5 months of age that resulted in apnea, cyanosis, and, eventually, brain death. The family was told that the cause of death was congenital infection.

Patient 2. The second case was born at full term with APGAR scores of 9/9 at one and 5 minutes. The birth weight was 2.9 kg (<10%), length was 48 cm (25%), and HC was 31 cm (<10%). At birth the infant was noted to have petechial skin rash, hepatosplenomegaly, and thrombocytopenia and required intensive care unit admission. A head CT scan showed extensive periventricular calcification (Figure 2). An MRI of the brain performed one year later showed loss of predominantly white matter and some gray matter with atrophy of the basal ganglia (Figure 3). Testing was positive for CMV IgG antibodies, but negative for IgM

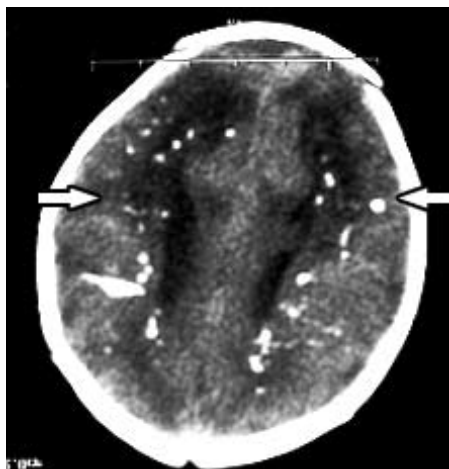


Figure 2 - Brain CT scan of family I, patient 2, showing extensive periventricular calcification.

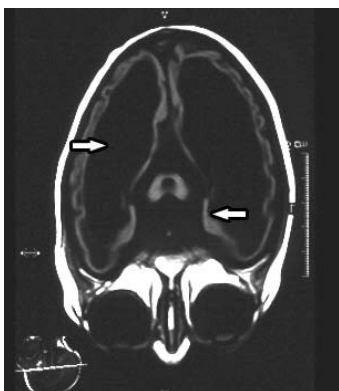


Figure 3 - Brain MRI of family I, patient 2, showing loss of predominantly white matter and some gray matter with atrophy of the basal ganglia.

antibodies. Early CMV antigen (Ag) was detected by immunofluorescence (IF) after an 18-hour incubation of a urine sample. Ganciclovir was started. An eye exam showed lightly pigmented fundi. After discharge from the hospital, frequent seizures developed. There were delayed milestones (not babbling, tracking, or rolling over by 10 months of age). The patient was referred to the genetics clinic where examination revealed a small face and mouth, microcephaly, with a HC of 39 cm (50% for 4 months), a weight of 5 kg (50% for 3 months), and length of 72 cm (50% for one year). The CNS examination showed hypertonia and hyperreflexia of the upper and lower limbs with adducted thumbs.

Family II. Patient 1. The first case in the second family was born at term. The prenatal and perinatal periods were uncomplicated. Parents are not consanguineous. The birth weight was 2.8 kg (10%). Seizures and excessive drooling developed at the age of 9 months. Examination at that time revealed microcephaly, with a head circumference of 48.5 cm (50th percentile for one year). There was peripheral hypertonia and hyperreflexia in the upper and lower limbs with central hypotonia. The metabolic screen was unremarkable. The head CT revealed brain atrophy with multiple areas of calcification. An eye exam showed myopia, and a hearing exam was normal. Laboratory investigations, including complete blood count (CBC) and liver function tests (LFTs) were normal. Testing for CMV IgG antibodies was positive. Urine culture for CMV was negative. Testing for toxoplasmosis IgM and IgG antibodies was negative.

Patient 2. The second case was born at full term. The first presentation was with a right-sided seizure and global developmental delay. On examination, the HC was 45 cm (50th percentile for 10 months), weight was 10.8 kg (50th percentile for one year), and length was 90 cm (50th percentile for 2 years). The CNS examination showed hypertonia and hyperreflexia in all limbs. The brain CT showed moderate dilatation of the lateral ventricles, but no evidence of intracranial calcification. The EEG showed diffuse background slowing with superimposed right posterior fossa slowing. The hematological and LFTs were normal. Testing for toxoplasma antibodies was negative.

Patient 3. The third case was born at full term with a birth weight of 2.5kg (25%), length (75%), and HC of 32 cm (10%). Seizures developed at the age of 6 months. Examination at 14 months of life showed a body weight of 7 kg (50th percentile for 6 months), length was in the 50th percentile for 10 months, and HC was on the 50th percentile for 5 months. There was no evidence of visual tracking. There was marked head lag and marked spasticity of all limbs, worse on the right. The metabolic

screen was unremarkable. A head CT revealed marked dilatation of the left lateral ventricle, subependymal calcifications in the wall of the lateral ventricle, scattered parenchymal calcifications in both cerebral hemispheres, and loss of white matter adjacent to the lateral ventricles (Figure 4). A brain MRI showed periventricular and basal ganglia calcifications in addition to enlargement of the left lateral ventricle (Figure 5). The laboratory tests, including CBC and LFTs, were normal. The CMV IgG antibodies were elevated, whereas, IgM antibody levels were normal. Toxoplasma IgG antibodies levels were also elevated.

Family III. Patient 1. The first case was born at full term to first cousins parents. Congenital microcephaly was found antenatally. Global developmental delay, seizures, and profound hearing loss were detected later. A head CT showed intracranial calcifications, and an MRI of the brain revealed extensive white matter

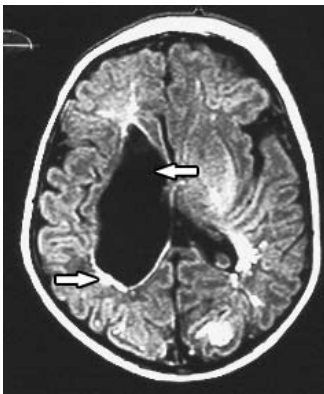

Figure 4 - Brain MRI of family II, patient 3, showing marked dilatation of the left ventricle, subependymal calcifications in the wall of the lateral ventricle, scattered parenchymal calcifications in both cerebral hemispheres and loss of white matter adjacent to the lateral ventricles.

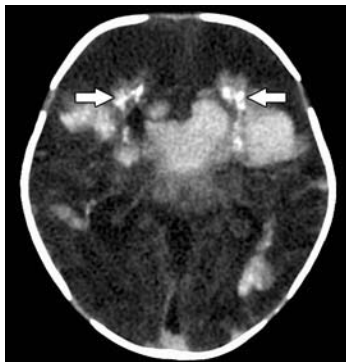


Figure 5 - Brain CT scan of family IV, patient 1, showing periventricular and basal ganglia calcifications in addition to enlargement of the left lateral ventricle.

changes. A TORCH screen was negative. A metabolic screen including mass spectrometry, and urine GCMS for organic acids was also negative.

Family IV. Patient 1. The first case was born at full term to consanguineous parents. The birth weight was 2.0 kg, with a HC of 32 cm (25th percentile). Antenatal ultrasound showed dilated cranial ventricles bilaterally with dilatation of the anterior horns and the posterior fossa. At birth, the patient developed apnea that needed resuscitation, and ventilation. Seizures developed in the first few hours of life, and they were responsive to conventional anticonvulsants. Examination showed a wide, tense anterior fontanel, a wide posterior fontanel, widely separated sutures, and bilateral joint stiffness in the upper and lower limbs. The CNS examination showed hypertonia and hyperreflexia of the upper and lower limbs. An eye exam diagnosed bilateral cataracts, but retinal examination was normal with no signs of chorioretinitis. There was no hepatosplenomegaly. Head ultrasound showed grade IV intraventricular hemorrhage. A head CT confirmed the presence of hemorrhage and showed periventricular calcifications (Figure 6). Laboratory findings showed elevated liver enzymes, a normal leukocyte count, and normal hemoglobin. The patient developed thrombocytopenia on the second day of life. Serological titers for rubella, CMV, toxoplasma, and herpes virus were normal in both the infant and mother. Urine cultures for CMV were negative.

Discussion. The causes of microcephaly with intracranial calcification are multiple. Aicardi-Goutières syndrome is a progressive encephalopathy with an onset in the first year of life and a recessive autosomal pattern of inheritance. The syndrome is characterized by acquired microcephaly, characteristic basal ganglia calcifications,

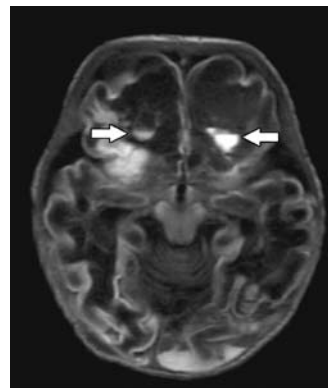


Figure 6 - Brain MRI of family IV, patient 1, showing hemorrhage and periventricular calcifications.

white matter abnormalities, chronic cerebrospinal fluid (CSF) lymphocytosis, and raised interferon-alpha (INF-alpha) in the CSF.¹ Unlike this syndrome, babies are usually born with normal HC. All our patients had antenatal microcephaly, and a different calcification distribution. Other differential diagnosis of intracranial calcification, considering the white matter abnormalities, should include other forms of leukodystrophy associated with metabolic defects, for example, Krabbe globoid cell leukodystrophy, and metachromatic leukodystrophy, which are not associated with intracranial calcification. Intrauterine infection due to the TORCH group and syphilis present a diagnostic dilemma, as their clinical features overlap and may initially be indistinguishable. Due to the varied clinical course reported for congenital intrauterine infections, and consistent clinical findings, we initially entertained a diagnosis of congenital CMV infection for some of our patients. However, this was excluded by the negative results of repeated immuno virologic studies, and the failure to recover viral inclusions in urine culture and to isolate *Toxoplasma* organisms. Also, the birth of a second affected child made the diagnosis of congenital infection doubtful.

The first 2 cases of a congenital infection-like syndrome were described in 1983 by Baraitser et al.² In the cases reported here, we found that all patients shared a very similar clinical picture characterized by congenital microcephaly, seizures, and radiological findings of intracranial calcification, with or without hepatosplenomegaly. The second child in Family I is the only patient who showed evidence of CMV infection, which is considered insignificant because of the prevalence of the CMV infection after the neonatal period. There was a diagnosis of cataract in one patient in Family IV, which is a characteristic feature of congenital intrauterine infection, despite negative TORCH screening. That patient had abnormal antenatal ultrasound of the brain, and a grade IV intraventricular hemorrhage, which is similar to the cases reported before by Knoblauch et al.³ However, Knoblauch's cases did not have cataract.³ Our case may be similar to the case reported by Al-Gazali et al.⁴ for a male infant, who had hepatomegaly. Detailed eye examination showed bilateral cataracts. The brain CT scan showed a large hemorrhage in the middle of the brain, and there was calcification in the periventricular white matter. That case along with other similar cases from a large consanguineous family from the United Arab Emirates was found to harbor a homozygous mutation

in the tight-junction protein gene *JAM3*.⁵ The patterns of calcification and other clinical findings of our patients are not consistent with the recently reported patients with band-like calcification and simplified gyration and polymicrogyria, with a mutation in the tight junction protein gene *OCNL*.⁶ Our cases seem to belong to the pseudo - TORCH syndrome in view of the presence of congenital microcephaly with intracranial calcification, and negative results from serum, urine, and CSF studies for similar illnesses.

In conclusion, the clinical presentations of the cases described here and the cases previously reported in the literature showed clinical variation that might represent different mutations of the same gene, namely, allelic heterogeneity, or have other genetic loci. The phenotype has not yet been clearly elucidated, which would help in recognizing single cases/first case in a non-consanguineous marriage. That can only be confirmed or ruled out by further molecular studies of these families once the underlying genetic defect has been identified. Finally, reporting these cases should alert the pediatricians, neurologists, and neonatologists to provide proper care, and counseling for these families.

Acknowledgments. *The author would like to thank Dr. Vijay Palkar for reporting the radiology films.*

References

1. Reardon W, Hockey A, Silberstein P, Kendall B, Farag TI, Swash M. Autosomal recessive congenital intrauterine infection-like syndrome of microcephaly, intracranial calcification, and CNS disease. *Am J Med Genet* 1994; 52: 58-65.
2. Baraitser M, Brett EM, Piesowicz AT. Microcephaly and intracranial calcification in two brothers. *J Med Genet* 1983; 20: 210-212.
3. Knoblauch H, Tennstedt C, Brueck W, Hammer H, Vulliamy T, Dokal I, et al. Two brothers with findings resembling congenital intrauterine infection-like syndrome (pseudo-TORCH syndrome). *Am J Med Genet A* 2003; 120A: 261-265.
4. al-Gazali LI, Sztrihai L, Dawodu A, Varady E, Bakir M, Khdir A, et al. Complex consanguinity associated with short rib-polydactyly syndrome III and congenital infection-like syndrome: a diagnostic problem in dysmorphic syndromes. *J Med Genet* 1999; 36: 461-466.
5. Mochida GH, Ganesh VS, Felie JM, Gleason D, Hill RS, Clapham KR, et al. A homozygous mutation in the tight-junction protein *JAM3* causes hemorrhagic destruction of the brain, subependymal calcification, and congenital cataracts. *Am J Hum Genet* 2010; 87: 882-889.
6. O'Driscoll MC, Daly SB, Urquhart JE, Black GC, Pilz DT, Brockmann K, et al. Recessive mutations in the gene encoding the tight junction protein occludin cause band-like calcification with simplified gyration and polymicrogyria. *Am J Hum Genet* 2010; 87: 354-364.