

# Protracted disease course after deafness in a man with Brown-Vialetto-Van Laere syndrome

Samira Yadegari, MD, Keyvan Razmjoo, MD, Shabriar Nafissi, MD.

## ABSTRACT

تعد متلازمة براون فياليتو فان لاري نوعاً نادراً من أمراض الخلية العصبية الحركية والذي يظهر على شكل صمم ثنائي وإصابة وتخريب عدد من الأعصاب القحفية. ويعد هذا المرض أكثر شيوعاً لدى الإناث ولكن في حالة الإصابة المبكرة أو إصابة الرجال فإن تقدم المرض يكون سريعاً جداً. نستعرض في هذه المقالة تقريراً عن رجل مصاب بمتلازمة براون فياليتو فان لاري والذي لوحظ لديه وجود فترة زمنية أطول من المتوقع ما بين إصابته بالصمم وظهور علامات إصابة الجهاز العصبي الحركي. وبعد مرور 6 سنوات ساءت حالته بشكل تدريجي انتهاءً بالوفاة. تماشياً مع تنامي وتطور الخيارات العلاجية فإن هذه الحالة تؤكد وجوب اعتبار وجود متلازمة براون فياليتو فان لاري بعد فترة طويلة من الاستقرار حتى لدى الرجال.

Brown-Vialetto-Van Laere syndrome (BVVLS) is a rare type of motor neuron disease, characterized by bilateral deafness, and multiple cranial nerve involvement. The disease is more frequent in females, but rapid deterioration was attributed to male gender or early onset. Herein, we report a man with BVVLS who had a longer than expected interval between onset of deafness and other motor symptoms that culminated in diagnosis. Six years later, he had gradual worsening and death. Along with potential new developing therapeutic options, this case emphasizes considering the diagnosis of BVVLS especially after a long period of stability, even in men.

*Neurosciences 2012; Vol. 17 (3): 253-255*

*From the Department of Neurology, Shariati Hospital, Tehran University of Medical Sciences, Tehran, Iran.*

*Received 2nd May 2011. Accepted 26th January 2012.*

*Address correspondence and reprint request to: Dr. Shabriar Nafissi, Associate Professor of Neurology, Shariati Hospital, North Kavegar Street, Tehran 14114, Iran. Tel. +98 (21) 84902224. Fax. +98 (21) 22884420. E-mail: nafissi@sina.tums.ac.ir*

Brown-Vialetto-Van Laere syndrome (BVVLS), or progressive pontobulbar palsy with deafness is a rare degenerative disorder characterized by slow or rapid onset progressive bilateral deafness and cranial nerve involvement, usually the motor components of the seventh, ninth, tenth, eleventh, and twelfth cranial nerves. The spinal motor nerves, and less commonly the upper motor neurons may be involved.<sup>1</sup> This syndrome was first described in 1894 by Brown and subsequently by Vialetto in 1936 and Van Laere in 1967.<sup>2</sup> Sathasivam reviewed all reported cases until 2007, and retrieved 58 cases.<sup>3</sup> Herein, we report a man with BVVLS presenting with hearing loss, but despite the expected short course of the disease in men, other symptoms developed 15 years later. Our objective in presenting this particular case is to highlight that in BVVLS, other symptoms than hearing loss could present many years after disease onset.

**Case Report.** This man was first seen at the age of 37 in 2003. He developed gradual hearing loss, first right and after a few months on the left side, accompanied by tinnitus from 1986 when he was 20 year old. He did not undergo further evaluation. After that, he reported facial twitching from 1991, and then gradual weakness in all limbs, difficulty in swallowing and speech, and episodes of choking over liquid feeding from 2001. His parents are non-consanguineous and healthy. His 3 sisters and one brother are also healthy. On examination there were bilateral fifth cranial nerve palsies. In addition, he had bilateral facial weakness associated with bilateral deafness. Atrophy and fasciculation were present in the tongue. Examination of the motor system revealed sternocleidomastoid, trapezius, and neck flexor weakness, compatible with a Medical Research Council (MRC) scale of 3/5. In the upper extremities, there was atrophy of the distal median and ulnar innervated muscles in both hands. Motor force was 4/5 in the deltoids and biceps. The strength of the first dorsal interosseous and abductor pollicis brevis was 4/5 on right, and 4/5 on left side. Distal atrophy and decreased motor force was more

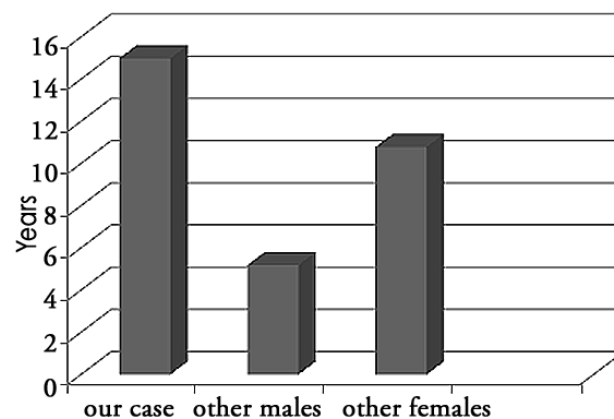
prominent in the distal lower limbs. The tibialis anterior (TA), extensor digitorum brevis, and intrinsic foot muscles were atrophied bilaterally. Muscle force was 3/5 in the extensor hallucis longus, TA, and gastrocnemius, and 4/5 in the femoral innervated muscles. Other abnormal findings were impaired position sensation, widespread brisk deep tendon reflexes, and bilateral upward plantar reflexes. The CSF pressure and analysis were normal. A brain MRI with contrast that was carried out before lumbar puncture was unremarkable with no abnormal signal or enhancement. We performed pure tone audiometry, which revealed bilateral low frequency sensorineural hearing loss. We then conducted an electrodiagnostic study. On motor nerve conduction study, distal latency, compound muscle action potential (CMAP) amplitude, and conduction velocity (CV) of the examined nerves (median, ulnar, tibial, and peroneal), were within normal limits. There was no conduction block or temporal dispersion. Peak latency and CV of the sensory nerves (median, ulnar and sural) were also normal. Electromyography (EMG) showed evidence of active denervation and reinnervation in the brainstem, cervical, and lumbar segments with prominent fasciculation in the tongue and fibrillation in the mentalis muscle. His condition worsened, and repeated EMG-NCV after 3 years showed reduction in CMAPs amplitude of the tibial and peroneal nerves. The thoracic paraspinal muscles were also involved in needle EMG. He became wheelchair bound from 2007. Gabapentin was of no benefit for his symptoms, and in 2008 he showed upward gaze palsy and deterioration in cranial and limb motor functions. He finally died one year after the last visit due to severe sepsis.

**Discussion.** Brown-Vialetto-Van Laere syndrome is a rare neurological disorder, considered a type of motor neuron disorder characterized by bilateral hearing loss as the most common presenting symptom, and accompanied by a variety of other cranial nerves dysfunction. The female to male ratio is approximately 3:1.<sup>4</sup> The age of onset varies, but is more common in the first and second decades. Disease duration varies from 0 (death at the presentation) to 45 years, and rapid deterioration has been attributed to male gender and disease onset at younger age.<sup>1</sup> Our case is a male with a long disease course (23 years). No male patient has been reported to have a course longer than 14 years. In addition, the onset of motor symptoms after hearing loss was 15 years later, at the age of 35. This is in sharp contrast with other male cases previously reported (Figure 1), which usually have shorter intervals than females (mean interval of 5.2 years in males versus 10.8 years

in females).<sup>3</sup> This emphasizes the clinical variability of BVVLS, which is not only in presenting symptoms, but also in duration until subsequent events. The fact should be considered that after an elongated period, hearing loss even in men, could lead to a life threatening neurological condition. Cases most commonly have been reported in the literature from Europe. We report a case of BVVLS from Iran. Previously, one male of 3 siblings was reported from Oman who had disease duration of one year.<sup>1</sup> Another male from Greece died 9 months after the first presentation.<sup>5</sup> Persian Caucasian ethnicity may play a role in long duration of disease in our reported patient.

Genetic tests for BVVLS were not available at the time of diagnosis, and the patient died before the gene was discovered. Sathasivam suggested an algorithm to approach a patient with sensorineural deafness and lower cranial nerve involvement.<sup>3</sup> If there were no signs of lower motor neuron (LMN) disorder in the limbs, the diagnosis is Boltshauser syndrome, but the clinical syndrome of LMN signs accompanied by cataract, cardiac conduction defect, and hypogonadism is compatible with Nathalie syndrome. The Madras type of motor neuron disorder (MMND) closely resembles BVVLS. The MMND is most confined to southern India, and in contrast to BVVLS has a benign clinical course.<sup>6</sup>

Four of the previously reported cases showed some improvement,<sup>7</sup> but the usual course reported in most cases is gradual deterioration followed by periods of stability or abrupt worsening. Our patient had a gradual deterioration course with no effect with Gabapentin. Although there was no trial or even report on the effectiveness of Gabapentin in BVVL, we tried a course of 900 mg per day for our patient because the drug has no serious adverse effects. More importantly experimental studies suggested a neuroprotective effect



**Figure 1** - Years between onset of hearing loss and other symptoms in Brown-Vialetto-Van Laere syndrome.

for Gabapentin by reduction in the rate of formation of glutamate derived from the branched-chain amino acids leucine, isoleucine, and valine and a randomized trial showed improvement in voluntary isometric contraction in spinal muscular atrophy type 2 or 3 following Gabapentin,<sup>8</sup> although that effect was not seen in other trials. We did not detect clinical nor electrophysiological improvement following its use. The commonly used drug in amyotrophic lateral sclerosis, Riluzole, has not been reportedly used in BVVLS.

While there is no proven effective treatment, the newly identified C20orf54 gene, located in 20p13,<sup>9</sup> and subsequently the riboflavin transporter defect,<sup>10</sup> may open a window for potential treatment options.

In conclusion, BVVLS shows large clinical variability. Male gender is associated with rapid deterioration, but long intervals between the onset of hearing loss and other symptoms are also possible.

## References

1. Koul R, Jain R, Chacko A, Alfutaisi A, Hashim J, Chacko J. Pontobulbar palsy and neurosensory deafness (Brown-Vialetto-van Laere syndrome) with hyperintense brainstem nuclei on magnetic resonance imaging: new finding in three siblings. *J Child Neurol* 2006; 21: 523-525.
2. Van Laere J. [On a new case of chronic bulbopontine paralysis with deafness]. *Verh K Vlaam Acad Geneesk Belg* 1967; 29: 288-308. Dutch.
3. Sathasivam S. Brown-Vialetto-Van Laere syndrome. *Orphanet J Rare Dis* 2008; 3: 9.
4. Descatha A, Goddet S, Aboab J, Allary J, Gergereau A, Baer M, et al. Cardiac arrest in a patient with Brown-Vialetto-Van Laere syndrome. *Amyotroph Lateral Scler* 2006; 7: 187-188.
5. Voudris KA, Skardoutsou A, Vagiakou A. Infantile progressive bulbar palsy with deafness. *Brain Dev* 2002; 24: 732-735.
6. Nalini A, Thennarasu K, Yamini BK, Shivashankar D, Krishna N. Madras motor neuron disease (MMND): clinical description and survival pattern of 116 patients from Southern India seen over 36 years (1971-2007). *J Neurol Sci* 2008; 269: 65-73.
7. De Grandis D, Passadore P, Chinaglia M, Brazzo F, Ravenni R, Cudia P. Clinical features and neurophysiological follow-up in a case of Brown-Vialetto-Van Laere syndrome. *Neuromusc Disord* 2005; 15: 565-568.
8. Merlini L, Solari A, Vita G, Bertini E, Minetti C, Mongini T, et al. Role of gabapentin in spinal muscular atrophy: results of a multicenter, randomized Italian study. *J Child Neurol* 2003; 18: 537-541.
9. Green P, Wiseman M, Crow YJ, Houlden H, Riphagen S, Lin JP, et al. Brown-Vialetto-Van Laere syndrome, a ponto-bulbar palsy with deafness, is caused by mutations in C20orf54. *Am J Hum Genet* 2010; 86: 485-489.
10. Bosch AM, Abeling NG, Ijlst L, Knoester H, van der Pol WL, Strooer AE, et al. Brown-Vialetto-Van Laere and Fazio Londe syndrome is associated with a riboflavin transporter defect mimicking mild MADD: a new inborn error of metabolism with potential treatment. *J Inherit Metab Dis* 2011; 34: 159-164.

### Related topics

Dbouk MB, Nafissi S, Ghorbani A. Chronic inflammatory demyelinating polyneuropathy following malignant melanoma. *Neurosciences* 2012; 17: 167-170.

Koc F, Yerdelen D. Motor neuron disease and its association with non-Hodgkins lymphoma. *Neurosciences* 2008; 13: 458-459.

Sengoz G, Yasar KK, Yildirim F, Nazlican O. Sensorineural hearing loss in neurobrucellosis. *Neurosciences* 2008; 13: 299-301.