

# Ramsay Hunt syndrome with multiple cranial neuropathies in a liver transplant recipient

Fawzi A. Babtain, MD, FRCPC, Harsha S. Bhatia, MD, Amer H. Assiri, MD, SBIM.

## ABSTRACT

تعد متلازمة رامزي هانت من الالتهابات التي تصيب الرأس والرقبة والتي يسببها الفيروس النطاقي الحماقي. وتشمل الإصابة أعصاب الوجه غير أن إصابة الأعصاب الدماغية الأخرى يعد نادراً. نستعرض في هذا المقال حالة مريض من مرضى المناعة الضعيفة كما أنه مصاب بمتلازمة رامزي هانت. وقد كان المريض يشكو من شلل عصبي في الوجه وحوصلات الأذن في نفس الجانب، بالإضافة إلى اضطراب عصبي دماغي متعدد. لقد تطورت حالة المريض جذرياً بعد العلاج بالمضادات الفيروسية والستيرويد القشري. تدل مثل هذه الحالة على وجوب اعتبار الفيروس النطاقي الحماقي كمسبب للاضطراب العصبي الدماغي المتعدد وذلك لدى المرضى المصابين بالمناعة الضعيفة. كما أنها تشير إلى أنه يجب التعجيل بأخذ عقار أسيسلوفير عند الشك في وجود المرض أثناء التشخيص.

Ramsay Hunt syndrome is an infection of the head and neck caused by varicella zoster virus involving the facial nerve; less commonly, other cranial nerves might be involved. We report a case of Ramsay Hunt syndrome in an immune compromised patient, with classic facial nerve palsy and ipsilateral ear vesicles, which rapidly evolved to involve multiple cranial neuropathies, and improved dramatically with antiviral therapy and corticosteroids. Varicella zoster virus should be considered as a cause of multiple cranial neuropathies in an immune compromised patient, and abrupt treatment with acyclovir should be initiated once this diagnosis is suspected.

*Neurosciences 2012; Vol. 17 (3): 262-264*

From the Department of Internal Medicine (Babtain), College of Medicine, King Khalid University, and the Department of Neurology (Bhatia, Assiri), Aseer Central Hospital, Abha, Kingdom of Saudi Arabia.

Received 3rd January 2012. Accepted 30th May 2012.

Address correspondence and reprint request to: Dr. Fawzi A. Babtain, Department of Internal Medicine, College of Medicine, King Khalid University, PO Box 641, Abha 61421, Kingdom of Saudi Arabia. Tel. +966 (7) 2417578. Fax. +966 (7) 2418111. E-mail: Fawzi.babtain@yahoo.com

Ramsay Hunt syndrome (RHS) is a varicella zoster virus (VZV) infection of the head and neck that involves the facial nerves (cranial nerve [CN] VII), but other CNs might be involved, including CN VIII, IX, V, and VI.<sup>1</sup> This infection will lead to vesicle formation with ulceration of the external ear, and the anterior two-thirds of the tongue and soft palate ipsilaterally. Ramsay Hunt syndrome accompanied by multiple cranial neuropathies is rare, more severe, and usually intractable compared with RHS without such an involvement.<sup>2</sup> We report a case of RHS with multiple cranial neuropathies in an immune compromised patient that responded well to antivirals and steroids, with no residual deficit on further follow up. Our objective in presenting this particular case is to highlight consideration of VZV as a cause of multiple cranial neuropathies in an immune compromised patient.

**Case Report.** A 32-year-old male presented to the emergency room with a 3-day history of severe headache and difficulty in swallowing. The headache started gradually, but progressed abruptly, was occipital, radiating to both temporal regions, and was severe enough to interfere with his daily activities. The headache was also associated with odynophagia, but there was no history of fever or other constitutional symptoms. He had a history of liver transplant 10 years ago for cirrhotic liver, possibly related to an immune hepatitis of unknown etiology. However, limited data were available regarding his immune status before the liver transplantation, as he was followed up and evaluated at another hospital. He was on prednisolone (West-Ward Pharmaceutical, Eatontown, NJ, USA) 20 mg once daily, with one reported episode of elevated liver enzymes, which was claimed to be a mild rejection that was confirmed by a liver biopsy, but no co-infections,

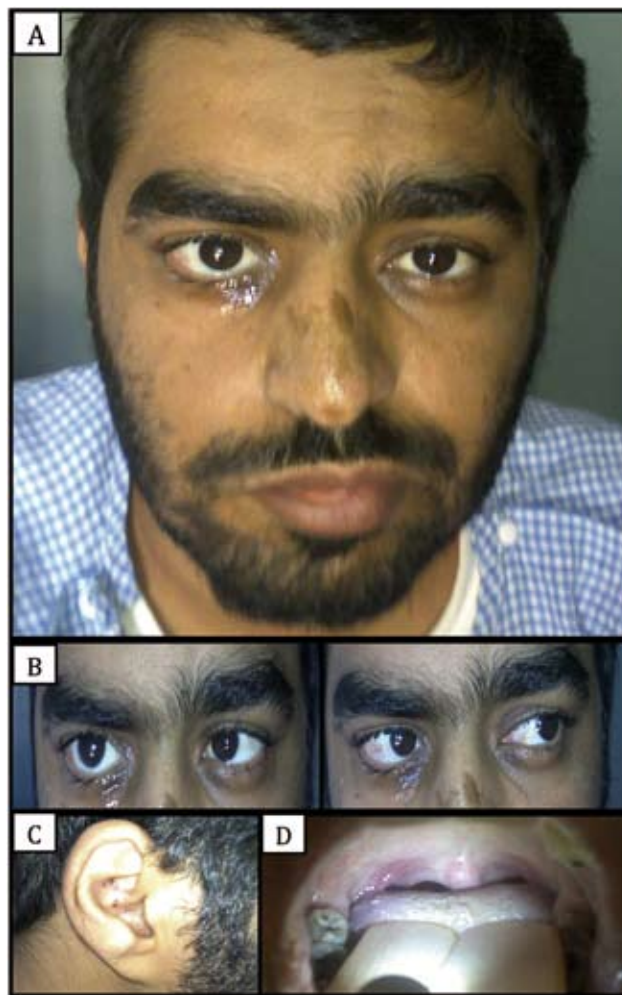
**Disclosure.** The authors declare no conflicting interests, support or funding from any drug company.

and no other opportunistic infections. He was also on Tacrolimus (Hikma Pharmaceuticals PLC, Amman, Jordan) one mg BID, and Cellcept (Roche, Milan, Italy) one gm BID. His initial examination revealed a fully awake patient, with no meningeal signs. There was a mild tenderness over the right sternomastoid muscle, but the rest of the examination, including the oropharyngeal exam and the nervous system were normal. He was admitted under the neurology service for a work up of a secondary headache in an immunosuppressed patient. The initial work up showed a normal CT of the brain, including the air sinuses. He was given analgesia, and MRI of the brain was ordered. The headache subsided, but he continued to have odynophagia. His examination then showed an oral thrush, and he was started on fluconazole (Tabuk Pharmaceutical Manufacturing Co., Tabuk, Saudi Arabia). On the fifth day of admission, he started to develop a maculopapular rash, and subsequently a vesicular rash over the external ear on the right. He was diagnosed with herpes zoster, and started on intravenous acyclovir (Hospira Australia, Melbourne, Australia) 10 mg/kg IV every 8 hours. On day 6 of admission, he developed horizontal double vision, worse towards the right. His examination showed right abducent nerve palsy and right lower motor neuron facial nerve palsy. The brain MRI showed filling of the right mastoid sinus, but otherwise normal. The next day, he was noted to have nasal speech, and had difficulties with swallowing. An examination then showed weak elevation of the soft palate on the right side, and absent gag reflex also on the right (Figure 1). However, there were no signs of pyramidal or cerebellar involvement. Due to the disseminated polycranial neuropathy, an assumption of herpes zoster as the primary etiology was made. The dose of prednisone was increased to 40 mg once daily, with a diagnosis of multiple cranial neuropathies secondary to herpes zoster virus. He was given 10 days of IV acyclovir. He started to improve gradually, and over 6 months follow up, he had no neurological deficit, and no history of facial pain. He continued with immune suppressants.

**Discussion.** Ramsay Hunt syndrome presenting with multiple cranial neuropathies is rare,<sup>2</sup> and full recovery following this unusual presentation is less likely to be observed. Varicella zoster virus infection is known to be associated with neurologic complications, with the trigeminal and facial nerves most commonly affected. This was first noted by Ramsay Hunt in the early 19th century, and simultaneous involvement of multiple cranial nerve ganglia (geniculate ganglion and peripheral ganglia of cranial nerves VIII, IX, and X) by

VZV, and its subsequent activation may result in the characteristic eruptions of herpes zoster cephalicus.<sup>3</sup> In 1915, a classification of zoster cephalicus was proposed by Sharp based on the inflammation of a particular cranial nerve involvement.<sup>3</sup>

Although the mechanism of polyneuropathy associated with RHS remains unclear, several possibilities can be considered. Hunt suggested that adjacent gasserian, petrous, accessory, jugular, plexiform, and second/third cervical dorsal root ganglia may form a chain allowing the extension of the ganglionitis. Other theories of cranial polyneuropathy propose that reactivation of the VZV may result from a direct perineural spread of the



**Figure 1** - Patient photograph showing: A) Loss of forehead wrinkles on the right side, with flattening of the right nasolabial fold, indicating a right lower motor neuron facial palsy. B) Examination of the horizontal gaze, with limited abduction of the right eye, indicating right abducent nerve palsy. C) External auditory canal of the right ear showing maculopapular vesicles. D) Weakness of the right soft palate.

virus along anastomotic pathways, or from a vasculitis in which the virus spreads through the small branches of the infected carotid artery, middle meningeal artery, and ascending pharyngeal artery that supply blood to cranial nerves V, VII, IX, X, XI, and XII.<sup>4,5</sup> It is known that the primary infection is usually acquired early in life and remains latent until it is reactivated later, where symptoms emerge, usually in association with an immune deficiency or suppression, such as, post-transplant treatment.<sup>6</sup>

Our case had gradual progressive involvement of lower cranial nerves VII, VI, VIII, IX, and X, associated with herpetic eruptions on the outer aspect of the ear, which was proven by positive polymerase chain reaction (PCR) for VZV. The PCR and the appropriate serologic assays (VZV IgM and IgA antibodies) on CSF, serum, and vesicular fluid may also detect VZV infection.<sup>7</sup> It was not until later in the admission that the patient started to show ear vesicles, and subsequently the right facial palsy, when the diagnosis of VZV infection was evidently clear, urging prompt appropriate therapy, although the patient subsequently developed multiple cranial involvement related to the same infection. It was probably the patient's immune status that led to the rapid and diffuse cranial nerve involvement, although this was unpredictable, his excellent recovery was mostly because of the early diagnosis and treatment of the infection. Our patient had a normal MRI exam, but in view of the vesicular skin rash and positive PCR for VZV, he was diagnosed to have herpes zoster. The inflammatory involvement of the cranial nerves on neuroimaging was demonstrated by the enhancement of the cranial nerve V, VII, VIII, and XII in the contrast-enhanced MRI.<sup>8</sup> Immunosuppressed patients, in particular, are known to be more vulnerable to zoster virus infections. Therefore, comprehensive clinical, laboratory, and radiological evaluations are warranted in such cases to secure the diagnosis, and also to exclude other potential etiologies in these patients.<sup>8</sup>

The benefit of early recognition of RHS is that early commencement of antiviral treatment significantly improves the prognosis.<sup>9</sup> The time gap between the onset of acyclovir therapy and attack of zoster oticus is the most relevant prognostic factor in recovery of these patients. Ramsay Hunt syndrome associated with cranial polyneuropathy needs a more active and aggressive management than the treatment of RHS without cranial polyneuropathy. Antiviral agents should be included in the treatment modality, and the combination therapy of

60 mg of prednisolone (or 48 mg of methylprednisolone) for 2 weeks and 1500-1800 mg of acyclovir for one week seems to be sufficient for the successful treatment of most patients.<sup>10</sup> Our case was started on acyclovir and steroids as early as the appearance of rash, and he gradually showed improvement with full recovery over 6 months. A combination therapy of antiviral agents and steroids in cases with polycranial neuropathies was reported to have a better prognosis with the exception of hearing loss.<sup>10</sup>

In conclusion, a diagnosis of RHS should be considered in patients with unilateral multiple cranial nerve palsies, and early antiviral and steroid treatment significantly improves the prognosis. The increasing number of post organ transplant patients affected by RHS, particularly with multiple cranial neuropathies, should be well recognized and promptly treated. However, the role of prophylactic anti-virals in these cases to prevent cranial neuropathies is still unknown, and requires further evaluation in future studies.

## References

1. Louis ED. James Ramsay Hunt (1874-1937). *J Neurol* 2004; 251: 240-241.
2. Shim HJ, Jung H, Park DC, Lee JH, Yeo SG. Ramsay Hunt syndrome with multicranial nerve involvement. *Acta Otolaryngol* 2011; 131: 210-215.
3. Sweeney CJ, Gilden DH. Ramsay Hunt syndrome. *J Neurol Neurosurg Psychiatry* 2001; 71: 149-154.
4. Espay AJ, Bull RL. Petrositis in Ramsay Hunt syndrome with multiple cranial neuropathies. *Arch Neurol* 2005; 62: 1774-1775.
5. Nishioka K, Fujishima K, Kobayashi H, Mizuno Y, Okuma Y. An extremely unusual presentation of varicella zoster viral infection of cranial nerves mimicking Garcin syndrome. *Clin Neurol Neurosurg* 2006; 108: 772-774.
6. Ozel L, Toros SZ, Unal E, Kara M, Eren PA, Canbakan M, et al. Ramsay Hunt syndrome with atypical progress in a renal transplant recipient: a case report. *Exp Clin Transplant* 2011; 9: 413-416.
7. Gross G, Schöfer H, Wassilew S, Friese K, Timm A, Guthoff R, et al. Herpes zoster guideline of the German Dermatology Society (DDG). *J Clin Virol* 2003; 26: 277-289.
8. Morelli N, Mancuso M, Cafforio G, Gallerini S, Pittiglio L, Tonelli S, et al. Ramsay Hunt syndrome complicated by unilateral multiple cranial nerve palsies. *NeuroSci* 2008; 29: 497-498.
9. Gilden D, Nagel MA, Mahalingam R, Mueller NH, Brazeau EA, Pugazhenti S, et al. Clinical and molecular aspects of varicella zoster virus infection. *Future Neurol* 2009; 4: 103-117.
10. Kim YH, Chang MY, Jung HH, Park YS, Lee SH, Lee JH, et al. Prognosis of Ramsay Hunt Syndrome Presenting as cranial polyneuropathy. *Laryngoscope* 2010; 120: 2270-2276.