

Remote cerebellar hemorrhage in neurosurgery

Saleh S. Baeesa, MBChB, FRCS.

ABSTRACT

يعتبر النزف المخيخي النائي من المضاعفات النادرة بعد عمليات الجراحة العصبية، وما زالت آليته وتطوره السريري أمراً مبهماً وغير واضح المعالم. وإن العمليات الجراحية العصبية التي قد يحدث بعدها هذا النزف ليست محصورة في نوع معين بل متنوعة، وتشمل العمليات فوق الخيمة المخية، وكذلك عمليات الحبل الشوكي، وبخاصة تلك العمليات التي يجري فيها استئصال واسع للآفة، أو يحدث فيها تسرب كبير للسائل الدماغي الشوكي. هذا وإن عوامل الخطورة التي بينتها الدراسات ما زالت غير كافية للتنبؤ بالمرضى المعرضين أكثر من غيرهم لحدوث هذا النزف، وبذلك يبقى النزف المخيخي النائي من المضاعفات الجراحية الغير متوقّعه والتي تتطلب فهماً أفضل للفيزيولوجيا المرضية التي تخصّه. ولقد قمنا في هذا المقال بمراجعة واسعة للدراسات المتاحة لاستيعاب ما عُرف عن هذا النزف، ولبيان ما انتهت إليه هذه الدراسات، وكذلك لبيان ما تحتاجه الدراسات المستقبلية بغية الوصول إلى فهم أفضل لهذا المرض.

Remote cerebellar hemorrhage (RCH) is a rare complication in neurosurgery that remains enigmatic both in underlying mechanism and clinical behavior. The range of procedures associated with RCH is diverse and includes both supratentorial and spinal procedures that entail significant CSF loss or lesion resection. The risk factors identified in the literature are not sufficient in predicting the patients at risk of developing RCH. It thereby remains an unpredictable hazard that requires better understanding of its pathophysiology. This study is a comprehensive review of the available literature to provide an understanding of where it stands so far, and to explain an observation in the literature that may have implications for better understanding the disease. Areas of future research are also identified.

Neurosciences 2012; Vol. 17 (4): 305-308

From the Division of Neurosurgery, Department of Surgery, Faculty of Medicine, King Abdulaziz University, Jeddah, Kingdom of Saudi Arabia.

Address correspondence and reprint request to: Dr. Saleh S. Baeesa, Division of Neurosurgery, King Abdulaziz University Hospital, PO Box 80215, Jeddah 21589, Kingdom of Saudi Arabia. Fax. +966 (2) 6408469. E-mail: sbaeesa@kau.edu.sa

Cerebellar hemorrhage remote from the operative field, referred to as remote cerebellar hemorrhage (RCH), is a complication rarely encountered in neurosurgery with a reported incidence of 0.08-0.6% post supratentorial craniotomies.^{1,2} Since it was first described by Yasargil et al in 1977,³ this complication has intrigued the neurosurgical community, with more than 164 cases documented after supratentorial surgeries to date, not counting those occurring after spinal procedures.^{1,4} Our understanding of the pathophysiology and risk factors of this complication is as limited as this phenomenon is rare.¹ This is a source of concern, as without a complete understanding of this phenomenon we can neither accurately identify those at risk, nor follow the optimum line of management. This study reviews the literature, and presents what is known regarding the clinical and radiologic features and prognosis of this rarely encountered complication. It also attempts to explain an observed discrepancy in outcome between RCH occurring from supratentorial and spinal procedures, adding more insight to the pathophysiology, and opening new fields of research.

The spectrum of implicated procedures. Remote cerebellar hemorrhage is a poorly understood consequence of neurosurgical procedures resulting in significant CSF hypovolemia, reported to occur after supratentorial procedures,⁵ trans-sphenoidal surgeries,⁶ and spine surgeries at the cervical, lumbar, and thoracic levels.^{4,7,8} There have been a few documented cases after burr hole evacuations of subdural hematomas with significant CSF egress,⁹ and uncontrolled lumbar punctures.¹⁰ The overall frequency mentioned in the literature ranges from 0.08-0.6% of all supratentorial craniotomies, and are even less common following spine surgery.^{1,2} Specific procedures requiring significant CSF drainage as part of the procedure show a higher incidence of RCH, with series reporting numbers of 3.9% following aneurysm surgeries, and 5% following temporal lobectomies.^{11,12}

Disclosure. The author declares no conflicting interests, support or funding from any drug company.

Pathophysiology: a source of ongoing debate. Despite the controversy surrounding this phenomenon, some aspects appear to be agreed upon in the reviewed literature.^{1,2} It is believed to be of venous origin; this conclusion was reached after observing that RCH is commonly bilateral.² It also has a predilection for the superior cerebellar surface and vermis (territory drained by the superior vermian veins), this does not follow the behavior of typical arterial bleeds seen in the cerebellum of the hypertensive patient. Cloft et al,¹¹ also showed that the mechanism that would label RCH as an arterial event, namely, a hemorrhagic transformation of a cerebellar infarct, resulting from the clamping and unclamping of the superior cerebellar arteries in aneurysm surgeries, does not explain the inconsistent presence of cerebellar infarction with RCH. Further support would come from histopathologic studies of surgically decompressed RCH cases consistent with venous infarction.¹³ The other aspects agreed upon are the need for CSF drainage (either intraoperatively or post operatively, the latter being more strongly associated), and that the RCH is typically subarachnoid, with a variable intraparenchymal element whose size corresponds to the associated morbidity and mortality.²

The pathophysiologic theories presented are numerous. They do, however, all have the common endpoint of increasing the pressure gradient across the walls of the infratentorial vessels. This can occur by one of 2 mechanisms; it may occur secondary to an increase in the intraluminal venous pressure by interrupting the outflow through the stretched internal jugular vein, as demonstrated to result from the intraoperative positioning typical of pterional craniotomies as proposed by Seoane and Rhoton¹⁴ (extensive rotation and extension), or as Yoshida et al¹⁵ suggested by stretching and kinking, or even shearing, of the superior vermian veins by the caudal migration of the cerebellum as a result of CSF hypovolemia, the “cerebellar sag.” Another mechanism provided by Konig et al,¹⁶ is by decreasing the CSF pressure in the surrounding subarachnoid spaces with a reciprocal relative rise in pressure; other studies support this mechanism.¹⁷ Honneger et al,⁵ later proposed that the hemorrhage is a result of the suctioning effect exerted by the transtentorial gradient on the cerebellum.

It is our belief that out of all the mentioned theories, the one that can explain the occurrence of RCH after both supratentorial and spinal procedures is the “cerebellar sag” hypothesis described in 1990 by Yoshida et al,¹⁵ and which is later echoed by Friedman et al in several reports.^{4,8,13} This theory also explains the propensity of RCH to occur after procedures requiring massive CSF drainage.^{11,12}

The literature seems to have reached a similar conclusion, at least regarding the need for substantial CSF drainage to occur, with its reference to the “zebra pattern” as characteristic of CSF over drainage.¹⁸ This, however, has recently come under increasing scrutiny, as the result of the “cerebellar sag” theory is kinking of the vermian veins. However, RCH is not uncommon after infratentorial surgeries involving the intentional occlusion of the supracerebellar veins.³ Other flaws in this theory include the conspicuous absence of cerebellar edema expected by venous obstruction. The fact that the distribution is not confined to the territory of a single vein,² and most recently, the theory’s failure to explain the occurrence of RCH after controlled CSF drainage, with episodes reported after lumbar puncture¹⁰ and one very recently occurring post operatively secondary to lumboperitoneal shunting,⁶ are additional weaknesses in this theory.

This theory alone cannot explain why RCH secondary to spinal procedures is more likely to result in persistent deficits than RCH following supratentorial craniotomies.² We believe that is because “spinal” RCH has 2 forces synergizing, the “cerebellar sag,” and a pressure gradient favoring downward cerebellar migration. While in the case of “cranial” RCH, they counteract, and the result is weaker. Recently, there was an interesting report linking intracranial hypotension to venous thrombosis; a mechanism not previously suggested as a cause of venous obstruction underlying RCH. We do acknowledge that this would imply that antithrombotic agents would be protective, not a risk factor as has been observed, but it may still have a role in impeding the venous outflow and thereby increasing venous pressure.^{8,16}

Proposed risk factors. With the widespread use of routine post-operative computed tomography (CT) scanning and the large number of implicated procedures performed daily, the occurrence of RCH may be much more common than believed. However, the vast majority are either passing undetected clinically or radiologically, and there are other factors, either perioperative or intrinsic to the patient that act to convert this ubiquitous hemorrhage from undetectable to detectable. Perioperative factors and patient traits presented in the literature to identify those at higher risk of developing RCH are numerous. They include: the intraoperative and, more likely, post-operative CSF loss, especially if negative pressure drains were used,¹⁸ perioperative hypertension,¹⁶ coagulopathies¹⁶ (both congenital and acquired), and platelet dysfunction⁸ (including perioperative aspirin administration); other factors implicated include dehydration¹⁹ (iatrogenic

intraoperatively or unintended) with its unfavorable effect on venous hemodynamics. It is believed to more likely occur in males, and has been observed in patients as young as 14 years of age.^{1,20}

Clinical presentation. Despite being asymptomatic in almost one quarter of reported cases, these bleeds may manifest with altered levels of consciousness, and headache, cerebellar signs, delayed awakening from anesthesia, and seizures have all been reported.^{1,13}

Radiologic features. The “zebra sign” is used to describe the CT characteristic appearance of the subarachnoid component of this entity. The alternating hyperdensity of the acute bleed, and the relative hypodensity of the upper cerebellar folia combine to form this characteristic pattern (Figure 1). Extension to adjacent structures or significant edema is rarely seen, but may occur in the territories of the draining superior vermian veins.¹⁸ What is also worth noting is the presence of a variable intraparenchymal component.

Although it is widely accepted that non-contrasted CT scan is considered the imaging modality of choice for intracranial hemorrhage, there are, however, reports of CT scans and negative bleeds discovered on MRI, which we believe could be yet another reason for underreporting.²⁰ But with 23.4% of hemorrhages in the literature being asymptomatic,¹ with CT scan as the prevailing modality, we believe that it would be very unlikely that a clinically significant lesion is missed. The use of MRI, however, may result in a rise of reported cases, albeit by detecting insignificant bleeds.

Management strategy. The management of RCH, a poorly understood and rarely encountered entity, is not well described in the literature. It may be inferred from the reported cases and series that the same principles of

spontaneous cerebellar hemorrhage management apply. If no mass effect were noted, then a conservative line of management can be followed with good outcomes expected. If, however, hydrocephalus or brain stem compression were to be present, then CSF diversion, and direct evacuation of the clot should be considered as needed.¹³ The one aspect of management that deserves special attention, because of its unique pathogenesis, is the need to assess for either CSF overdrainage in the inserted drains or the possible presence of an occult CSF leak.¹² Some have called for correcting the CSF hypovolemia by infusing isotonic crystalloids, but this has not been widely accepted by the neurosurgical community, and may even be deleterious in a hydrocephalic patient.⁶ It should be noted that the need for intervention is a marker for poor outcome, as is increasing age and hemorrhage severity.²

The management of hydrocephalus in a deteriorating patient with an expanding cerebellar hematoma would pose a dilemma. On one hand, the patient is hydrocephalic and needs CSF diversion. On the other hand, its presence risks losing the tamponading effect of CSF, with its drainage allowing the hematoma to rapidly grow. This has been reported in a patient with a VP shunt who rapidly deteriorated following head trauma; the CT scan showed an epidural hematoma that rapidly grew to huge proportions.²¹

Prognosis. The literature paints a grim picture for this entity’s clinical behavior, with the overall morbidity rate reported around 8.4%, and a reported mortality rate estimated at 7.8%.¹² An RCH associated with spinal procedures is more likely to result in permanent deficits,² but does not otherwise differ from that associated with cranial procedures in a statistically significant manner.

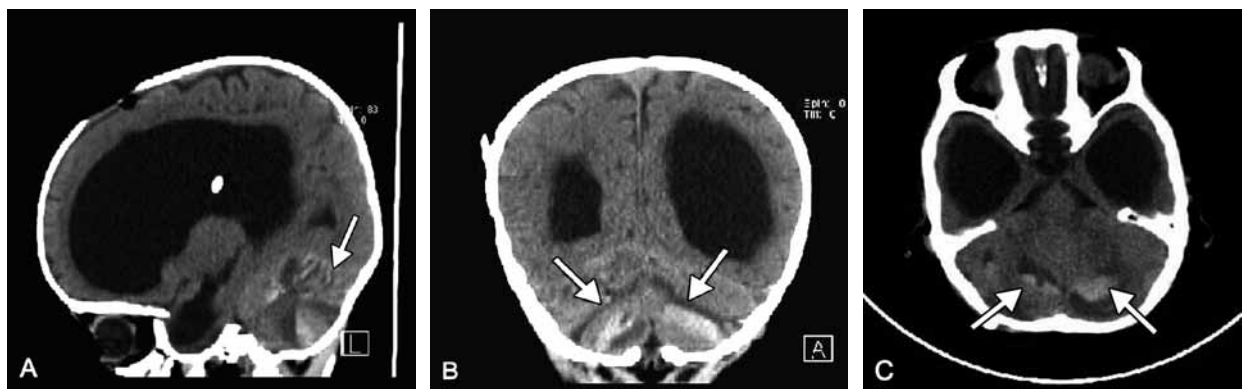


Figure 1 - The CT scans of a 4-month-old boy in A) sagittal, B) coronal, and C) axial views showing development of a remote cerebellar hemorrhage one day following insertion of a ventriculoperitoneal shunt. Note the demonstration of the classically described Zebra sign.

Outcome was only affected by patient age and severity of hemorrhage, with both having a negative impact on outcome.

In conclusion, RCH is a poorly understood disease whose pathophysiology and management is still a matter of controversy. We believe that there are in fact, several subtypes, as evidenced by the varying morbidity observed between those caused by supratentorial and spinal procedures. Each of these subtypes is with their own underlying mechanisms, which along with certain patient and procedure-related factors converge to disrupt the infratentorial venous bed. Further research is needed to better describe its clinical behavior as well as to identify those patients at risk of developing RCH. Should we be able to label them as such, we may offer a personalized line of management that prevents and proactively attempts to detect it in the pre clinical stage.

References

1. Park JS, Hwang JH, Park J, Hamm IS, Park YM. Remote cerebellar hemorrhage complicated after supratentorial surgery: retrospective study with review of articles. *J Korean Neurosurg Soc* 2009; 46: 136-143.
2. Brockmann MA, Groden C. Remote cerebellar hemorrhage: a review. *Cerebellum* 2006; 5: 64-68. Review.
3. Yasargil MG, Yonekawa Y. Results of microsurgical extra-intracranial arterial bypass in the treatment of cerebral ischemia. *Neurosurgery* 1977; 1: 22-24.
4. Friedman JA, Ecker RD, Piepgras DG, Duke DA. Cerebellar hemorrhage after spinal surgery: report of two cases and literature review. *Neurosurgery* 2002; 50: 1361-1363. Review.
5. Honegger J, Zentner J, Spreer J, Carmona H, Schulze-Bonhage A. Cerebellar hemorrhage arising postoperatively as a complication of supratentorial surgery: a retrospective study. *J Neurosurg* 2002; 96: 248-254.
6. Sasani M, Sasani H, Ozer AF. Bilateral late remote cerebellar hemorrhage as a complication of a lumbo-peritoneal shunt applied after spinal arteriovenous malformation surgery. *J Spinal Cord Med* 2010; 33: 77-79.
7. Chaddock WM. Cerebellar hemorrhage complicating cervical laminectomy. *Neurosurgery* 1981; 9: 185-189.
8. Friedman JA, Piepgras DG. Remote hemorrhage. *J Neurosurg* 2001; 95 (2 Suppl): 279-280.
9. Vogels RL, Verstegen MJ, van Furth WR. Cerebellar haemorrhage after non-traumatic evacuation of supratentorial chronic subdural haematoma: report of two cases. *Acta Neurochir (Wien)* 2006; 148: 993-996.
10. Bernal-García LM, Cabezedo-Artero JM, Ortega-Martínez M, Fernández-Portales I, Ugarriza-Echebarrieta LF, Pineda-Palomo M, et al. [Remote cerebellar hemorrhage after lumbar spinal fluid drainage. Report of two cases and literature review]. *Neurocirugía (Astur)* 2008; 19: 440-445. Review. Spanish.
11. Cloft HJ, Matsumoto JA, Lanzino G, Cail WS. Posterior fossa hemorrhage after supratentorial surgery. *AJNR Am J Neuroradiol* 1997; 18: 1573-1580.
12. Toczek MT, Morrell MJ, Silverberg GA, Lowe GM. Cerebellar hemorrhage complicating temporal lobectomy. Report of four cases. *J Neurosurg* 1996; 85: 718-722.
13. Friedman JA, Piepgras DG, Duke DA, McClelland RL, Bechtel PS, Maher CO, et al. Remote cerebellar hemorrhage after supratentorial surgery. *Neurosurgery* 2001; 49: 1327-1340.
14. Seoane E, Rhoton AL Jr. Compression of the internal jugular vein by the transverse process of the atlas as the cause of cerebellar hemorrhage after supratentorial craniotomy. *Surg Neurol* 1999; 51: 500-505.
15. Yoshida S, Yonekawa Y, Yamashita K, Ihara I, Morooka Y. Cerebellar hemorrhage after supratentorial craniotomy--report of three cases. *Neurol Med Chir (Tokyo)* 1990; 30: 738-743.
16. König A, Laas R, Herrmann HD. Cerebellar haemorrhage as a complication after supratentorial craniotomy. *Acta Neurochir (Wien)* 1987; 88: 104-108.
17. Canhão P, Batista P, Falcão F. Lumbar puncture and dural sinus thrombosis--a causal or casual association? *Cerebrovasc Dis* 2005; 19: 53-56.
18. Brockmann MA, Nowak G, Reusche E, Russlies M, Petersen D. Zebra sign: cerebellar bleeding pattern characteristic of cerebrospinal fluid loss. Case report. *J Neurosurg* 2005; 102: 1159-1162.
19. Sasani M, Ozer AF, Oktenoglu T, Karaarslan E, Sasani H, Kaner T. Remote cerebellar hemorrhage following resection of a supratentorial tumor: a case report. *Cases J* 2009; 2: 7299.
20. Marquardt G, Setzer M, Schick U, Seifert V. Cerebellar hemorrhage after supratentorial craniotomy. *Surg Neurol* 2002; 57: 241-251.
21. Bor Seng Shu E, de Almeida Leme RJ, Aguiar PH, de Andrade AF, Teixeira MJ, Plese JP. Traumatic acute giant epidural hematoma in a hydrocephalic shunted child. *Pediatr Neurosurg* 2000; 32: 176-179.