

Acute visual loss in an orbital arteriovenous malformation

Yin Niu, MD, Hongping Miao, MD, Gang Zhu, MD, PhD, Zhi Chen, MD.

ABSTRACT

أن تشوه الشريان الوريدي للحجاج بعد نادراً وخلق السبب . يمكن أن يزداد بشكل بطيء ومتأخر بعد فترة طويلة هادئة إن كان هنالك توازن للدورة الدموية بين الأوعية الداخلة والخارجة . لكن، عند انحلال التوازن قد يسبب تشوه الشريان الوريدي تدهور ملحوظ . نسلط في هذا التقرير الضوء على حالة مريض ذكر يبلغ من العمر 17 عاماً مصاب بتشوه الشريان الوريدي ومناقشة آليته وطرق السيطرة على التدهور البصري الحاد في هذا المكان . أظهر تصوير الأوعية الدموية احتقان مداري مع انسداد المجاري وانصمام مداري قوي وذلك لخلل التوازن . لم يظهر لدى المريض أي تطور بالرغم من نجاح العلاج بانصمام جذري . يسبب انسداد المجاري إلى تدفق الانسياب الدموي الذي يؤدي إلى تدهور حاد . أن التشخيص الدقيق والمبكر والخضوع لعلاج انصمام عبر الشريان يعد مهماً قبل ظهور الخلل الدموي .

Arteriovenous malformations (AVMs) of the orbit are rare and are thought to be congenital. They can grow slowly or in a delayed fashion after a prolonged period of quiescence if there is a hemodynamic balance between the in-flow and the out-flow vessels. However, once the balance is destroyed, orbital AVMs may cause acute visual deterioration. We report a 17-year-old male with orbital AVM, and discuss the mechanism and the management of acute visual deterioration in this setting. Angiography revealed an orbital AVM with obvious drainage obstruction and serious orbital congestion, due to the disruption of the balance. He had no vision improvement although treated successfully with radical transarterial embolization. The worsening of drainage obstruction could alter the hemodynamic flow and lead to acute visual deterioration. Early and exact diagnosis and complete transarterial embolization therapy are important before the hemodynamic imbalance.

Neurosciences 2013; Vol. 18 (3): 273-275

From the Department of Neurosurgery, Southwest Hospital, Third Military Medical University, Chongqing, China.

Received 22nd January 2013. Accepted 7th April 2013.

Address correspondence and reprint request to: Dr. Zhi Chen, Professor, Department of Neurosurgery, Southwest Hospital, Third Military Medical University, Gaotanyan Street, Shapingba District, Chongqing 400038, China. Tel. +86 (23) 68765259. Fax. +86 (23) 65463954. E-mail: southwestpcz@163.com

Hemodynamically, arteriovenous malformations (AVMs) are connected to in-flow and out-flow vessels of the normal vascular system. Arteriovenous malformations of the orbit commonly present proptosis, followed by chemosis, and periocular pain.¹ Acute visual loss of the orbital AVMs is rare, with only one case reported in 1993.² We present a unique patient with acute visual deterioration due to venous congestion without obvious drainage, in which early and exact identification of the hemodynamic imbalance may be necessary to avoid irreversible visual impairment.

Case Report. A 17-year-old man was referred to our office with a 3-year history of pulsating proptosis with pain, and 10 days of rapid visual loss. There was no history of orbital trauma or family history of vascular disorders. Ten days before presentation to our hospital he had 4 mm of nonaxial proptosis of the right eye without visual loss. Following this, his vision became blurred upon awakening and continued to worsen throughout the day. After treatment for infectious conjunctivitis in a local clinic, he still had impaired vision. On admission, physical examination demonstrated proptosis, restricted extraocular movements in all directions, and complete loss of vision in the right eye. No bruits were audible over the right orbit. Intraocular pressure was normal (right eye, 13.8 mm Hg; left eye, 13.7 mm Hg, by Goldmann applanation tonometer, GAT). The visual

Disclosure. The authors declare no conflicting interests, support or funding from any drug company.

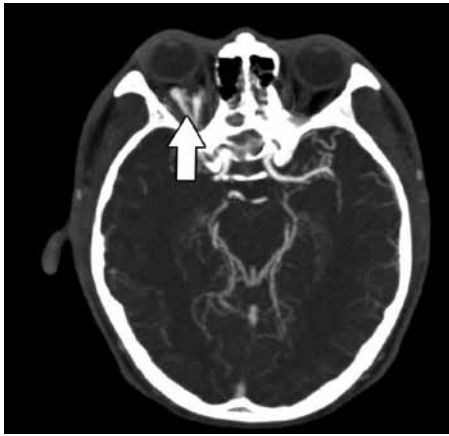


Figure 1 - Computed tomographic angiography scan showing vascular lesion in the retrobulbar fat without hemorrhage consistent with an orbital arteriovenous malformation (arrow).

evoked potential (VEP) examination showed the P100 wave absent in the right eye. A computed tomographic angiography scan revealed AVM in the retrobulbar fat without obvious hemorrhage (Figure 1). Angiography revealed a right-sided orbital AVM fed by the right ophthalmic artery, and out-flow venous obstruction

without retrograde drainage through the superior ophthalmic vein, inferior ophthalmic vein, or facial vein. There was severe congestion with slow flow around the orbital area (Figures 2A & 2B). For endovascular treatment, a 6F Launcher catheter was placed in the right internal carotid artery. A microcatheter was superselectively navigated into the proper feeders arising from the distal ophthalmic artery. Superselective angiogram showed the anterior part of the AVM with flow controlled in the feeder (Figure 3A). Twenty percent Glubran (GEM, Viareggio, Italy) was injected from the microcatheter wedged into the feeders for embolization. Angiography immediately after the procedure showed complete occlusion of the AVM (Figure 3B). After the operation, his proptosis and chemosis resolved rapidly without vision improvement. The VEP still showed the P100 wave absent in the right eye. After 3 months follow-up, the vision had no obvious improvement, the intraocular pressure was normal, there was no proptosis, and no conjunctival chemosis.

Discussion. Orbital AVMs are considered to be congenital and derived embryologically from the arterial system, the venous system, or both. Based on

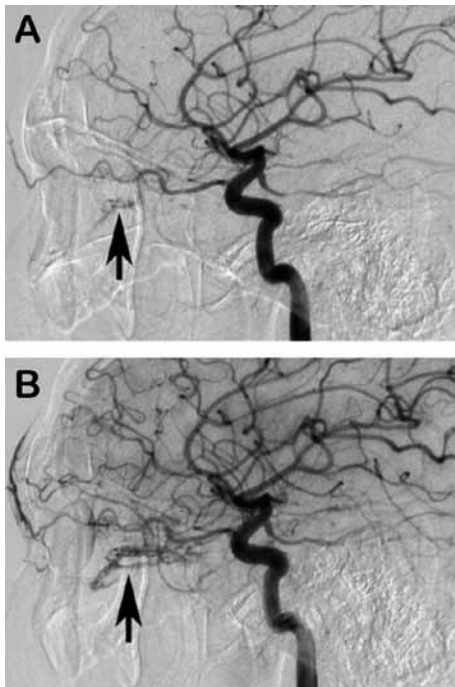


Figure 2 - Right internal carotid artery (ICA) angiograms showing: A) lateral view of the arterial phase demonstrating an orbital arteriovenous malformation (AVM) (arrow), the main supply to this AVM is from the right ophthalmic artery via a branch. B) Capillary phase of the right ICA angiogram showing obvious slowing of the out-flow venous of orbital AVM (arrow).

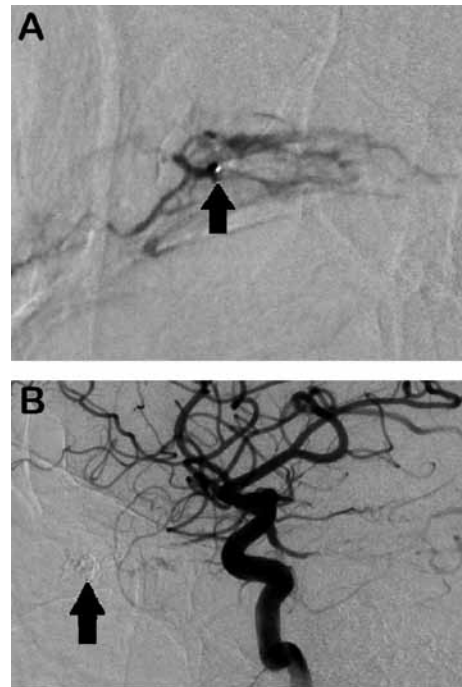


Figure 3 - Angiograms showing A) lateral view, obtained after a microcatheter (arrow) was advanced into the proper feeder and selective injections were performed. B) Right internal carotid artery angiogram showing complete occlusion of the arteriovenous malformation (arrow).

location, they may be classified into 3 types: purely orbital, orbital and periorbital, and orbital with retinal or cerebral AVMs. The purely orbital AVMs are more common (26 of 36 reviewed cases [72%] by Warriar et al³). Orbital AVMs are lesions of the vasculature that develop blood flow directly from the arterial system (in-flow) to the venous system (out-flow) without passing through a capillary system. The most common presenting feature is proptosis, followed by chemosis, and periocular pain without sudden visual deterioration if there is a hemodynamic balance between the in-flow and the out-flow vessels. Acute visual loss with orbital AVMs has rarely been reported. Chakraborty et al² reported one case that presented with rapid visual loss in 1993, and considered the causes of the rapid visual deterioration to be compression of the optic nerve and massive AVM invasion of the optic nerve. Thus far, the mechanism of visual deterioration of orbital AVMs was commonly thought to be optic nerve or retinal ischemia, increased intraocular pressure, shunting of arterial blood, or mass effect.⁴

In the present case, angiography revealed obstruction of the venous out-flow of the orbital AVM without obvious drainage through the superior ophthalmic vein, inferior ophthalmic vein, or facial vein, and severe congestion with slow flow around the orbital area. The patient presented with the same symptoms as previous cases of orbital AVMs,⁵⁻⁷ including progressive pulsating proptosis and pain because of the free drainage before visual loss. Accordingly, we speculated that the hemodynamic balance between the in-flow and the out-flow vessels was maintained before visual loss with the free drainage. Additionally, acute visual deterioration of the orbital AVM may be caused by the disruption of the hemodynamic balance and serious orbital congestion, which was not only due to the worsening of drainage obstruction, but also due to the high-pressured orbital venous reflux.⁸

Diagnosis of orbital AVMs is based on angiographic findings highlighting the in-flow arteries, a malformation, and the out-flow vessels. The observations of this case suggest that the state of hemodynamic balance between the in-flow and the out-flow vessels should be identified early and imminently in AVMs of the orbit. The diagnosis can be assisted by clinical history and noninvasive tests, such as computed tomographic angiography, Doppler studies, and MRI to highlight the hemodynamics of the lesions.

The most common approach involves preoperative angiography followed by surgical resection with or

without embolization. Laser therapy, percutaneous embolization, and radiation therapy are also potentially viable treatment options.⁹ Recently, with the rapid advancement of endovascular techniques, Sato et al⁷ reported an orbital AVM successfully treated by radical transarterial embolization, and reported that transarterial embolization can be considered as one of the radical treatments for orbital AVMs. In our case, the malformation was also radically extirpated via transarterial embolization. Unfortunately, only the symptoms of proptosis and chemosis resolved rapidly, despite attempts to save his vision after successful treatment by radical transarterial embolization with glue.

In conclusion, this case suggests that worsening of the drainage obstruction could alter the hemodynamic flow and lead to acute visual deterioration of orbital AVMs. Early and exact identification of the hemodynamics of AVMs, with drastic removal via transarterial embolization before the hemodynamic balance is disrupted is necessary, or visual improvement may be impossible.

References

1. Ho TY, Wang AG, Lin MC, Yen MY. Orbital arteriovenous malformation. *Jpn J Ophthalmol* 2010; 54: 636-637.
2. Chakraborty S, Nagashima T, Izawa I, Sekiya Y, Sugiura T, Inoue M, et al. Intraorbital arteriovenous malformation: case report. *Surg Neurol* 1993; 40: 320-325.
3. Warriar S, Prabhakaran VC, Valenzuela A, Sullivan TJ, Davis G, Selva D. Orbital arteriovenous malformations. *Arch Ophthalmol* 2008; 126: 1669-1675.
4. Trombly R, Sandberg DI, Wolfe SA, Ragheb J. High-flow orbital arteriovenous malformation in a child: current management and options. *J Craniofac Surg* 2006; 17: 779-782.
5. Huna-Baron R, Setton A, Kupersmith MJ, Berenstein A. Orbital arteriovenous malformation mimicking cavernous sinus dural arteriovenous malformation. *Br J Ophthalmol* 2000; 84: 771-774.
6. Kaufman Y, Cole P, Dauser R, Hollier L Jr. Intraorbital arteriovenous malformation: issues in surgical management. *J Craniofac Surg* 2007; 18: 1091-1093.
7. Sato K, Matsumoto Y, Kondo R, Tominaga T. Intraorbital arteriovenous malformation treated by transarterial embolization: technical case report. *Neurosurgery* 2011; 68: 383-387.
8. Chen Z, Zhu G, Feng H, Liu Z. Worsening of cavernous sinus dural arteriovenous fistula with incomplete superior ophthalmic thrombosis after palliative transarterial embolization. *Neurology India* 2007; 55: 390-392.
9. Goldberg RA, Garcia GH, Duckwiler GR. Combination embolization and surgical treatment of arteriovenous malformation of the orbit. *Am J Ophthalmol* 1993; 116: 17-25.