

Crossed cerebro-cerebellar atrophy with Dyke Davidoff Masson syndrome

Hussein A. Algabtni, MD, FRCPC, Ahmed A. Aldarmahi, M.Med Sci, PhD, Mohammed W. Al-Rabia, MD, PhD, G. Bryan Young, MD, FRCPC.

ABSTRACT

أن متلازمة دايك دافيدوف ماسون (DDMS) هي متلازمة معروفة بخصائص سريرية وتغيرات شعاعية تتميز بوجود خزل شقي ونوبات صرعية وعدم تناظر وجهي مع تخلف عقلي. نحن نقوم بتسجيل حالة رجل يبلغ من العمر 25 عام مصاب بضمور المخ والمخيخ المتعكس مع متلازمة دايك دافيدوف ماسون. لقد تمت السيطرة على نوبات الصرع التي تصيب هذا المريض باستخدام توليفة من الأدوية المضادة للصرع. تعتبر هذه الحالة أول حالة ضمور للمخ وللمخيخ المتعكس مع متلازمة دايك دافيدوف ماسون تسجل في المملكة العربية السعودية.

Dyke Davidoff Masson syndrome (DDMS) refers to atrophy or hypoplasia of one cerebral hemisphere following a prior fetal or childhood insult. It has characteristics of clinical and radiological changes. These changes include hemiparesis, seizures, facial-asymmetry, and mental retardation. We present a 25-year-old man with crossed cerebrocerebellar atrophy and DDMS. His seizures were well controlled using a combination of antiepileptic drugs.

Neurosciences 2014; Vol. 19 (1): 52-55

From the College of Medicine (Algabtni, Aldarmahi), King Saud bin Abdulaziz University for Health Sciences, the Department of Microbiology and Medical Parasitology (Al-Rabia), College of Medicine, King Abdulaziz University, Jeddah, Kingdom of Saudi Arabia, and the Department of Neurological Sciences, University of Western Ontario (Young), London, Ontario, Canada.

Received 6th April 2013. Accepted 23rd June 2013.

Address correspondence and reprint request to: Dr. Hussein A. Algabtni, Associate Dean for Clinical Affairs, King Saud bin Abdulaziz University for Health Sciences, PO Box 12723, Jeddah 21483, Kingdom of Saudi Arabia. Tel. +966 (12) 6240000 Ext. 24358. Fax. +966 (12) 6240000 Ext. 22765. E-mail: grdresearches@gmail.com

Diaschisis, a Greek term meaning “shocked throughout”, was first introduced in 1914 by von Monakow¹ to indicate a transient impairment of functional activity in an area remote from the site of primary brain lesion. There are many types of diaschisis. Cerebrocerebellar diaschisis (CCD) is a condition in which cerebellar hypometabolism is ascribed to functional disconnection of the contralateral hemisphere from the cerebral cortex. The first description by Baron et al in 1989,² using positron emission tomography (PET), showed a parallel reduction in blood flow and oxygen uptake in the cerebellar hemisphere contralateral to the side of supratentorial ischemic infarction. Crossed cerebro-cerebellar atrophy (CCA) is an uncommon sequelae of a contralateral cerebral hemispheric lesion. This condition has been described in patients with supratentorial infarct, tumor, arteriovenous malformation, and hemorrhage. The CCA possibly occurs due to interruption of the corticopontocerebellar pathway at the supratentorial level. The CCA is an irreversible process, which can be diagnosed on neuroimaging. Dyke Davidoff Masson syndrome (DDMS) is a well-known syndrome, first described in 1933,³ with characteristic clinical and radiological abnormalities. Here, we describe the clinical and radiological profile of a 25-year-old man with DDMS. This particular case is interesting and unique not only due to the neuroimaging and electrophysiological findings, but also because of the favorable response of the combination of antiepileptic treatment.

Case Report. A 25-year-old man, product of full-term uncomplicated normal vaginal delivery developed bacterial meningitis at age 3 months, complicated by a persistent right-sided hemiparesis.

Disclosure. The authors declare no conflicting interests, support or funding from any drug company.

Since 13 years old he has had Jacksonian motor seizures beginning in the right hand, and spreading to the upper arm and face with variable secondary generalization. He has had several episodes of status epilepticus since the age of 19. Further clinical examination showed that the right hand of the patient was smaller than the left as shown in Figure 1. He had mild mental delay, mild right-sided weakness, brisk reflexes on the right upper and lower limbs and a right Babinski sign. Subtle right side dysmetria on finger-to-nose test and heel-to-shin test were observed with normal gait. An (EEG) indicated left cerebral dysfunction as shown in Figure 2. Furthermore, an MRI showed atrophy of left cerebral and right cerebellar hemispheres with no parenchymal signal abnormalities (Figure 3). There is also hyperpneumatization of left paranasal sinuses, another neuroimaging feature of DDMS. Finally, our observations showed his seizures were well controlled for the past 3 years on 2 antiepileptic medications.

Discussion. In 1933, Dyke, Davidoff, and Masson described a series of 9 patients with characteristic.³ They were clinically characterized by hemiparesis, seizures, facial-asymmetry, and mental retardation. The skull x-ray changes included thickening of bone in the calvarium region with dilatation of ipsilateral sinuses (frontal and ethmoid).⁴ Dyke Davidoff Masson syndrome was initially described as changes in the skull on skull x-ray in patients with cerebral hemiatrophy (CH), but is now also applied more broadly to other cross-sectional imaging studies. It is characterized by compensatory thickening of the skull bone in the calvarium region with enlargement of sinuses (frontal and ethmoidal) and mastoid air-cells. Other changes include ipsilateral falcine displacement and elevation of the petrous ridge. Dyke Davidoff Masson syndrome (also referred to as CH) can be divided into either congenital or acquired. Causes of acquired DDMS include vascular, trauma, and infection. It can be diagnosed by CT or MRI, which shows CH and compensatory ipsilateral skull changes like osseous hypertrophy and hyperpneumatization of the paranasal sinuses and mastoid cells. Dyke Davidoff Masson syndrome is not necessarily associated with CCA.⁴ The usual clinical features of DDMS are hemiparesis, hemiplegia, seizures, mental retardation, and facial-asymmetry.

In a recent large series of DDMS (19 patients),⁴ it was noticed that all patients experienced seizures, and the most common MRI findings were ipsilateral ventricle dilatation, CH, and cortical sulcus enlargement. It was more common in males, and this was thought to be due to the presence of circulating androgens in the

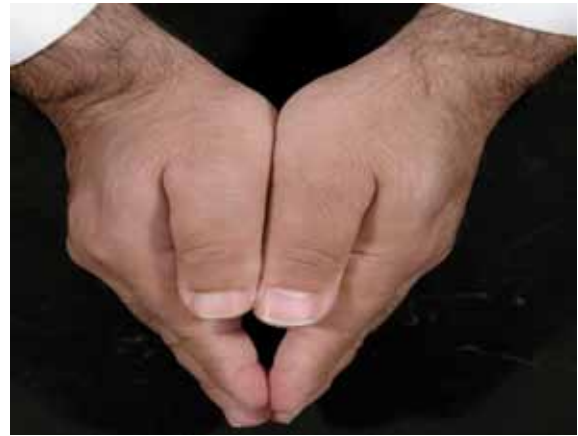

Figure 1 - Photograph of the patient's hands showing asymmetry with the right thumb smaller than left.

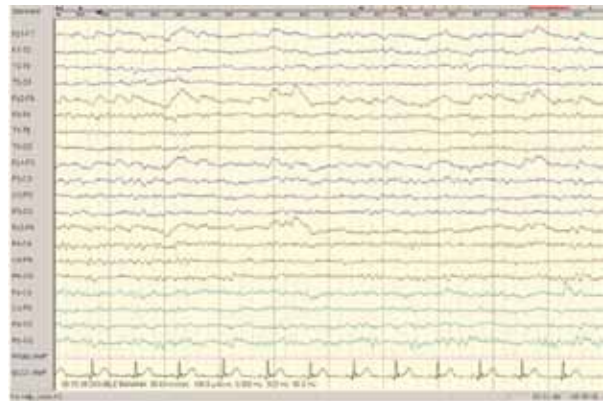


Figure 2 - Patient EEG showing asymmetry, with higher amplitudes on the right side, together with slowing in the left hemisphere and reduced voltage.

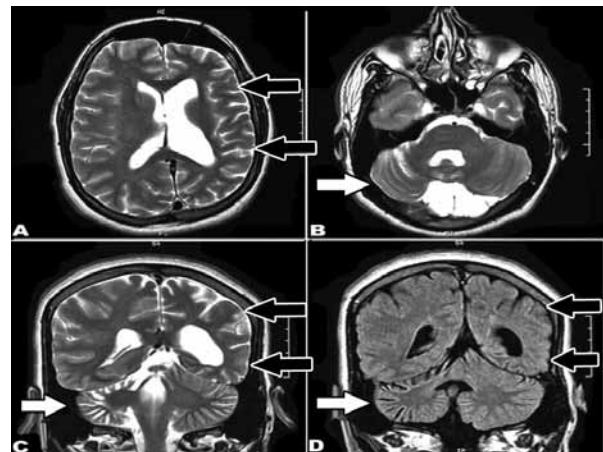


Figure 3 - Patient MRI showing axial (A, B), coronal (C) T2 weight images and coronal FLAIR (D) showing moderate parenchymal and cortical atrophy involving the left cerebral hemisphere (black arrows) and the contralateral cerebellar hemisphere (white arrows). Note the prominence of the sulci and the ventricular dilatation.

developing male brain, which generate a hyperplastic condition such that there may be more extensive neuronal remodeling after injury than in the female brain. Traditionally, CCD is considered a reversible functional process without structural change and can be diagnosed classically by PET scan. It is distinct from the irreversible CCA. However, reversible CCD and irreversible CCA can hypothetically constitute a continuum of the same biological process.⁵ Crossed cerebro-cerebellar atrophy can be diagnosed by CT or MRI. However, MRI T2-weighted, half-Fourier rapid acquisition with relaxation enhancement, and dynamic susceptibility contrast magnetic resonance can also be of help in diagnosing CCD.⁵ Previously reported causes of CCA include vascular: stroke, arteriovenous malformation, CADASIL, cavernous angioma, subdural hematoma, epilepsy. Infections: herpes simplex encephalitis, hydatid cyst, and sickle cell anemia.^{6,7} Further, Rasmussen's encephalitis, familial hemiplegic migraine, neoplasia: brain tumor, MELAS, trauma, Sturge Weber syndrome, intracarotid Amytal procedure, and carotid endarterectomy are also known causes of CCA.⁸ In our case, the cause of CCA is probably a combination of old hemispheric insult due to childhood meningitis and prolonged uncontrolled seizures. Our patient had long-standing intractable focal seizures for many years. Despite this fact, we were able to control his seizures using a combination of antiepileptic medications. The mechanism of CCD is considered to be secondary hypoperfusion due to neuronal deactivation, and the mechanism underlying CCA in seizures is not fully understood. There are some patients with CCD who do not progress to CCA and improve without any residual problem, as previously confirmed by Tien and Ashdown, when they compared CCD and CCA in 26 patients (8 patients with CCA and 18 with CCD).⁹

In another report by Ricardo et al,¹⁰ 51 patients were collected with epilepsy secondary to destructive brain lesions of early development. Only 7 patients had CCA (13%). Their statistical analysis showed that both the extent of the primary supratentorial lesion, and the occurrence of status epilepticus had a significant correlation with the degree of cerebellar volume loss or atrophy. Another consistent finding in all patients with CCA is that none of them had obvious cerebellar signs despite marked cerebellar atrophy. This most likely represents a module of brain plasticity. A study carried out using functional MRI and transcranial magnetic stimulation showed the involvement of ipsilateral parietal posterior cortex and supplementary motor

area in the recovery of hand movements. The ipsilateral primary sensorimotor cortex played only a minor role.¹¹ In several animal studies, inducing focal discharges in the cerebral cortex using penicillin were shown to cause firing in cerebellar Purkinje cells and in dentate nucleus neurons. It is possible that frequent and excessive excitatory input during seizures via glutaminergic corticopontine-cerebellar pathways induces cerebellar atrophy. However, reduced interictal metabolism or perfusion may lead to premature cell death. Crossed cerebro-cerebellar atrophy occurs in cases where the insult happens after the age of one month of life. If the injury occurs earlier, the result will be ipsilateral (or uncrossed) cerebellar atrophy and this is due to differences between the developing and developed brain.

At the time of reporting, our patient has been seizure free for the past 3 years. The lack of obvious cerebellar signs might be explained by the process of cerebellar reorganization and plasticity as mentioned above. If the seizures remain uncontrolled in such patients, a surgical procedure, like hemispherectomy might be of help.

In conclusion, CCA is often associated (but not necessarily) with DDMS or CH. It is possible to differentiate between the reversible CCD from the irreversible CCA, as it was mistakenly used interchangeably in the literature. While there are many case reports on different causes of CCA, it usually develops in patients with an old cerebral hemispheric insult in early childhood. Our patient had an early cerebral insult, with later development of several episodes of status epilepticus. Seizure in such patients can be controlled either by a combination of antiepileptic drugs or by surgery in intractable cases.

Acknowledgments. *The authors thank Dr. Sattam Lingawi for reviewing the images and legends.*

References

1. von Monakow C. Diaschisis (1914 article translated by G Harris). In: Pribram KH, editor. *Brain and Behavior I: Moods, States and Mind*. Baltimore (MD): Penguin; 1969. p. 27-36.
2. Baron JC. Depression of energy metabolism in distant brain structures: studies with positron emission tomography in stroke patients. *Semin Neurol* 1989; 9: 281-285.
3. Dyke CG, Davidoff LM, Masson LB. Cerebral hemiatrophy with homolateral hypertrophy of the skull and sinus. *Surg Gynecol Obstet* 1933; 57: 588-600.
4. Atalar MH, Icgasioglu D, Tas F. Cerebral hemiatrophy (Dyke-Davidoff-Masson syndrome) in childhood: clinicoradiological analysis of 19 cases. *Pediatr Int* 2007; 49: 70-75.
5. Lin DD, Kleinman JT, Wityk RJ, Gottesman RF, Hillis AE, Lee AW, et al. Crossed cerebellar diaschisis in acute stroke detected by dynamic susceptibility contrast MR perfusion imaging. *AJNR Am J Neuroradiol* 2009; 30: 710-715.

6. Tsurugai Y, Matsusue E, Tanabe Y, Sugihara S, Fujii S, Kinoshita T, et al. [Cerebral atrophy and crossed cerebellar atrophy following acute subdural hematoma in Infant]. *Nihon Igaku Hoshasen Gakkai Zasshi* 2005; 65: 273-275. Japanese
7. O'Gorman RL, Siddiqui A, Alsop DC, Jarosz JM. Perfusion MRI demonstrates crossed-cerebellar diaschisis in sickle cell disease. *Pediatr Neurol* 2010; 42: 437-440.
8. Madai VI, Altaner A, Stengl KL, Zaro-Weber O, Heiss WD, von Samson-Himmelstjerna FC, et al. Crossed cerebellar diaschisis after stroke: can perfusion-weighted MRI show functional inactivation? *J Cereb Blood Flow Metab* 2011; 31: 1493-1500.
9. Tien RD, Ashdown BC. Crossed cerebellar diaschisis and crossed cerebellar atrophy: correlation of MR findings, clinical symptoms, and supratentorial diseases in 26 patients. *AJR Am J Roentgenol* 1992; 158: 1155-1159.
10. Teixeira RA, Li LM, Santos SL, Zanardi VA, Guerreiro CA, Cendes F. Crossed cerebellar atrophy in patients with precocious destructive brain insults. *Arch Neurol* 2002; 59: 843-847.
11. Feydy A, Krainik A, Bussel B, Maier MA. Cortical reorganization allows for motor recovery after crossed cerebrocerebellar atrophy. *J Neuroimaging* 2004; 14: 49-53.

Related articles

Al-Jafen BN, Alanazy MH, Scott JN, Pillay N. Magnetic resonance imaging of crossed cerebellar diaschisis and bright pulvinar in status epilepticus. *Neurosciences* 2012; 17: 259-261.

Abdel-Salam GM, Shahab MI, Galal AH, Abdel-Kader AA, Fateen E. Clinical spectrum associated with some structural cerebellar abnormalities. *Neurosciences* 2006; 11: 271-278.