

# Venous thrombosis of the brain

## Retrospective review of 110 patients in Kuwait

Jasem Y. Al-Hashel, MD, FRCPC, John K. John, MRCP (UK), DM (Neurology), Periasamy Vembu, MD, DM (Neurology).

### ABSTRACT

**الأهداف:** لتسليط الضوء على أهمية الأعراض العصبية والمضاعفات في التشخيص المبكر والسيطرة على التخثر الوريدي الدماغي (CVT).

**الطريقة:** قام الباحثون بتحليل الحالة بأثر رجعي من 110 مريضاً اللذين عانوا من CVT و عولجوا في مركز علم الأعصاب ، مستشفى ابن سينا، الكويت خلال الفترة من يناير 2000م إلى سبتمبر 2013م. تم استرجاع سجلات المرضى الذين عانوا من CVT، ودخلت في ورقة البيانات. وقد تم تحليل مختلف الإشارات والأعراض العصبية عرضاً رئيسياً استناداً إلى تكرارها، بداية المرض والعلاج.

**النتائج:** في هذه الدراسة أدرجت (110) مريضاً، وكانت نسبة الذكور إلى الإناث 1:1.7. كانت الإشارات والأعراض العصبية (82%) صداع، (42%) النوبات، العجز العصبي البؤري (33%). وسجلت 35 مريضاً (32%) بالوذمة الحليمية العصبية مع الضغط داخل الجمجمة. وسجلت 27 مريضاً بالاحتشاء الوريدي والنزيف الوريدي ونزيف داخل المخ أو تحت العنكبوتية في 7 مريضاً. كانت الجيوب الوريدية تشارك الجيب السهمي العلوي في 54.5%، والجيوب الأنفية السيني العرضية في 52%.

**الخاتمة:** من أكثر الأعراض العصبية شيوعاً هي الصداع، والنوبات، والعجز العصبي البؤري. استخدمت مضادات التخثر (الهيبارين النظامية) كعلاج أولي، بما في ذلك المرضى الذين يعانون من نزيف داخل المخ. سُجلت استخدام ستيرويد ومدرات البول التناضحي بمقاييس مضادات الوذمات في 25% من الحالات. يمكن علاج ضغط داخل الجمجمة ICP التي أثارتهما البزل القطني وسائل الدماغي الشوكي CSF الذي قد يمنع الفشل البصري.

**Objective:** To highlight the importance of neurological presentation and complications in the early diagnosis and management of cerebral venous thrombosis (CVT).

**Methods:** We performed a retrospective case analysis of 110 patients with CVT treated at the Neurology Center, Ibn Sina Hospital, in Kuwait from January 2000 to September 2013. The records of patients with CVT were retrieved and entered in a data sheet. The different neurological presenting signs and symptoms were analyzed based on their frequency, pathogenesis, and treatment.

**Results:** One hundred and ten (110) patients were included in this study, with a male to female ratio of 1:1.7. Neurological signs and symptoms were headache (82%), seizures (42%), and focal neurological deficits (33%). Papilledema with raised intracranial pressure was recorded in 35 patients (32%). Venous and hemorrhagic venous infarctions were recorded in 27 patients, and multiple intracerebral or subarachnoid hemorrhages in 7 patients. The venous sinuses involved were the superior sagittal sinus in 54.5%, and transverse sigmoid sinuses in 52%.

**Conclusion:** Headache, seizures, and focal neurological deficits were the most common neurological presentation. Anticoagulants (systemic heparin) were used as first-line therapy, including patients with intracerebral hemorrhage. The use of steroids and osmotic diuretics as anti-edema measures were recorded in 25% of cases. Treating raised ICP by repeated lumbar puncture and CSF drain could prevent visual failure.

*Neurosciences 2014; Vol. 19 (2): 111-117*

*From the Department of Neurology, Ibn Sina Hospital, Safat, Kuwait.*

*Received 21st December 2013. Accepted 29th March 2014.*

*Address correspondence and reprint request to: Dr. Periasamy Vembu, Consultant Neurologist, Department of Neurology, Ibn Sina Hospital, PO Box 25427, Safat 13115, Kuwait. Tel. +965 24803676 / 24840837. Fax. +965 24849226. E-mail: drvperiasamy@yahoo.com*

**Disclosure.** The authors declare no conflicting interests, support or funding from any drug company.

Cerebral venous thrombosis (CVT) results from thrombosis of intracranial venous sinuses. The signs and symptoms associated with CVT are broad. If the disease is unrecognized, a delay in treatment may result in cerebral edema, intracranial hypertension, cerebral ischemia, and hemorrhagic venous infarction. Rapid neurological worsening can cause coma and even death.<sup>1</sup> The mortality ranges from 5-30%. Diagnosing CVT often challenges the physicians or specialists, owing to the nonspecific symptoms and the broad spectrum of presentation.<sup>1</sup> The use of anticoagulants (heparin) in CVT has been reported for several decades. There are several rationales for using anticoagulants in CVT, but the use of anticoagulants in patients with CVT associated with cerebral hemorrhage is still controversial. Steroids may have a role in CVT by decreasing vasogenic edema, but in patients with CVT, steroids are not recommended, even in the presence of parenchymal brain lesions. The objective of this study was to retrospectively analyze 110 patients with CVT, to record the pattern of clinical presentation and complications, and to highlight treatment with steroids and heparin in unusual presentations, such as brain edema with intracranial hemorrhage (ICH), subarachnoid hemorrhage (SAH), and raised intracranial pressure (ICP) secondary to venous thrombosis.

**Methods.** We performed a retrospective analysis of 110 patients registered from January 2000 to September 2013, who were diagnosed as having CVT by clinical and imaging studies and treated at Ibn Sina Hospital, Kuwait. The patient's files were collected, and the data were abstracted anonymously for this review. The study was approved by the Institutional ethical review committee, which was given 'exemption' status by the ISH Institutional Medical Ethical Committee, not requiring consent from patients. The diagnosis of CVT was made based on the clinical presentation and by imaging studies. Magnetic resonance imaging (MRV) and CT venography were the method of choice for diagnosis of CVT. The different neurological presenting signs and symptoms were analyzed based on their frequency, pathogenesis, and treatment. Based on these data, the frequencies of various neurological manifestations were analyzed using simple statistical methods.

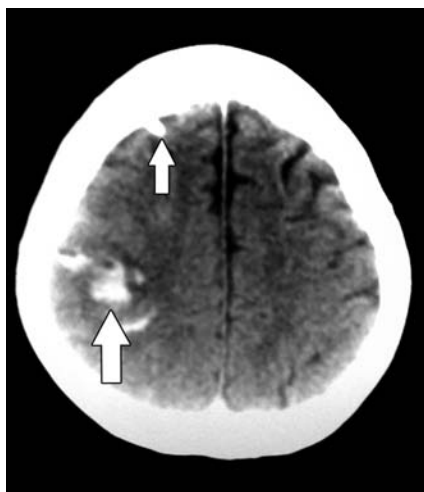
**Results.** The records of 110 patients, 41 men and 69 women who were diagnosed and treated as CVT were retrieved. Their ages ranged from 20-60 years, with a median age of 30, and a male to female ratio of 1:1.7. The common neurological manifestations

were headache, seizures, papilledema, and focal neurological deficits. Headache was the most common symptom recorded in our study (82%), and the next most common manifestation was focal or generalized seizures as recorded in 46 patients (42%). Among the 46 patients who presented with different types of seizures (focal or generalized), focal neurological deficits were recorded in 19 patients (14 female and 5 male). In general, focal neurological deficits were recorded in 36 patients (33%), and included hemiplegia or hemiparesis, cranial nerve palsies, and cerebellar deficits. Eight patients (3 males, 5 females) presented with ataxia and cerebellar signs due to cerebellar infarction or hemorrhage. Six patients developed varying degrees of visual impairment secondary to raised ICP with bilateral papilledema. The parenchymal lesions in the brain were venous infarction, hemorrhagic venous infarction, and multiple intracerebral bleeds. Most of these patients developed raised ICP and brain edema of varying degrees, requiring anti-edema measures with parenteral steroids, and intravenous mannitol with anticoagulants of choice. Three males and 12 females had venous infarction, and 3 males and 9 females had hemorrhagic venous infarction. Seven patients (4 males, 3 females) had SAH at presentation. Sixty patients (54.5%) had papilledema at the time of presentation (22 males, 38 females). Out of the 60 patients, CSF pressure was recorded in 40 patients and was found to be elevated in 35 patients. The CSF pressure ranged from 200-600 mm of H<sub>2</sub>O. In 5 patients the pressure was normal, and in the remaining 20 patients, lumbar puncture was not carried out. Among the 35 patients who had raised CSF pressure, 7 patients had focal neurological deficits with or without focal seizures at the time of presentation. The remaining 28 patients (25%) presented like idiopathic intracranial hypertension (IIH) (Table 1). The most common dural sinuses involved were the superior sagittal sinus (SSS) (54.5%), the transverse and sigmoid sinuses (52%), and the deep cerebral veins involved in 3 patients. Cavernous sinus thrombosis was seen in 5.4% (n=6) of patients. Venous thrombosis was diagnosed in 10 patients with Behçet's disease. The serum D-dimer level was tested in only 60 patients (54.5%), and the levels were raised in 35 patients (58%). The normal level of D-dimer will not exclude venous thrombosis. Fifty-five patients were treated with unfractionated heparin, and 30 patients were treated with low molecular weight heparin (LMWH) for the required period of time followed by warfarin. Twenty patients directly received warfarin, with the INR maintained around 2-3. Sixty percent of patients recovered with in 2-4 weeks, and 20% of patients required ICU admission.

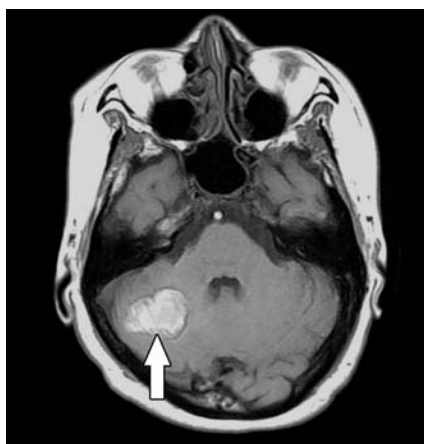**Table 1** - Frequency of signs and symptoms in patients with cerebral venous thrombosis (N=110).

Presenting signs & symptoms	No. of patients	Frequency (%)
Headache-different types	90	(82)
Seizures: focal or generalized	46	(42)
Focal neurological deficits	36	(33)
Papilledema	60	(54.5)
Papilledema + raised pressure	35	(32)
Behçet's disease & CVT	10	(9)
Ataxia/cerebellar lesion	8	(7)
Cavernous sinus thrombosis	6	(5.4)
Venous/hemorrhagic infarction/SAH	34	(31)
Visual impairment/papilledema	6	(5.4)
Superior sagittal sinus thrombosis	60	(54.5)
Transverse & sigmoid sinus	57	(52)

CVT - cerebral venous thrombosis, SAH - subarachnoid hemorrhage



**Figure 1** - A CT brain axial view showing right parietal hemorrhagic venous infarction. The external ventricular drain tube in the right frontal lobe is shown by the small arrow.



**Figure 2** - Axial MRI T1-weighted image shows hemorrhagic infarction in the right cerebellar hemisphere in a 41-year-old lady secondary to bilateral transverse sinus thrombosis.

**Discussion.** Cerebral venous thrombosis is known for its diverse clinical manifestations with unpredictable outcome. The clinical diagnosis of CVT is often difficult. However, the sensitivity to diagnose parenchymal and blood flow studies with modern radiological imaging techniques have facilitated easier, early diagnosis, and initiation of treatment.<sup>2</sup> In venous thrombosis, the symptoms are caused by obstruction of the SSS, lateral sinus, sigmoid sinus, or deep cerebral veins. As a result, the CSF absorption is impaired; causing raised ICP. Obstruction of draining veins causes regional venous infarction.<sup>3</sup>

Headache was the most frequent symptom and presenting complaint of our patients. It often antedates any obvious symptoms or signs of increased ICP, mimicking IHH. Headache was present even in the absence of intracranial hypertension, SAH, or meningitis. The exact mechanism of headache remains unknown.<sup>3,4</sup> The venous infarction or intracerebral hematoma associated with CVT in some patients produces a mass effect with raised ICP, which causes headache and vomiting requiring anti-edema measures.

The next most common presenting symptom was seizure either partial or generalized. Partial seizures were more often seen, and were associated with fluctuating motor or sensory deficits. Patients with focal motor deficits due to cortical vein thrombosis and ICH carry a higher risk for early seizures.<sup>3</sup> In our study, 46 patients presented with focal or generalized seizures and anticonvulsant treatment was given for approximately one year.

Venous stroke due to obstruction of draining veins causes venous infarction or hemorrhagic venous infarction, which does not correlate with the classical arterial territory. The veins of Labbé and Trolard were more commonly involved and resulted in parieto-temporal venous infarction.<sup>4</sup> Hemorrhagic infarction and or parenchymal hemorrhages were found on MRI or CT at the time of diagnosis in almost half of our patients; this could have been due to an increase in venous and capillary pressure, resulting in rupture of those veins (Figures 1 & 2).<sup>5</sup> In our study, focal neurological signs were recorded in 36 patients (33%), which might be a consequence of a lesion localized in a specific functional area.

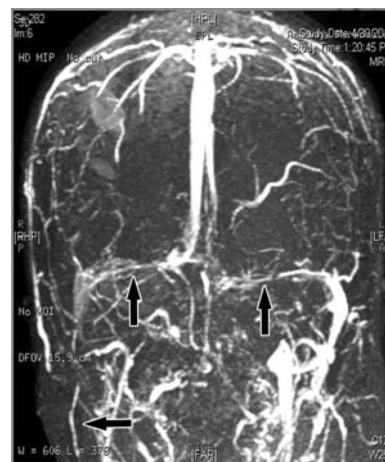
The most common neurological deficits were hemiplegia or hemi-paresis, para-paresis, cranial nerve palsies, or cerebellar ataxia. Both thalami drain into the vein of Galen and straight sinus, and so bilateral thalamic involvement is frequently encountered in CVT. Unilateral thalamic edema occurs when all internal cerebral veins are occluded. This may mimic a thalamic tumor. Patients with neuro-Behçet's syndrome

develop CVT as a complication. Central nervous system disease and major vessel events are serious complications of Behçet's syndrome. Around 25% of patients with Behçet's disease have vascular disease in the form of venous thrombosis,<sup>6</sup> or deep vein thrombosis in the leg. Anticoagulation and steroids represent safe and effective therapy in such patients.<sup>7</sup> The pathology is vasculitis of an autoimmune nature. In our study, we recorded CVT in 10 (9%) of our patients with Behçet's disease. Vandenberghe et al<sup>8</sup> reported 4 patients with multiple sclerosis who developed cerebral venous thrombosis. Two of these patients received IV methylprednisolone 48 hours prior and were also taking oral contraceptives, which is a known a risk factor for CVT.

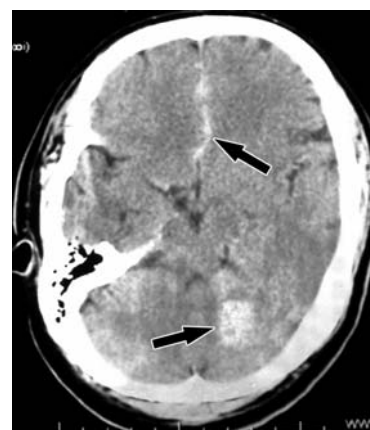
Papilledema was found in 60 patients who presented with headache, and 35 patients had elevated CSF pressure. Papilledema can sometimes be the only manifestation of CVT.<sup>9</sup> In our study, in patients who presented with papilledema and focal neurological deficits, multiple venous sinuses were involved and there was a clinical co-relation between papilledema and extensive SSS thrombosis. Jungmann et al<sup>10</sup> reported a case of CVT in a young woman in the post-partum period after epidural anesthesia during delivery. With increasing use of regional anesthesia in obstetrics, venous thrombosis should be considered as a differential diagnosis of post-dural puncture headache.<sup>10</sup>

Early diagnosis of CVT is a crucial point to initiate early treatment. Agid et al<sup>2</sup> proposed that when available, MRI supplemented with the technique of Gadolinium enhanced MRV, are the methods of choice for the diagnosis of dural sinus thrombosis. The MRI/MRV are now the imaging technique of choice for the diagnosis of CVT. The lack of signal void, and the absence of signal on MRV is the hallmark of thrombus in a particular dural sinus (Figure 3).

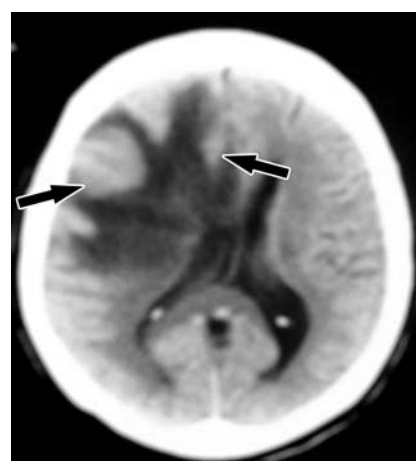
Tardy et al<sup>11</sup> reported that measurement of serum D-dimer level in the blood of patients with acute headaches with or without focal neurological deficits has potential utility in the diagnosis of CVT. Plasma levels of D-dimers, which are fragments of cross-linked fibrin digested by plasmin, have been shown to be sensitive for the diagnosis of venous thrombosis and pulmonary embolism. Patients who present with acute headache and clinically suspected CVT should undergo urgent MR venography for confirmation of the diagnosis if the D-dimer test is positive.<sup>12</sup> The normal D-dimer level is less than 500 ng/L or 0-0.5 µg/ml, and in patients with CVT the levels increase 5 to 10 times. In our series, the serum D-dimer test was carried out for only 60 patients (22 males, and 38 females), and it was raised in only 35 patients (58%).



**Figure 3** - Magnetic resonance venography coronal reconstruction view showing bilateral transverse and right sigmoid venous sinus thrombosis with prominent collateral veins.



**Figure 4** - Axial CT brain showing left intracerebellar hemorrhage and anterior inter-hemispherical fissure subarachnoid hemorrhage in a patient with CVT (arrows).



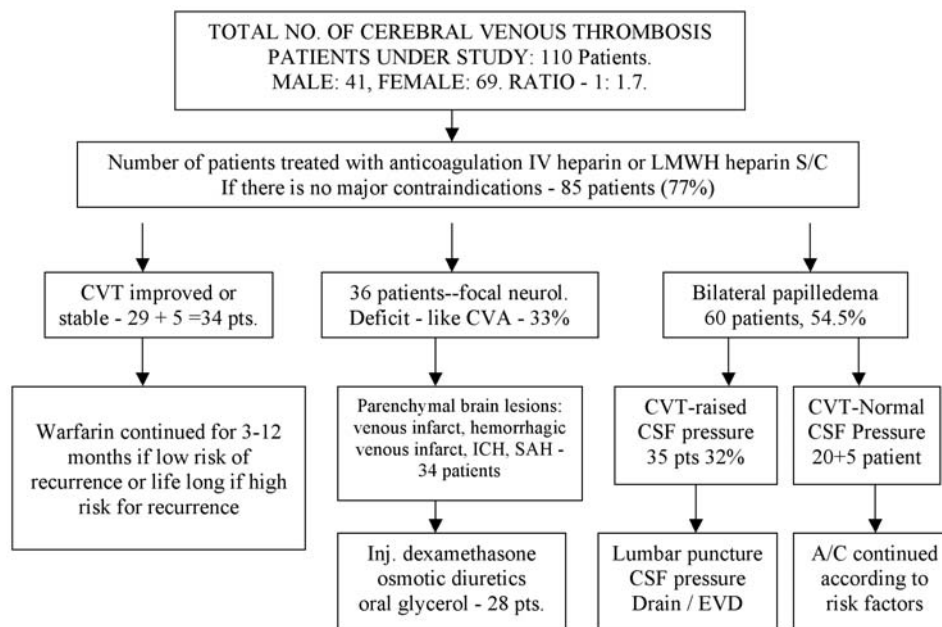
**Figure 5** - Axial CT showing right fronto-parietal infarct with brain edema, mass effect, and midline shift in a case of cerebral venous thrombosis (arrows).



Heparin remains the first-line treatment for CVT because of its efficacy, safety, and feasibility.<sup>1</sup> This treatment is aimed at preventing the thrombus extension and maintaining the venous pathways. It has been shown to be the most effective treatment modality; though its risk and benefits need to be evaluated on an individual basis.<sup>13</sup> The treatment of CVT with heparin has been controversial for decades. This concern was based on the fact that 30-40% of all patients with CVT have some degree of cerebral hemorrhage at the time of admission. Most experts now agree that patients with CVT should receive a rapid and full course of anticoagulation as soon as the diagnosis is made. Anticoagulation is the treatment in patients with significant, and even life threatening complications.<sup>14</sup> The role of heparin in the treatment of CVT was well highlighted in the European Federation of Neurological Societies (EFNS) guidelines.<sup>15</sup> It also describes the current therapeutic measures of different modes of anticoagulation therapy, the use of thrombolysis and symptomatic therapy, including control of seizures and elevated ICP. All patients with CVT without contraindication for anticoagulation should be treated with dose-adjusted intravenous heparin or body weight-adjusted subcutaneous fractionated heparin (LMWH). Concomitant ICH related to CVT is not a contraindication for heparin therapy (Figure 4).<sup>16</sup>

Follow up oral anticoagulation should be given for 6-12 months in patients with idiopathic CVT and in those with mild hereditary thrombophilia. In our study, 34 patients (31%) had either venous infarction or multiple hemorrhagic venous infarctions with SAH or ICH at the onset or as a complication related to CVT. All patients with CVT with evidence of ICH or venous hemorrhagic infarction received a full course of anticoagulants, heparin, or LMWH.

Although there is increasing evidence that treatment with heparin remains safe and is appropriate in patients with hemorrhagic venous infarction, still some controversy remains on the use of anticoagulation for CVT in the presence of large ICH or hemorrhage located in the temporal lobe.<sup>17</sup> No mortality was seen in the current practice of treating CVT with heparin. Other treatment modalities include corticosteroids and osmotic diuretics as anti-edema measures to reduce the cerebral edema, sedatives to reduce the metabolic needs of the brain, and CSF drainage to decrease ICP. Anti edema treatment is necessary in 25% of patients with raised ICP in patients with parenchymal lesions such as ICH or hemorrhagic venous infarction related to CVT. Steroids could decrease vasogenic edema that develops with CVT and reduces the intracranial hypertension; however, others argue that steroids could be harmful because of their potential prothrombotic properties.<sup>18,19</sup>



**Figure 6** - Flow chart showing the various types of treatment modalities in the different groups of patients. IV - intravenous, LMWH - low molecular weight heparin, S/C - subcutaneous, CVT - cerebral venous thrombosis, CVA - cerebrovascular accident, ICH - intracranial hemorrhage, SAH - subarachnoid hemorrhage, Inj - injection, EVD - external ventricular drain, A/C - anticoagulant

No randomized controlled trials or case control study have so far analyzed the efficacy of steroids. Forbes et al<sup>20</sup> reported cytotoxic edema in the pathogenesis of cerebral venous infarction as evidenced by restricted water diffusion, commonly found on MRI images in patients with CVT. Cytotoxic edema produced by cerebral venous infarction in patients with CVT was improved by steroids (Figure 5). However in our series, steroids (dexamethasone injection) were used to treat cerebral edema in 28 patients (25%) without any obvious complications. The neurological deficits, headaches, and cerebral edema were much reduced (Figure 6).

The EFNS guidelines<sup>15</sup> advise that osmotic substances might be harmful in venous outflow obstruction since they are not as quickly eliminated from the intracerebral circulation as in other conditions. In our study, osmotic diuretics (20% mannitol) were used along with steroids without complications. Other options of invasive therapy, such as transvascular mechanical thrombectomy and surgical thrombectomy with thrombolysing agents are available.<sup>21</sup> In our study, none of the patients were treated with the new surgical treatments, such as rheolytic thrombectomy or by transvascular mechanical thrombectomy.

A better prognosis was demonstrated in patients who presented with headache and papilledema alone, and who had rapid venous sinus recanalization or development of collateral veins. The main cause of acute death in CVT was found to be neurologic, and the most frequent mechanism was trans-tentorial herniation. The cause of death is due to hemorrhagic infarction, sepsis, pulmonary embolism, and brain edema with herniation or with an underlying systemic disorder like cancer.<sup>13</sup>

There are still many unsolved issues in the pathophysiology, diagnosis, and management of CVT. Future study of steroid use, osmotic diuretics, and the use of any kind of anticoagulants without contraindications are warranted by case controlled study.

This study had certain limitations. Since it is a retrospective study, the methodology was not uniformly applicable in all patients. The serum D-dimer lab test was not available in the initial period of the study, so this test was performed in only 60 patients.

In conclusion, headache, focal seizures, and focal neurological deficits were common neurological presentations. The serum D-dimer level was helpful for early diagnosis only in 58% of patients for whom it was carried out. Anticoagulants (heparin/Clexane) were used in most patients, and this is not a contraindication in the presence of hemorrhagic venous infarction or stable intracerebral hemorrhages. The use of corticosteroids or

osmotic diuretics as anti-edema measures, were more useful in selected cases with brain parenchymal lesions and brain edema. Patients with bilateral papilledema and threatened visual failure should have immediate treatment with repeated lumbar puncture and CSF drain to prevent visual loss. Heparin is the gold standard first-line treatment for CVT. Early diagnosis and treatment with heparin are mandatory to prevent morbidity and mortality.

**Acknowledgments.** We thank Dr. Mohammed A. Rudwan, Senior Neuro-Radiologist, Ibn Sina Hospital, for his review of the images and legends, and attesting to their clarity and correctness.

## References

1. Bousser MG, Ferro JM. Cerebral venous thrombosis: an update. *Lancet Neurol* 2007; 6: 162-170.
2. Agid R, Shelef I, Scott JN, Farb RI. Imaging of the intracranial venous system. *Neurologist* 2008; 14: 12-22.
3. Ferro JM, Canhão P, Bousser MG, Stam J, Barinagarrementeria F; ISCVT Investigators. Early seizures in cerebral vein and dural sinus thrombosis: risk factors and role of antiepileptics. *Stroke* 2008; 39: 1152-1158.
4. Vembu P, John JK, Mohammed MI, Al-Shubaili AF. Cerebral venous thrombosis in Kuwait. Clinical presentation, risk factors and management. *Neurosciences (Riyadh)* 2011; 16: 129-136.
5. Kajtazi NI, Zimmerman VA, Arulneyam JC, Al-Shami FM. Cerebral venous thrombosis in Saudi Arabia. Clinical variables, response to treatment, and outcome. *Neurosciences (Riyadh)* 2009; 14: 349-354.
6. Saadoun D, Wechsler B, Resche-Rigon M, Trad S, Le Thi Huong D, Sbai A, et al. Cerebral venous thrombosis in four patients with multiple sclerosis. *Eur J Neurol* 2003; 10: 63-66.
7. Tunc R, Saip S, Siva A, Yazici H. Cerebral venous thrombosis is associated with major vessel disease in Behçet's syndrome. *Ann Rheum Dis* 2004; 63: 1693-1694.
8. Vandenberghe N, Debouverie M, Anxionnat R, Clavelou P, Bouly S, Weber M. Cerebral venous thrombosis in four patients with multiple sclerosis. *Eur J Neurol* 2003; 10: 63-66.
9. Subash M, Parmar DN. Papilloedema as the sole presenting feature of postpartum cerebral venous sinus thrombosis. *Can J Ophthalmol* 2009; 44: e1-2.
10. Jungmann V, Werner R, Bergmann J, Daum J, Wöhrle JC, Dünnebacke J, et al. [Postpartum cerebral venous sinus thrombosis after epidural anaesthesia]. *Anaesthesist* 2009; 58: 268-272. German.
11. Tardy B, Tardy-Poncet B, Viallon A, Piot M, Garnier P, Mohamedi R, et al. D-dimer levels in patients with suspected acute cerebral venous thrombosis. *Am J Med* 2002; 113: 238-241.
12. Misra UK, Kalita J, Bansal V. D-dimer is useful in the diagnosis of cortical venous Sinus Thrombosis. *Neurol India* 2009; 57: 50-54.
13. Wasay M, Kamal AK. Anticoagulation in cerebral venous sinus thrombosis: are we treating ourselves. *Arch Neurol* 2008; 65: 985-987.
14. Stam J. Sinus thrombosis should be treated with anticoagulation. *Arch Neurol* 2008; 65: 984-985.

15. Einhäupl K, Bousser MG, de Bruijn SF, Ferro JM, Martinelli I, Masuhr F, et al. EFNS guidelines on the treatment of cerebral venous sinus thrombosis. *Eur J Neurol* 2006; 13: 553-559.
16. Fink JN, McAuley DL. Safety of anticoagulation for cerebral venous thrombosis associated with intracerebral hematoma. *Neurology* 2001; 57: 1138-1139.
17. Hegazi MO, Ahmed S, Sakr MG, Hassanien OA. Anticoagulation for cerebral venous thrombosis with subarachnoid hemorrhage: a case report. *Med Princ Pract* 2010; 19: 73-75.
18. Canhão P, Cortesão A, Cabral M, Ferro JM, Stam J, Bousser MG, et al. Are steroids useful to treat cerebral venous thrombosis? *Stroke* 2008; 39: 105-110.
19. Stolz E, Klotzsch C, Schlachetzki F, Rahimi A. High-dose corticosteroid treatment is associated with an increased risk of developing cerebral venous thrombosis. *Eur Neurol* 2003; 49: 247-248.
20. Forbes KP, Pipe JG, Heiserman JE. Evidence for cytotoxic edema in the pathogenesis of cerebral venous infarction. *AJNR Am J Neuroradiol* 2001; 22: 450-455.
21. Baker MD, Opatowsky MJ, Wilson JA, Glazier SS, Morris PP. Rheolytic catheter and thrombolysis of dural venous sinus thrombosis: a case series. *Neurosurgery* 2001; 48: 487-493.

#### Related articles

Algahtani HA, Aldarmahi AA, Cerebral venous sinus thrombosis. *Neurosciences* 2014; 19: 11-16.

Algahtani HA, Abdu AP, Shami AM, Hassan AE, Madkour MA, Al-Ghamdi SM, et al. Cerebral venous sinus thrombosis in Saudi Arabia. *Neurosciences* 2011; 16: 329-334.

Kajtazi NI, Zimmerman VA, Arulneyam JC, Al-Shami SY, Al-Senani FM. Cerebral venous thrombosis in Saudi Arabia. Clinical variables, response to treatment, and outcome. *Neurosciences* 2009; 14: 349-354.