

# Alternatives to surgical approach for giant spinal schwannomas

Mehmet R. Onen, MD, Mehmet Simsek, MD, Sait Naderi, MD.

## ABSTRACT

**الأهداف:** للنظر في الطرق التشخيصية و الأساليب العلاجية لأورام العصب الشوكي الشوانوما ذات الحجم الضخم .

**الطريقة:** تم مراجعة المعلومات الاكلينيكية والأشعة التشخيصية التي تم الحصول عليها قبل و بعد القيام بالتدخل الجراحي ، وكذلك معلومات عن الجوانب الجراحية 18 حالة شوانوما العصب الشوكي ذات الحجم الضخم قد أجريت لهم جراحات خلال الفترة من يناير 2008م إلى ديسمبر 2013م .

**النتائج:** تتضمن العينة 15 (83.3%) أنثى و3 (16.6%) ذكور . تراوحت أعمار الحالات ما بين 16-70 عاما (متوسط الأعمار 45.8) . متوسط فترة وجود الأعراض كان 1.5 شهرا (يتراوح بين 1-48 شهرا) . كان هناك ألم محلي في 15 حالة و ألم جذري في 6 حالات . كانت أغلب الأورام في المنطقة القطنية العجزوية (11 حالة ، 61.1%) . استخدم أسلوب من خارج نطاق العصب الشوكي في 7 حالات ، الأسلوب الخلفي في 6 حالات ، واستخدم أسلوب مشترك يتضمن الأسلوب الخلفي و آخر من خلال البطن في حالتين ، و كذلك الأسلوب الخلفي استخدم بالاشتراك مع أسلوب من خارج نطاق العصب الشوكي في حالتين ، و استخدم أسلوب من خلف الغشاء البريتوني في حالة واحدة . تم استئصال الورم كاملا في جميع الحالات . كان متوسط فترة المتابعة 38.5 شهرا (يتراوح بين 20-68) .

**الخاتمة:** أورام العصب الشوكي الشوانوما ذات الحجم الضخم تظهر عوامل تشخيصية وجراحية فريدة . يؤثر اختيار الأسلوب الأمثل بشكل كبير و يؤثر على نجاح العلاج .

**Objective:** To review the diagnoses and surgical approach characteristics of giant spinal schwannomas (GSS) patients.

**Methods:** We reviewed the preoperative and postoperative radiological and clinical data, and the surgical aspects of 18 GSS patients who underwent surgery in the Department of Neurosurgery, Umraniye Teaching Hospital and Research State Hospital, Istanbul, Turkey between January 2008 and December 2013.

**Results:** There were 15 (83.3%) female and 3 (16.6%) male patients. The age range was 16-70 years (average: 45.8). Average symptom duration was 1.5 months

(range: 1-48). There was local pain in 15 cases, and radicular pain in 6 cases. The GSSs were most frequently located in the lumbosacral area (11 cases, 61.1%). An extraforaminal surgical approach was employed in 7 cases, a posterior approach was employed in 6 cases, a combined anterior transabdominal and posterior approach was employed in 2 cases, a combined posterior and extraforaminal approach was employed in 2 cases, and a retroperitoneal approach was applied in one case. The tumors were completely excised in all cases. The mean follow-up period was 38.5 months (range: 20-68).

**Conclusion:** Giant spinal schwannomas exhibit unique diagnostic and surgical factors. The selection of an appropriate approach significantly influences the success of the treatment.

*Neurosciences 2016; Vol. 21 (1): 30-36  
doi: 10.17712/nsj.2016.1.20150242*

*from the Department of Neurosurgery, Umraniye Teaching and Research State Hospital, Istanbul, Turkey.*

*Received 6th April 2015. Accepted 21st October 2015.*

*Address correspondence and reprint request to: Dr. Mehmet R. Onen, Department of Neurosurgery, Umraniye Teaching and Research State Hospital, Istanbul, Turkey. E-mail: mresid@gmail.com*

Spinal schwannomas (SSs) comprise approximately 25-30% of all spinal tumors.<sup>1,2</sup> Schwannomas are frequently located in the lumbar spine. They are usually solitary lesions, and multiple schwannomas should raise suspicion of neurofibromatosis (NF).<sup>1-3</sup> Although SSs

**Disclosure.** Authors disclose no affiliation or financial involvement with organizations or entities with a direct financial interest in the subject matter or materials discussed in the manuscript. No funding was received for this work from any organization.

are commonly benign tumors, they rarely display malignant characteristics.<sup>1</sup> They can be intradural extramedullary or totally extradural tumors. These tumors grow slowly, enlarge the foramen, and can extend out of the spinal canal. Schwannomas that grow out of the canal can become very large.

Sridhar<sup>4</sup> classified spinal schwannomas according to their sizes and extensions; in this classification, intraspinal schwannomas that occupy more than 2 vertebral segments in length and tumors with extraspinal components larger than 2.5 cm are defined as giant SS (GSS).<sup>4</sup> The aim of this study was to review the diagnoses, tumor characteristics, and surgical approaches of patients with GSS who underwent surgery at our clinic.

**Methods.** Data from 18 patients who underwent surgery for GSS in the Department of Neurosurgery, Umraniye Teaching and Research State Hospital, Istanbul, Turkey between January 2008 and December 2013 were retrospectively analyzed.

Although type II and above tumors are accepted as GSS according to Sridhar's classification,<sup>4</sup> in this study we included all Sridhar type III, IV, and V GSS cases (namely, all tumors were larger than 2.5 cm). Many aspects of the cases, including demographic aspects (age, gender), symptoms, symptom duration, preoperative and postoperative neurologic states (assessed via the Nurick scale),<sup>5</sup> tumor localization, and selected surgical approach were examined. Radiological assessments included preoperative and postoperative CT, and MRI; digital subtraction angiography (DSA) was employed in 2 cases with abdominal extensions of the tumors. All cases were monitored radiologically and clinically.

**Inclusion and exclusion criteria.** This study included cases diagnosed with benign spinal schwannoma in histopathological analysis, and the ones that are type III and above according to the Sridhar classification. The cases diagnosed with malignancy, and those smaller than type III on Sridhar were disregarded.

**Statistical analysis.** Statistical analysis was performed using the Statistical Package for Social Sciences, version 12 (SPSS Inc., Chicago, IL, USA). Values were expressed as means±SD or as percentages. Means were compared by the Student's t-test, or one-way ANOVA test. The percentage was calculated in the presence and absence group by Pearson's Chi-square test. The limit of statistical significance was set at  $p < 0.05$ .

**Results.** Thirty (25.6%) SS cases were identified among 117 operated spinal tumors. Eighteen (60%) of these cases were type III or above according to

Sridhar's classification and were assessed as GSSs. Of the 18 GSS cases, 15 (83.3%) were female, and 3 (16.6%) were male. The age range was 16-70 (average: 45.8). The average symptom duration was 1.5 months (range: 1-48 months). Local pain was present in 15 cases, and radicular pain was present in 6 cases. Two patients (11.1%) complained of cervico thoracically-localized paraparesis, and 2 (11.1%) patients with sacral localizations complained of urinary retention and constipation.

The GSSs were most frequently located in the lumbosacral area (11 cases: 61.1%), and their distribution is indicated in Table 1. The NF type II lesions were present in 2 cases. The tumor types according to Sridhar classification, and their regional distribution are indicated in Table 2. Twelve (66.6%) GSSs were located extradurally, 2 (11.1%) were intradural, and 4 (22.2%) were both intradural and extradural. Only one case with a lumbar GSS had a history of previous surgery. All other cases underwent primary surgery at our clinic.

**Surgical approaches.** Differently localized tumors were approached differently. While the spine surgery team performed the posterior and posterolateral transabdominal methods, the access surgeons (namely, gynecologist and general surgeon) conducted the anterolateral retroperitoneal and anterior transabdominal methods. A posterior extraforaminal approach was applied in 7 cases, a posterior approach in 6 cases, a combined anterior transabdominal and posterior approach in 2 cases, a combined posterior and extraforaminal approach in 2 cases and a retroperitoneal approach in one case. Hemilaminectomy or total laminectomy was preferred for cases in which the lesions were completely within the spinal canal. The posterior method was the standard approach. In this method, the surgeon can see and control both proximal and distal poles of the tumor. Also, the surgeon can see the relation between the tumor, nerve roots, and rootlets. Therefore, this approach is safe for the experienced surgeons.

The posterolateral transforaminal approach was applied to the lumbar foraminal cases (Figure 1A). The extraforaminal corridor was used after an incision in the skin was created 4 cm lateral to the middle line. A similar approach was used for the thoracic foraminal cases in which rib head resections were performed to reach the foraminal area (Figure 1B). An anterolateral retroperitoneal approach was used in a foraminal GSS case with extension to the retroperitoneal area. For the giant sacral cases with extensions into the presacral area and abdominal cavity, staged surgeries were planned. In these cases, the intraabdominal, presacral, and intracorporal portions of the sacral GSS were initially resected using a transabdominal approach. Next, the

**Table 1** - Clinical summary of giant spinal schwannoma patients.

Case	Age/ gender	Localization	Nurick Score		Symptoms	Symptom duration (months)	Sridhar classification	Surgical approach	Complication
			Preop.	Postop.					
1	42 M	L	0	0	Lumbar pain	24	3	P	
2	50 F	L	0	0	Lumbar and right leg pain	2	4	EF	
3	44 F	L	1	0	Lumbar and left leg pain	4	4	EF	
4	48 F	C	0	0	Neck and right arm pain, paraparesis in right arm	1	3	P	
5	52 F	T	0	0	Back pain, coughing	48	5	EF	Local infection
6	59 F	L	0	0	Lumbar and right leg pain	2	4	EF	
7	42 F	CT	1	0	Left arm pain and paraparesis in left arm	2	5	P	
8	32 F	Sc	1	0	Lumbar and abdominal pain	36	5	Ant TA + P	CSF leak
9	70 F	L	0	0	Lumbar pain	24	5	RP	
10	33 F	L	1	0	Lumbar pain	24	5	EF + P	
11	35 F	TL	1	0	Lumbar and back pain	12	4	P	
12	52 F	Sc	1	0	Sacral pain	3	5	Ant TA + P	Local infection
13	64 F	L	1	1	Lumbar and back pain	6	5	EF	
14	35 F	TL	0	0	Lumbar and back pain	12	3	EF	
15	44 M	T	1	0	Back pain	24	5	EF + P	
16	59 M	Sc	1	0	Sacral pain	3	5	P	
17	62 F	Sc	0	0	Pain in hip area	12	5	P	
18	16 M	TL	0	0	Back and lumbar pain	8	5	EF	

F - female, M - male, EF - extraforaminal approach, P - posterior approach, Ant TA - anterior transabdominal approach, RP - retroperitoneal approach, Cervical CT - cervicothoracic, L - lumbar, T - thoracic, TL - thoracolumbar, Sc - sacral

**Table 2** - Distribution of GSSs across the spinal levels according to Sridhar's classification.

Spinal level	Sridhar classification					Total
	Type I	Type II	Type III	Type IVb	Type V	
Cervical + cervicothoracic junction			1		1	2
Thoracic + thoracolumbar junction			1	1	3	5
Lumbar			1	4	3	8
Sacral					3	3

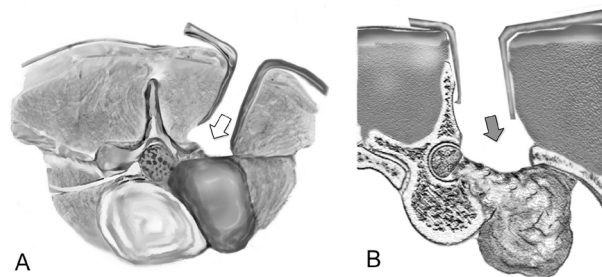
remaining portions of the tumor were excised using a posterior midline line approach. Tumor excisions were performed under a microscope in all cases. Total tumor excision was achieved in all cases.

**Functional results.** Preoperative assessments revealed that 9 patients were classified as Nurick 0, and 9 patients were classified as Nurick 1. Postoperative assessments revealed improvements in the Nurick scores of 8 cases. The Nurick score of one case did not change (Table 3). The constipation complaints from the patients with sacral localizations were alleviated in the early postoperative period, and the urinary complaints were

resolved approximately 2 months later. Similarly, the paraparesis and radicular symptoms of the 2 cervical and thoracic GSS cases were resolved in the postoperative period.

**Complications.** Surgery site infections were observed in 2 cases, and CSF leakage was observed in one case. The patients who experienced infection and CSF leakage were medically treated with bed rest and proper antibiotic therapy.

**Histopathological analysis.** Histopathological analysis of the tumors revealed a benign schwannoma in all cases. No malignance occurred in any cases.



**Figure 1** - Illustration of the lumbar extraforaminal and thoracic foraminal approach for resection of giant spinal schwannomas A) Lumbar extraforaminal approach for extraforaminal giant tumors (white arrow). B) The posterior approach was used for the thoracic foraminal cases in which rib head resection and hemilaminectomy were performed to reach the foraminal area (black arrow).

**Table 3** - Comparison of studies that have examined giant spinal schwannoma cases in the literature.

Literature	No. of cases	Localization	Complications
Correa et al, 2013 <sup>11</sup>	1	Thoracic	-
Çağlı et al, 2012 <sup>10</sup>	13	Sacral	L5 nerve root injury, CSF leak, sphincter disturbance, iliac vein injury
Kagaya et al, 2000 <sup>12</sup>	1	Cauda equina	Temporary loss of motor function
Ogosa et al, 2001 <sup>13</sup>	1	Sacral	Temporary sciatic weakness
Özdemir et al, 2010 <sup>14</sup>	6	All levels	Three instability cases
Sridhar et al, 2001 <sup>4</sup>	10	All levels	Fusion applied to all patients, one patient exhibited CSF leak
Yu et al, 2012 <sup>15</sup>	14	All levels	Four recurrences, 2 instability cases
Current study	18	All levels	2 CSF leaks, 2 local infections

GSS - giant spinal schwannoma, L - lumbar, CSF - cerebrospinal fluid

**Tumor recurrence and follow-up.** The cases were followed postoperatively for an average of 38.5 months (range: 20-68). All patients were examined in an outpatient clinic at 6-monthly intervals. The MR imaging revealed that no relapses occurred in any case during the follow-up period.

**Discussion.** Nerve sheath tumors originate from the transition section (Obersteiner-Redlich section) of the nerve root where the oligodendrocytes transform into Schwann cells. Schwannomas most frequently develop from the dorsal roots and are generally located intradurally and extramedullary.<sup>1,6</sup> However, nerve sheath tumors

can extend to the foraminal and extraforaminal areas, and can also be extradural. Schwannomas are tumors with benign capsules that originate from single nerve fascicles that display progressive growth characteristics that do not comprise other fascicles. Schwannomas can be observed sporadically or in association with NF-2, schwannomatosis or Carney complexes.<sup>7,8</sup>

The incidence of spinal schwannomas is approximately 0.3-0.4 per 100,000 people.<sup>9</sup> The SSSs are most frequently observed in the lumbar and cervical areas. Currently, the frequent use of MRI has increased the incidence of spinal tumors. Specifically, lesions localized in the lumbar and cervical zones can be detected before any clinical presentation. The SSSs can grow to giant sizes as they produce late clinical signs and symptoms following extension through the neuro foramen. There is no clear data in the literature regarding the frequency of GSSs.<sup>2,6</sup> A large portion of the published studies is composed of case reports, and the numbers of cases in case series are well below 20 (Table 3).<sup>4,10-15</sup>

One hundred and seventeen primary spinal cord tumors were observed in our clinic between January 2008 and December 2013. Thirty percent of these cases were formed by spinal schwannomas, and 18 (60%) cases were classified as types III, IV, or V in the Sridhar classification (Table 1) (Figures 2 & 3). In our clinic, the rate of GSSs was relatively high compared with the overall rate of SSSs, which is because these types of cases are referred to our clinic. Although most of the reported case presentations and case series were comprised of sacral GSS, a review of the related literature revealed that many GSS cases are located in the lumbar spine; indeed, 60-70% of GSSs have been reported to be lumbar by other studies.<sup>10,13-18</sup> High rates of cervical GSSs have only been reported by Kim et al<sup>19</sup> and Özdemir et al,<sup>14</sup> who found rates of 50-55% in their series. In our series, most of the GSSs were located in the lumbosacral area (11 cases; 61.1%).

Many factors may affect the clinical presentations of spinal schwannomas, such as the location, level, and extension of the tumor, and the duration of compression. Large tumors can compress both neural and adjacent organs. Extraforaminal thoracic GSSs can compress the lungs and vascular structures, and lumbosacral GSSs can compress abdominal and visceral structures resulting in urination problems and constipation.<sup>10,13,19</sup> Furthermore, GSSs that are located in the cauda equina can cause vertebral erosion that results in instability pain.<sup>11-13,20</sup>

The most frequently observed complaints in our trial were low back pain and radicular symptoms. Paraparesis

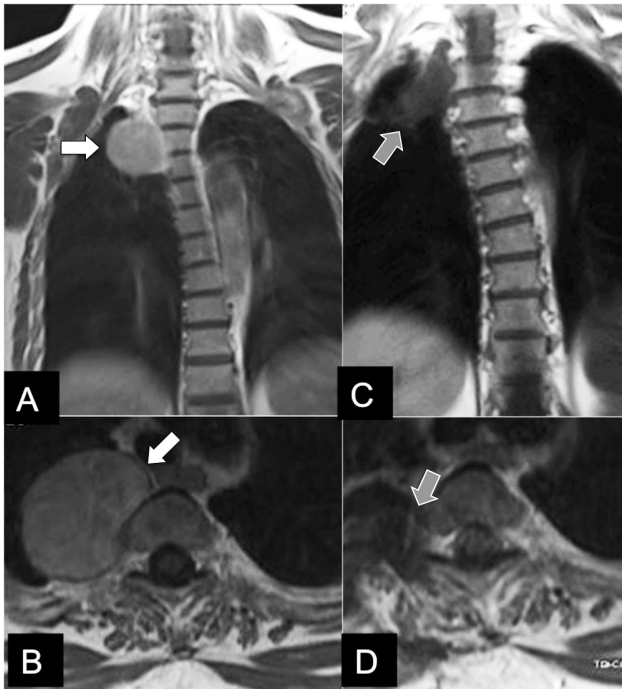


was observed in 2 cases with cervical localizations, and one patient with a Th4 localization growing toward the inside of the thorax. Neurological assessments revealed improvement in 8 of 9 cases. No change occurred in the score of one case, but the preoperative score of this case was one.

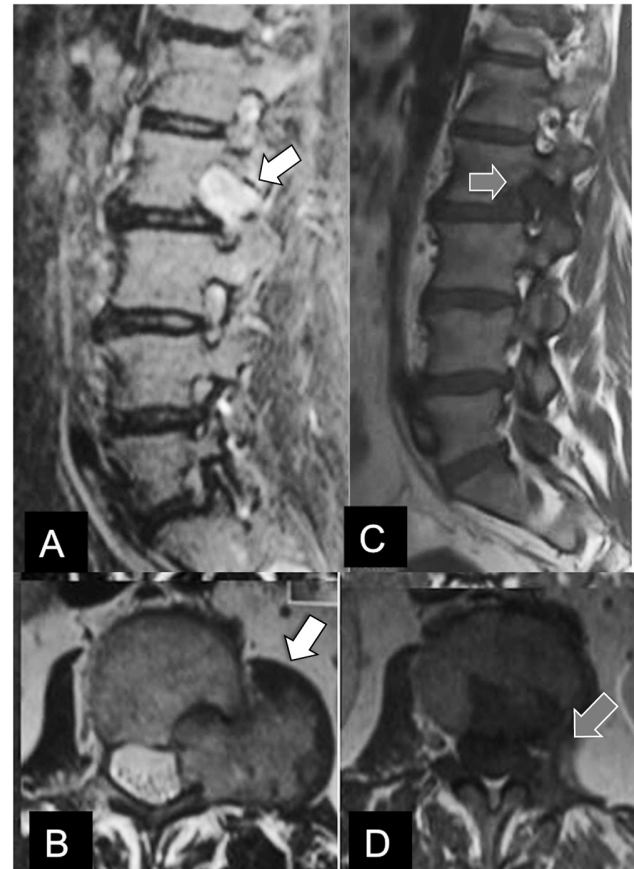
Radiologically, GSSs are isointense (75%) on T1- and hyperintense on T2-weighted MR sequences. Unlike classic schwannomas, cystic and necrotic zones may be observed in GSSs. In such cases, preoperative diagnoses should be supported with percutaneous biopsies. Preoperative diagnostic biopsies were performed in 2 of the cases in the present study. Cystic components were detected in 3 (17.6%) cases on MR imaging, and bone destruction was observed in 9 (52.9%) cases. Another issue that should receive attention during diagnosis is that intracranial schwannomas are likely to accompany spinal schwannomas. Therefore, complete spinal and cranial MRs were performed for all cases in this series.

**Surgical indication and surgical approach.** Surgery is the treatment of choice for GSSs. The selection of the surgical approach varies according to the location and extension of the GSS. In sacrally localized

tumors, anterior and/or posterior surgery can be applied depending on the intra-pelvic or intra-sacral compartment of the tumor. Similarly, in thoracic and lumbar GSSs, the tumors generally exhibit enlargement in the spinal foramen and growth in the anterior direction. Anterior surgery is a safe method for controlling vascular plexuses and other anatomical structures. Particularly for intra-pelvic GSSs that are localized in the sacral area, the iliac artery might be adherent to the vein, ureter, and rectum. In such cases, the portion of the tumor inside the sacrum erodes the sacrum. Such cases require a posterior, and anterior approach to resect all parts of the tumor.<sup>2,6,21</sup> The close relationship between the tumor and iliac arteries, veins, and colorectum should be kept in mind, and surgeons should be well prepared for any complication. Therefore, a colorectal surgeon or gynecologist rather than a general



**Figure 2** - Thoracic giant spinal schwannoma A) Preoperative coronal T1 weighted with contrast MR images and B) preoperative axial T1 weighted with contrast of case 5 (white arrows). C) Postoperative coronal T1 weighted with contrast images and D) axial T1 weighted with contrast of case 5 who underwent an extraforaminal approach for tumor excision (gray arrows).



**Figure 3** - Lumbar giant spinal schwannoma A) Preoperative sagittal T2 weighted with contrast and B) axial T2 weighted MR images of case 13 (white arrows). C) Postoperative sagittal T1 weighted with contrast, and D) axial T1 weighted with contrast MR images of case 13 who underwent posterior approach for tumor excision (gray arrows).

surgeon should conduct presacral exploration. The extraforaminal approach is an alternative to the anterior and posterior approaches for all types of pathology and interventions within the foraminal, paraforaminal, and extraforaminal areas. This approach, which can be used in tumors that grow extraforaminally in the lumbar, thoracic, and cervical zones, is a safe approach that can be applied by spine surgeons and does not require the support of other surgical disciplines.

In these cases, there was already an enlarged intervertebral foramen. Hence, enlarging the foramen was not needed in most of the cases. The surgeon could initially expose the tumor and distal end of the nerve root. After opening the tumor sheath and enucleation, the proximal end of the nerve root became visible. In all the cases, the tumor was successfully removed, and there was no need to sacrifice the nerve root. The foraminal and extraforaminal GSSs between the transverse processes were easy to reach following a vertical incision 4-5 cm lateral to the middle line. This same method can be applied safely with a rib resection in the thoracic zone. With this technique, the lateral surfaces of the revealed nerve root, foramen, and dura can be reached easily.

This approach can be combined with a posterior approach in cases in which the tumor has both extraforaminal and intraspinal compartments. In such cases, a combined intervention that involves 2 separate fascia incisions, one closer to the midline and the other at approximately 3-4 cm lateral to the midline and a single skin incision one cm lateral of the middle line can be performed. A second alternative approach for these tumors with intracanal extensions is the far lateral approach, which employs a skin incision that is 6-8 cm lateral to the midline. In our study, a pure extraforaminal approach was applied in 7 cases (5 lumbar, 2 thoracic) and a combined extraforaminal and posterior approach from the single incision was applied in 2 cases.

The anterolateral retroperitoneal method was applied only in one case in the current series. As in the posterolateral approach, the proximal end of the nerve root cannot be seen until resecting the tumor during this approach. Careful exposure and dissection of the tumor and surrounding structures are critical to avoid injury to the peritoneal and retroperitoneal structures. Therefore, an access surgeon familiar with this area (for example, general surgeon, or urologist) should carry out this operation.

In GSS surgery, several complications can develop depending on the tumor's localization and size. Complications such as infection, pulmonary emboli, neurologic damage, CSF fistula, vascular injuries, instability, and ureter and rectum injury have been

reported in the literature.<sup>22,23</sup> Complication rates increase as the size of the total excised tumor increases. Neurological deficits following total excision of the cauda equina and sacral GSSs were observed in 12 of 24 cases,<sup>10,22-26</sup> while neurological deficits were observed in only 2 of the 26 cases who underwent subtotal excision.<sup>3,10,27-29</sup>

Bone destruction due to tumor invasion and/or the resection of bone tissue during surgery is an important reason for postoperative instability. The need for intraoperative instrumentation might arise in cases with obvious preoperative instability. The biggest handicap of this technique is that it is more difficult to follow-up these cases due to the appearance of metal artifacts on postoperative MRIs. Therefore, most surgeons refrain from applying implants in these cases.<sup>3,12,25,28,30</sup>

In our study, local surgery site infections were observed in 2 cases, and a CSF fistula was observed in one case. Primary or iatrogenic instability did not develop in our cases. The tumor tissues were excised in single sessions, with the exception of 2 cases with sacral tumors. Postoperative residues were not observed in our cases, and radiological recurrence was not determined on the follow-up.

In conclusion, spinal schwannomas are benign tumors that originate from the nerve sheath and tend to grow toward the outside of the vertebra from the neural foramen, and this growth is accompanied by bone expansion. Spinal schwannomas can easily reach giant sizes in the extraforaminal area and can require complex surgical planning. The most important aim of such surgical treatments should be the total excision of the tumor with minimum damage. To this end, the tumor should be excised using the most appropriate approach. The approach can be tailored based on the tumor's size, location, and extension. Giant spinal schwannomas may enlarge towards neighbor vascular and visceral organs into abdominal and thorax regions. Therefore, surgical operations need planning through multidisciplinary approaches and proper methods should be chosen accordingly. In some cases surgically, a simple intralaminar excision is an appropriate choice.

## References

1. Hirano K, Imagama S, Sato K, Kato F, Yukawa Y, Yoshihara H, et al. Primary spinal cord tumors: review of 678 surgically treated patients in Japan. A multicenter study. *Eur Spine J* 2012; 21: 2019-2026.
2. Choe WJ, Chung CK, Cho BK. Spinal Cord Tumors: An Analysis of 654 Cases (1973-1999). *J Korean Neurosurg Soc* 2001; 30: 1004-1012.
3. Kogame M, Yamamoto T, Harada N. Spinal destructive change due to neurofibroma of cauda equina. A report of three cases. *Cent Jpn J Orthop Traumatol* 1985; 28: 705-707.

4. Sridhar K, Ramamurthi R, Vasudevan MC, Ramamurthi B. Giant invasive spinal schwannomas: definition and surgical management. *J Neurosurg* 2001; 94: 210-215.
5. Nurick S. The pathogenesis of the spinal cord disorder associated with cervical spondylosis. *Brain* 1972; 95: 87-100.
6. Conti P, Pansini G, Mouchaty H, Capuano C, Conti R. Spinal neurinomas: retrospective analysis and long-term outcome of 179 consecutively operated cases and review of the literature. *Surg Neurol* 2004; 61: 34-43; discussion 44.
7. Asthagiri AR, Parry DM, Butman JA, Kim HJ, Tsilou ET, Zhuang Z, et al. Neurofibromatosis type 2. *Lancet* 2009; 373: 1974-1986.
8. Watson JC, Stratakis CA, Bryant-Greenwood PK, Koch CA, Kirschner LS, Nguyen T, et al. Neurosurgical implications of Carney complex. *J Neurosurg* 2000; 92: 413-418.
9. Seppälä MT, Haltia MJ, Sankila RJ, Jääskeläinen JE, Heiskanen O. Long-term outcome after removal of spinal neurofibroma. *J Neurosurg* 1995; 82: 572-577.
10. Çağlı S, İşik HS, Yıldırım U, Akıntürk N, Zileli M. Giant sacral schwannomas. *J Neurooncol* 2012; 110: 105-110.
11. Rubio Correa I, Monje F, González-García R, Villanueva-Alcojol L. Lateral cervical approach combined with posterior thoracotomy for the treatment of giant neurilemmoma of the chest involving the neck. *J Oral Maxillofac Surg* 2013; 71: 433-436.
12. Kagaya H, Abe E, Sato K, Shimada Y, Kimura A. Giant cauda equina schwannoma. A case report. *Spine (Phila Pa 1976)* 2000; 25: 268-272.
13. Ogosa A, Hotta T, Sato S, Takano R, Higuchi T. Presacral schwannoma with purely cystic form. *Spine (Phila Pa 1976)* 2001; 26: 1817-1819.
14. Ozdemir N, Bezircioğlu H, Akar O. Giant erosive spinal schwannomas: surgical management. *Br J Neurosurg* 2010; 24: 526-531.
15. Yu NH, Lee SE, Jahng TA, Chung CK. Giant invasive spinal schwannoma: its clinical features and surgical management. *Neurosurgery* 2012; 71: 58-66.
16. Pongsthorn C, Ozawa H, Aizawa T, Kusakabe T, Nakamura T, Itoi E. Giant sacral schwannoma: a report of six cases. *Ups J Med Sci* 2010; 115: 146-152.
17. Bhatia S, Khosla A, Dhir R, Bhatia R, Banerji AK. Giant lumbosacral nerve sheath tumors. *Surg Neurol* 1992; 37: 118-122.
18. Salvant JB Jr, Young HF. Giant intrasacral schwannoma: an unusual cause of lumbosacral radiculopathy. *Surg Neurol* 1994; 41: 411-413.
19. Kim CH, Chung CK. Surgical outcome of a posterior approach for large ventral intradural extramedullary spinal cord tumors. *Spine (Phila Pa 1976)* 2011; 36: E531-E537.
20. O'Brien DF, Farrell M, Fraher JP, Bolger C. Schwann cell invasion of the conus medullaris: case report. *Eur Spine J* 2003; 12: 328-331.
21. Payer M, Radovanovic I, Jost G. Resection of thoracic dumbbell neurinomas: single postero-lateral approach or combined posterior and transthoracic approach? *J Clin Neurosci* 2006; 13: 690-693.
22. Lesoin F, Krivosic I, Cama A, Jomin M. A giant intrasacral schwannoma revealed by lumbosacral pain. *Neurochirurgia (Stuttg)* 1984; 27: 23-24.
23. Rengachary SS, O'Boynick P, Batnitzky S, Kepes JJ. Giant intrasacral Schwannoma: case report. *Neurosurgery* 1981; 9: 573-577.
24. Türk PS, Peters N, Libbey NP, Wanebo HJ. Diagnosis and management of giant intrasacral schwannoma. *Cancer* 1992; 70: 2650-2657.
25. Dickson JH, Waltz TA, Fechner RE. Intraosseous neurilemmoma of the third lumbar vertebra. *J Bone Joint Surg* 1971; 53:349-355.
26. Santi MD, Mitsunaga MM, Lockett JL. Total sacrectomy for a giant sacral schwannoma. A case report. *Clin Orthop* 1993; 294: 285-289.
27. Fearnside MR, Adams CB. Tumours of the cauda equina. *J Neurol Neurosurg Psychiatry* 1978; 41: 24-31.
28. Enomoto A, Okuzumi S, Omibuchi N. Intradural neurinoma of the cauda equina accompanied with severe destruction of the spine: A report of three cases. *East Jpn J Clin Orthop* 1991; 3: 506-508.
29. Yone K, Sakou T, Tomimura K. Giant-sized tumors in the cauda equina. A report of four cases. *J West Jpn Orthop Traumatol* 1986; 34: 897-900.
30. Shirasaki N, Fuji T, Kurato S, Kubo M, Kawai S. Spinal reconstruction following resection of a giant cauda equina schwannoma. *Rinsho Seikei Geka* 1988; 23: 651-656.

## NEW PEER REVIEWERS

Join our team of expert peer reviewers for the Neurosciences Journal by sending an enquiry and summarized CV to [info@smj.org.sa](mailto:info@smj.org.sa). Note that NSJ reviewers, whose reviews are returned on time and are judged satisfactory by the Editors, may receive 1 CME credit per review, with a maximum of 5 credits per year, from the Saudi Council for Health Specialties.