

# Endovascular treatment of a traumatic dural arteriovenous fistula of the superior sagittal sinus using dual lumen balloon microcatheter

Yihao Tao, MD, Yin Niu, MD, Gang Zhu, MD, PhD, Zhi Chen, MD.

## ABSTRACT

الناسور الشرياني الوريدي الجافية (DAVFs) الناجم عن صدمة في الجيب السهمي العلوي (SSS) هو حالة نادرة ويصعب علاجها بسبب موقعها الفريد في خط الوسط، تعدد مغذيات الشرايين، والتصريف الوريدي المستحكم. نعرض تقريراً عن أدائنا الناجح في علاج باطن الأوعية الدموية باستخدام بالون التجويف المزدوج microcatheter على المريض بعد الصدمة SSS DAVF. وباستخدام عصا بالون التجويف المزدوج microcatheter، منعنا Onyx reflux DAVFs. في هذه الحالة، تحقق الانصمام الكامل للـ DAVFs وكانت نتيجة علاج المريض جيدة إلى حد ما.

Dural arteriovenous fistula (DAVFs) induced by trauma in the superior sagittal sinus (SSS) are rare and difficult to treat because of their unique midline location, multiplicity of arterial feeders, and critical venous drainage. We report a case of an endovascular treatment using dual lumen balloon microcatheter on a patient with post-traumatic SSS DAVF. By the use of dual lumen Scepter balloon microcatheter, proximal Onyx reflux was prevented. In this case, complete embolization of the DAVFs was achieved and the outcome of the patient was fairly good.

*Neuroscience 2016; Vol. 21 (2): 158-160*

*doi: 10.17712/nsj.2016.2.20150331*

*From the Department of Neurosurgery, Southwest Hospital, Third Military Medical University, Chongqing, China.*

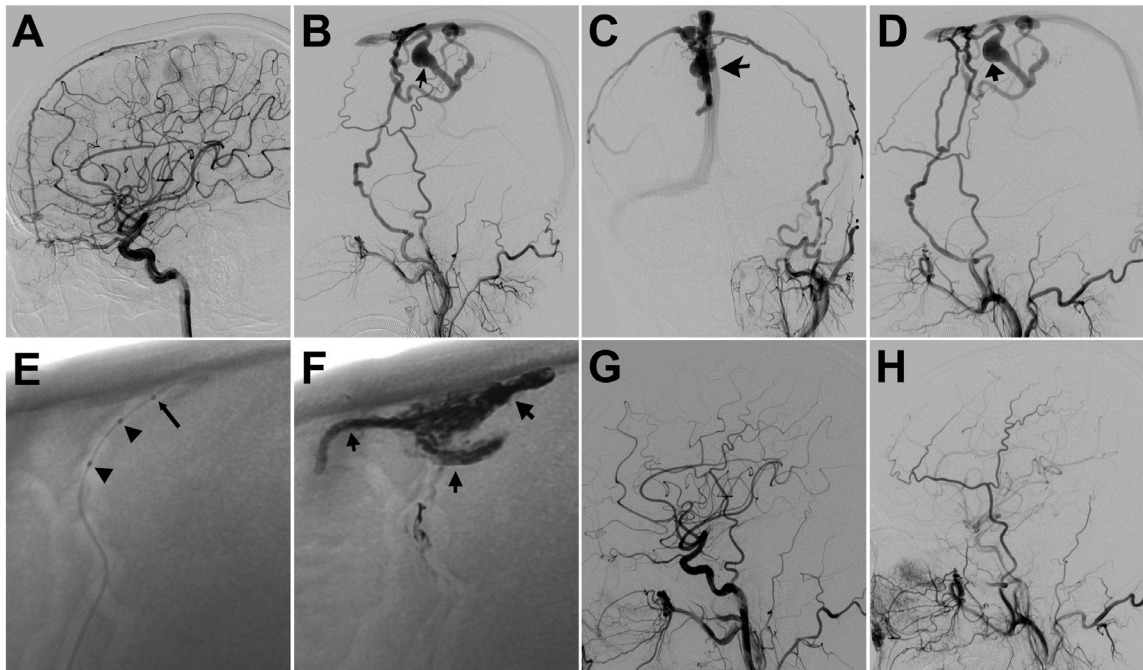
*Received 12th May 2015. Accepted 21st October 2015.*

*Address correspondence and reprint request to: Dr. Zhi Chen, Associate Professor, Department of Neurosurgery, Southwest Hospital, Third Military Medical University, Chongqing, Republic of China. E-mail: zhichen@tmmu.edu.cn*

It has been reported that dural arteriovenous fistula (DAVFs) could be induced by trauma, which frequently have severe neurologic consequences including hemorrhage, intracranial hypertension, focal deficits, and seizures. Post-traumatic DAVFs of the superior sagittal sinus (SSS) are rare and difficult to treat because of their unique midline location, multiplicity of arterial feeders, and critical venous drainage. All kinds of approaches including endovascular embolization with Onyx or liquid adhesives, surgical techniques, and combined surgical and endovascular therapy have been performed to close fistulas completely.<sup>1-3</sup> Scepter C is a dual lumen polyurethane balloon catheter, which allows for balloon inflation and Onyx injection via 2 different lumens.<sup>4</sup> It enormously eliminates the risk of Onyx reflux.<sup>1,5</sup> Hereby, an effective and minimally invasive method of occluding a rare fistula by transarterial embolization was reported. The reason for presenting this case is to present a novel and effective method for the treatment of DAVF.

**Case Report.** A 36-year-old man with repeatedly paroxysmal headache was admitted to our hospital. The patient suffered a severe head trauma in a car accident 21 days prior to the accident. He was admitted to hospital with periorbital soft tissue swelling, CT scanning revealed a skull fracture in SSS area. Before he was transferred to our hospital, Computerized tomographic angiography (CTA) revealed vascular malformation and venous congestion of the SSS, which was considered to be secondary to the trauma. Neurological examination revealed no abnormalities. Left internal carotid artery angiogram revealed a DAVF supplied by the anterior falx artery (Figure 1A). Left lateral (Figure 1B), anteroposterior (Figure 1C) and right lateral (Figure 1D) view of left external carotid artery (ECA) angiogram showed the SSS DAVF with bilateral cortical venous reflux.

Embolization of the DAVF was performed under general anesthesia. A Scepter C balloon catheter (4×15



**Figure 1** - Endovascular treatment for a patient with posttraumatic dural arteriovenous fistula (DAVF) of the superior sagittal sinus (SSS). A) Left internal carotid artery angiogram before embolization showing the DAVF supplied by the anterior falx artery; B, C and D) Lateral (B&D) and anteroposterior (C) view of left external carotid artery (ECA) angiogram before embolization showing the DAVF of SSS with bilateral cortical venous reflux; E) Unsubtracted image showing the Scepter balloon catheter navigated close to the fistulous point for Onyx injection (arrow head indicating the balloon markers, arrow indicating the distal tip); F) Unsubtracted image showing the Onyx cast extending to the proximal draining vein after embolization; G) Post-embolization angiogram of the left common carotid artery showing complete disappearance of the fistula. H) Post-embolization angiogram of the right ECA showing complete disappearance of the fistula.

mm, MicroVention, Tustin, California, USA) was placed at the most distal segment of the left middle meningeal artery (MMA) and contrast medium was injected into the balloon. Unsubtracted image showed the Scepter balloon catheter navigated close to the fistulous point for Onyx injection (Figure 1E). In order to occlude any residual fistula, Onyx-18 (eV3, Irvine, California, USA) was then injected through the dual lumen balloon catheter positioned in one branch of the MMA. Unsubtracted image showed the Onyx cast extending to the proximal draining vein after embolization (Figure 1F). With the balloon inflated, a total of 1.2 ml of Onyx-18 was delivered with thorough penetration into the malformation slowly, after which, angiogram of both the left common carotid artery and

the right external carotid artery (ECA) showed complete disappearance of the fistula (Figures 1G-H). The balloon was deflated by syringe suction without difficulty. At the end of the procedure, the catheter was removed under constant aspiration without any noticeable adherence to the Onyx cast. Procedure related complications were not observed. At 6 months follow-up, it revealed complete occlusion of the lesion.

**Discussion.** Dural arteriovenous fistula account for 10%–15% of intracranial arteriovenous malformations.<sup>6</sup> DAVFs in SSS are extremely rare. A small percentage of patients have a history of previous trauma, they have been well reported.<sup>7</sup> The common characteristic of DAVFs happened when a patient suffered skull fracture, or other trauma, not long after a head injury with progressive symptoms such as, exophthalmos, swelling of the eyelids, bruit, and so forth. This scenario most likely accounts for the findings in our patient, and we believe that his DAVFs probably were secondary to the head injury rather than a congenital anomaly. So far, the first-line treatment for DAVFs is embolization

**Disclosure.** Authors have no conflict of interests, and the work was not supported or funded by any drug company.

by using transarterial, transvenous, or occasionally, combined approaches.<sup>1-8</sup> This approach proved to be effective comparable with DAVF obliteration in preventing neurologic morbidity with lower levels of procedural risk. The optimal method of endovascular treatment remains debated and controversial. The use of Onyx has been increasingly reported for the treatment of DAVFs.<sup>2-10</sup> Using reflux as a plug, operator creates a forward flow of Onyx, which is called the “plug and push technique.” The dual lumen balloon microcatheter served a dual purpose: the Onyx-18 injection was allowed through the dual lumen balloon catheter and a mechanical barrier was provided to prevent the Onyx reflux at the same time. This technique is an option during extracranial embolic embolization in a few select cases.

In this case, a patient with a post-traumatic DAVF of the SSS was effectively treated. It is appropriate to select a dual lumen balloon microcatheter for complex dural arteriovenous fistulas. Using a dual lumen balloon microcatheter helps prevent Onyx reflux and improves its penetration during Onyx embolization of DAVFs. Thus, this is a feasible and effective alternative approach for the management of post-traumatic DAVFs.

## References

- Jagadeesan BD, Grigoryan M, Hassan AE, Grande AW, Tummala RP. Endovascular Balloon-assisted embolization of intracranial and cervical arteriovenous malformations using dual lumen co-axial balloon microcatheters and onyx: Initial Experience. *Neurosurgery* 2013.
- Gonzalez LF, Chalouhi N, Tjoumakaris S, Jabbour P, Dumont AS, Rosenwasser RH. Treatment of carotid-cavernous fistulas using intraarterial balloon assistance: case series and technical note. *Neurosurgical Focus* 2012; 32: E14.
- Dabus G, Linfante I, Martinez-Galdamez M. Endovascular treatment of dural arteriovenous fistulas using dual lumen balloon microcatheter: technical aspects and results. *Clinical Neurology and Neurosurgery* 2014; 117: 22-27.
- Kim ST, Jeong HW, Seo J. Onyx embolization of dural arteriovenous fistula, using scepter C balloon catheter: a Case Report. *Neurointervention* 2013; 8: 110-114.
- Orozco LD, Luzardo GD, Bucicuc RF. Transarterial balloon assisted Onyx embolization of pericallosal arteriovenous malformations. *J Neurointerv Surg* 2013; 5: e18.
- Gandhi D, Chen J, Pearl M, Huang J, Gemmete JJ, Kathuria S. Intracranial dural arteriovenous fistulas: classification, imaging findings, and treatment. *AJNR Am J Neuroradiol* 2012; 33: 1007-1013.
- Abla AA, Albuquerque FC, Theodore N, Spetzler RF. Delayed presentation of traumatic cerebral and dural arteriovenous fistulae after a BB gun accident in a pediatric patient: case report. *Neurosurgery* 2011; 68: E1750-E1754.
- Jagadeesan BD, Siddiq F, Grande AW, Tummala RP. Modified balloon assisted coil embolization for the treatment of intracranial and cervical arterial aneurysms using coaxial dual lumen balloon microcatheters: initial experience. *J Neurointerv Surg* 2014; 6: 704-707.
- Spiotta AM, Miranpuri AS, Vargas J, Magarick J, Turner RD, Turk AS, et al. Balloon augmented Onyx embolization utilizing a dual lumen balloon catheter: utility in the treatment of a variety of head and neck lesions. *J Neurointerv Surg* 2014; 6: 547-555.
- Puri AS, Kuhn AL, Hou SY, Wakhloo AK. Use of intermediate guide catheters as an adjunct in extracranial embolization to avoid onyx reflux into the anastomotic vasculature. A technical note. *Interventional Neuroradiology* 2014; 20: 424-427.

## CASE REPORTS

Case reports will only be considered for unusual topics that add something new to the literature. All Case Reports should include at least one figure. Written informed consent for publication must accompany any photograph in which the subject can be identified. Figures should be submitted with a 300 dpi resolution when submitting electronically or printed on high-contrast glossy paper when submitting print copies. The abstract should be unstructured, and the introductory section should always include the objective and reason why the author is presenting this particular case. References should be up to date, preferably not exceeding 15.