

Multiple Choice Questions Section

The Neurosciences Journal includes this section of multiple choice questions as part of its commitment to continuous education and learning in Neurosciences. Experts in various neuroscience specialties are invited to participate with their knowledge and expertise in this section.

Neurology, neurosurgery, and other board residents are encouraged to read this section to improve their knowledge and direct their reading for written examinations.

Discitis in children

Abdulaziz Alghamdi, MD

From the Department of Pediatric, Prince Sultan Military Medical City, Riyadh, Kingdom of Saudi Arabia. E-mail: am_alghamdi@psmmc.med.sa

Choose the most appropriate single answer.

1. This 3-year-old boy complains of progressively unable to walk or sit 4 days prior to presentation. He had no obvious tenderness, but he seemed more irritable while sitting. There was no history of recent trauma, or vaccinations. Review of systems was negative for fever, cough or choking. He had normal bowel motions and there was no change in his voice. On examination, the child was awake and alert. He did not appear in pain. Cranial nerves are intact. He appeared in a frog leg position with decreased tone and little spontaneous movement in both lower limbs. Deep tendon reflexes were +3 bilaterally, and the power in the upper limbs was normal. His anal tone was normal. He would withdraw to tactile stimulation in all extremities. He was unable to weight bear. The possible diagnosis is:
 - a) Acute transverse myelitis
 - b) Guillain-Barre syndrome
 - c) Discitis
 - d) Vertebral fractures
2. To confirm the diagnosis in such case, you need to do:
 - a) Electromyogram and nerve conduction velocity
 - b) Spine plain X-Ray
 - c) Blood cultures
 - d) MRI whole spine
3. The most common organism can be seen in this disease is:
 - a) *Staphylococcus aureus*
 - b) *Escherichia coli*
 - c) *Pseudomonas species*
 - d) *Candida albicans*
4. If you want to treat this child, what you will choose?
 - a) Steroid pulse therapy
 - b) Antistaphylococcal agent and a third-generation cephalosporin
 - c) Intravenous immunoglobulin
 - d) Immobilization

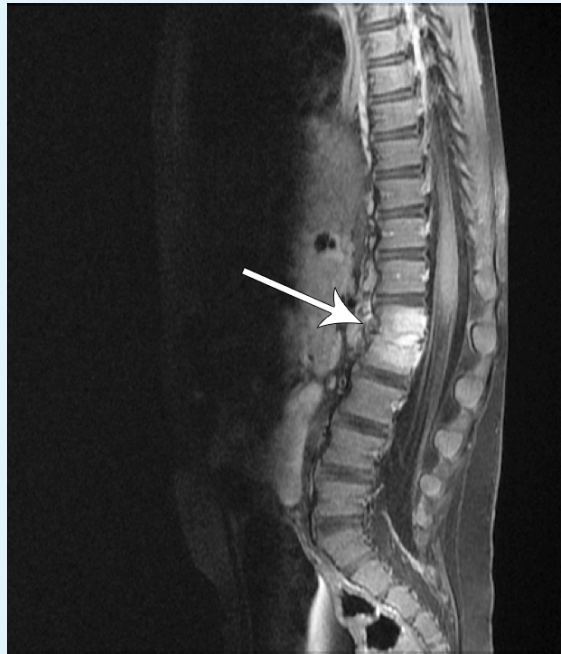


Figure 1 - MRI spine with GAD showed a discitis at L1-2 without significant compromise of the spinal canal, and a very small epidural abscess. GAD - Gadolinium

5. Which one of the following sentences is correct?

- a) Disc biopsy mandatory for the diagnosis
- b) Anomalies of the disc space and adjacent vertebrae are common findings on long-term follow-up.
- c) Erythrocyte sedimentation rate is elevated in < 40% of patients
- d) Management include immobilization and oral antibiotic for 2 weeks

Answers:

1. **c**

Discitis is an inflammation of the intervertebral disc. It is rare in young children and the etiology is controversial. Occurs in children at around 2-5 years of age. They present with irritability and back pain, limp, or refusal to walk. On examination patients may refusal to bend forward or to sit, tenderness over the involved spine. Hip pain and stiffness and decreased power and reflexes can be seen. Most patients have had symptoms around one month before diagnosis made.¹

2. **d**

MRI spine with gadolinium is diagnostic for the disease but it can be normal initially. It can define the inflammation and exclude alternative diagnoses such as vertebral osteomyelitis and tumors.²

3. **a**

Around 60% of organisms that had been isolated when disc biopsy performed was *Staphylococcus aureus*.³

4. **b**

Empiric antibiotic therapy as an antistaphylococcal agent and a third-generation cephalosporin are the preferable choice.⁴

5. **b**

The prognosis is usually good but anomalies of the disc space and adjacent vertebrae are common findings on long-

term follow-up. Erythrocyte sedimentation rate is elevated in more than 90% of patients. No need to do disc biopsy to diagnose children with discitis. Management for discitis in children is different than adult. Antibiotics usage is associated with earlier response and fewer relapses. Initially patient should be started on intravenous antibiotics until the child shows clinical improvement, followed by oral antibiotics. Bed rest, analgesia and immobilization by casting, may help with pain control.⁵

References

1. Fernandez M, Carrol CL, Baker CJ. Discitis and vertebral osteomyelitis in children: an 18-year review. *Pediatrics* 2000; 105: 1299-1304.
2. Houry NJ, Hourani MH, Arabi MM, Abi-Fakher F, Haddad MC. Imaging of back pain in children and adolescents. *Curr Probl Diagn Radiol* 2006; 35: 224-244.
3. Ring D, Johnston CE 2nd, Wenger DR. Pyogenic infectious spondylitis in children: the convergence of discitis and vertebral osteomyelitis. *J Pediatr Orthop* 1995; 15: 652-660.
4. Cushing AH. Diskitis in children. *Clin Infect Dis* 1993; 17: 1-6.
5. Jansen BR, Hart W, Schreuder O. Discitis in childhood. 12-35-year follow-up of 35 patients. *Acta Orthop Scand* 1993; 64: 33-36.

Do you have any comments or questions? Agree or disagree with published articles?

The correspondence section within the journal is a forum to comment on any of the articles published in the journal. Correspondence will not be sent for peer review, and will only be edited for the use of appropriate language. All correspondence should be submitted and published within 6 months from the date of the original publication.

Please submit your correspondence through the journal website (www.neurosciencesjournal.org), and don't forget to clearly state the title of the original publication, and your contact details.