

Is Duplex carotid artery screening prior to CABG justified?

Khawaja B. Waheed, MBBS, FCPS, Faisal M. Alzahrani, MBBS, KFUF, Muhammad N. Sharif, MBBS, FCPS, Nawaf N. Al Jubair, MBBS, SB-RAD, Mona J. Hundallah, GSCE, MBBS, Muhammad S. Amin, MBBS, MCPS, Zechariah J. Arulanantham, MSc, PhD.

ABSTRACT

الأهداف: تقييم استخدام فحص الشريان السباتي المزدوج في المرضى الذين يخضعون لتطعيم مجازة الشريان التاجي (CABG).

الطريقة: أجريت هذه الدراسة الوصفية والرصدية في قسم الأشعة في مجمع الملك فهد الطبي العسكري، الظهران، المملكة العربية السعودية خلال الفترة من أبريل 2015-2018م. تمت مراجعة بأثر رجعي جميع المرضى السعوديين (العدد= 178) الذين خضعوا لموجات فوق صوتية السباتي دوبلكس قبل CABG للحصول على المعلومات المورفولوجية و الدورة الدموية الأساسية لتقدير شدة تضيق الشريان السباتي الداخلي خارج الجمجمة. تم استبعاد المرضى الذين يعانون من CABG وخضعوا لجراحة القلب معاً، والذين لديهم دراسات السباتي محدودة. تم تسجيل التقدم في العمر (65 عاماً أو أكثر)، والجنس، والتدخين، والسمنة، ومرض السكري (DM)، ارتفاع ضغط الدم (HTN)، اختلال مستوى الدهون البروتينية، مرض الأوعية التاجية، أمراض القلب والسكتة الدماغية السابقة. تم تسجيل الحدث العصبي بعد طعم مجازة الشريان التاجي (وهي نوبة نقص التروية العابرة [TIA] أو السكتة الدماغية). تم استخدام اختبار كاي لتحديد ارتباط درجة التضيق بالحدث العصبي بعد CABG.

النتائج: مائة وثمانية وعشرون مريضاً (72%) كانوا يعانون من مرض ICA، في ظهر تضيق الشريان السباتي بشكل كبير (أكثر من 70%) في 11 مريضاً (6.2%). شوهد ما بعد الشريان التاجي تم تسجيل الحدث العصبي بعد طعم مجازة الشريان التاجي في 4.5% من المرضى. وظهر تقدم العمر، تضيق كبير ICA ومرض الشريان التاجي متعدد الأوعية المرتبطة بالحدث بعد CABG.

الخلاصة: أظهرت الدراسة تضيق كبير ICA على الفحص المزدوج في المرضى المسنين الذين يعانون من مرض الشريان التاجي متعدد الأوعية أو بعض عوامل الخطر قد يتنبأ بالسكتة الدماغية بعد CABG.

Objectives: To evaluate the use of duplex carotid artery screening in patients undergoing coronary artery bypass graft (CABG).

Methods: This descriptive, observational study was conducted in Radiology Department at King Fahad Military Medical Complex, Dhahran, Kingdom

of Saudi Arabia from April 2015-2018. All Saudi patients (n=178) who underwent duplex carotid sonography prior to CABG were retrospectively reviewed for essential morphologic and hemodynamic information to estimate severity of extra-cranial internal carotid artery (ICA) stenosis. Patients with combined CABG and cardiac surgery, and those with limited carotid studies were excluded. Advancing age (65 years or above), gender, smoking, obesity, diabetes (DM), hypertension (HTN), dyslipidemia, coronary vessel disease, cardiac disease and previous stroke were recorded. Post-coronary artery bypass graft neurologic event (namely, transient ischemic attack [TIA] or stroke) was recorded. Chi-square test was used to determine association of stenosis degree with post-CABG neurologic event.

Results: One hundred twenty eight patients (72%) were having ICA disease, while significant carotid artery stenosis (>70%) was seen in 11 patients (6.2%). Post-coronary artery bypass graft neurologic event was seen in 4.5% of patients. Advancing age, significant ICA stenosis and multi-vessel coronary disease were seen associated with a post-CABG event.

Conclusion: Significant ICA stenosis on duplex screening in elderly patients with multi-vessel coronary artery disease or certain risk factors may predict post-CABG stroke.

*Neurosciences 2019; Vol. 24 (2): 122-129
doi: 10.17712/nsj.2019.2.20180022*

From the Department of Radiology (Waheed, Al Zahrani, Al Jubair, Hundallah, Amin); from the Department of Cardiology and Cardiac Surgery (Sharif), King Fahad Military Medical Complex, and from the Department of Vice Deanship of Postgraduate Studies and Research (Arulanantham), Prince Sultan Military College of Health Science, Dhahran, Kingdom of Saudi Arabia.

Received 5th November 2018. Accepted 20th February 2019.

*Address correspondence and reprint request to: Dr. Khawaja B. Waheed, Department of Radiology, King Fahad Military Medical Complex, Dhahran, Kingdom of Saudi Arabia. E-mail: Khawaja@kfmmc.med.sa
ORCID ID: <https://orcid.org/0000-0001-6340-3139>*

Coronary artery disease (CAD) is a major worldwide public health problem.¹ The World Health Organization (WHO) estimated that in 2008, out of 17.3 million cardiovascular disease related deaths globally, myocardial infarction was responsible for 7.3 million deaths.² The overall prevalence of CAD in Kingdom of Saudi Arabia is reported to be 5.5%.³ According to the latest WHO data published in May 2014, coronary heart disease deaths in Kingdom of Saudi Arabia reached 24.34% of total deaths. The age adjusted death rate is 165.67 per 100,000 of the population.⁴ Coronary artery bypass surgery or CABG is a surgical procedure opted to relieve uncontrolled angina, prevent or relief left ventricular failure, thereby reducing the risk of death.⁵ Coronary artery bypass graft is used to restore normal blood flow to ischemic myocardium through a CABG across the obstructed coronary artery in patients having advanced CAD.

Stroke is a serious non-cardiac complication of CABG, that occurs in 1.3-2.0% of patients.² In 2015, stroke was the second most frequent cause of death after CAD, accounting for 6.3 million deaths (11% of the total).⁶ The annual incidence of stroke ranged from 27.6-57 per 100,000 in the Gulf countries with ischemic stroke being the most common subtype.^{4,7} In an ischemic stroke, blood supply to brain is impeded, leading to dysfunction or death of the brain tissue in that area. Thrombosis and embolism are main factors contributing to such an event.^{8,9} Thrombosis can occur in a large or a small vessel; large vessel disease involves the common and internal carotid arteries, the vertebral artery, and the Circle of Willis, while the small vessel disease involves smaller arteries within the brain parenchyma itself.

The ICA is the source of more than 75% of strokes related to extracranial large vessel disease.¹⁰ Carotid endarterectomy (CEA) or carotid angioplasty (and stenting) can be used to remove atherosclerotic narrowing or occlusion of the carotid artery. There is an evidence supporting these procedures in selected cases.¹¹ Carotid endarterectomy has been shown to be effective at preventing stroke in selected patients particularly having previous history of stroke.¹² Imaging of ICA stenosis is necessary for any intervention or surgery. Although multiple imaging modalities are available,

carotid duplex scanning has become a method of choice for preliminary investigation to assess presence and severity of CAD, and in particular ICA stenosis.¹³

Screening for carotid artery stenosis has not been proven a useful test in the general population.¹⁴ Studies have shown that extracranial ICA stenosis is a risk factor for perioperative stroke in patients undergoing coronary artery bypass surgery.¹⁵ To avoid possibility of stroke, CEA has been recommended in patients undergoing CABG in a staged or concomitant manner.¹² Although the benefits of CEA remain uncertain, some of these studies reported reductions in stroke rates, promoting the rationale that preoperative screening for carotid stenosis in all CABG patients is necessary to reduce perioperative and long-term stroke rates.⁶ Such non-selective carotid screening does add considerable time, money and expertise to preoperative diagnostic workup. Some investigators have identified risk factors for carotid disease that could be used for more selective screening.⁹ These risk factors include older age, carotid bruit, previous neurological event, previous carotid surgery, peripheral vascular disease (PVD), HTN, DM, dyslipidemia and smoking. Unfortunately, there are neither consensus criteria to provide guidelines to optimize carotid screening practices nor prospective management outcome studies to establish such approach.¹⁶

In this study, we sought to evaluate the results of our routine experience in practicing a non-selective preoperative carotid screening for CABG patients in a 3-year period.

Methods. All (Saudi) patients who had undergone either an elective or emergency CABG alone (N=178) between April 2015-2018, were retrospectively reviewed for demographic and clinical information, risk factors, presence and severity of carotid artery stenosis on duplex (Grey-scale and Doppler) sonography. Patients with combined CABG and cardiac (valve) surgery were excluded. Patients with incomplete, difficult or limited duplex studies were also excluded.

Research protocol was approved from the Hospital Research and Ethic Committee. As the study was retrospective and did not involve disclosure of any patient's information and privacy, the ethics committee of the Hospital waived the need for patient consent. The study was conducted in accordance with the Helsinki Declaration. All clinical and radiologic information were kept strictly confidential. Literature review was performed through electronic search (Google Scholar, PubMed).

Disclosure. Authors have no conflict of interests, and the work was not supported or funded by any drug company.

Demographic information about age and gender of all patients was collected. Clinical information regarding risk factors (advancing age, smoking, obesity, DM, HTN, dyslipidemia, family history of CAD, prior history of stroke or transient ischemic attack) and coronary vessel disease (left mainstem or single-, two-, triple or multi-vessel disease) were acquired through patients' clinical notes and Hospital Information System (HIS).

Age above 65 years was considered 'advancing age'. Body mass index (BMI) was recorded and a value of 30 or above was taken as 'obese', 25-29.9 as 'overweight' while 18.5-24.5 was taken as 'normal' weight. 'Risk profiling' was carried out by identifying single, combined, or other risk factors. Frequently observed co-morbidities (namely, combination of DM, HTN and dyslipidemia) were categorized as 'combined risk' factors. Coronary vessel disease findings were retrieved from the catheter angiography reports (available in patients' records). Coronary catheter angiographies were performed by the cardiologist on a C-arm fluoroscopy Siemens machine (Artis Zee 2010, Germany).

Duplex carotid ultrasounds were requested by the cardiothoracic surgeon and were performed in Radiology department on a properly maintained and calibrated Toshiba machine (Aplio MX 2010, Japan) using a 7.5 MHz linear probe. All ultrasound scans were carried out by a senior sonographer under supervision

of a senior specialist or a consultant. Both grey-scale and doppler images were reviewed (Figure 1), and percentage of ICA stenosis was assessed (Figure 2).

The degree of ICA stenosis was measured considering both morphologic and hemodynamic information. Brightness-mode (B-mode) and color imaging for plaque morphology assessed. North American Symptomatic Carotid Endarterectomy Trial (NASCET) method of grading (that compared diameter of residual lumen at the stenosis with diameter of normal ICA lumen distal to stenosis) was largely used to measure the degree of morphologic stenosis. European Carotid Surgery Trial (ESCT) method was also used in cases where NASCET was difficult to apply (namely, non-visualized or difficult-to-see distal or diseased segment). Peak systolic velocities (PSV) along both ICA and common carotid artery (CCA), along with end-diastolic velocities (EDV) were measured. The degree of ICA stenosis was categorized as mild (0-49%), moderate (50-69%) and severe/significant (70-99%) as per Society of Radiologists in Ultrasound (SRU) criteria.¹⁷ Unilateral or bilateral mild ICA stenosis was labelled as 'Mild', while moderate stenosis was labelled as 'Moderate', and severe stenosis was labelled as 'Severe' disease. 'Mild-moderate' disease was labelled if mild disease was observed on one side and moderate on the left side. In case moderate disease was observed on one side and severe disease on the other side, it was considered as 'severe' disease.

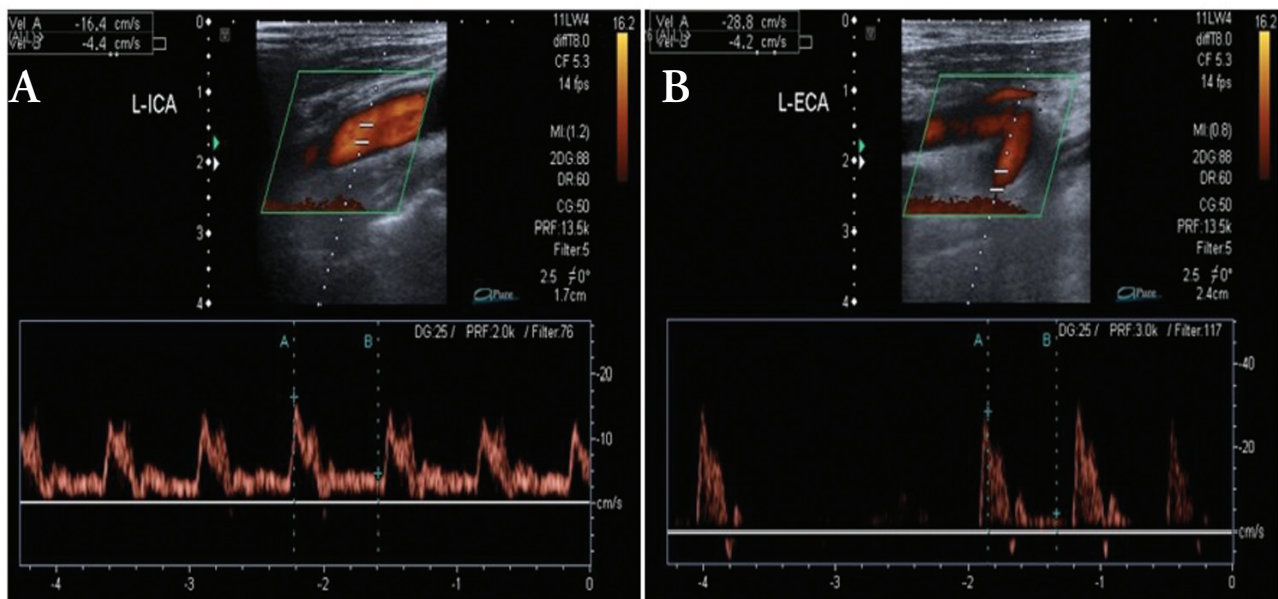


Figure 1 - Normal doppler waveforms of A) internal carotid artery (ICA) (left image) and B) External carotid artery (ECA) (right image).

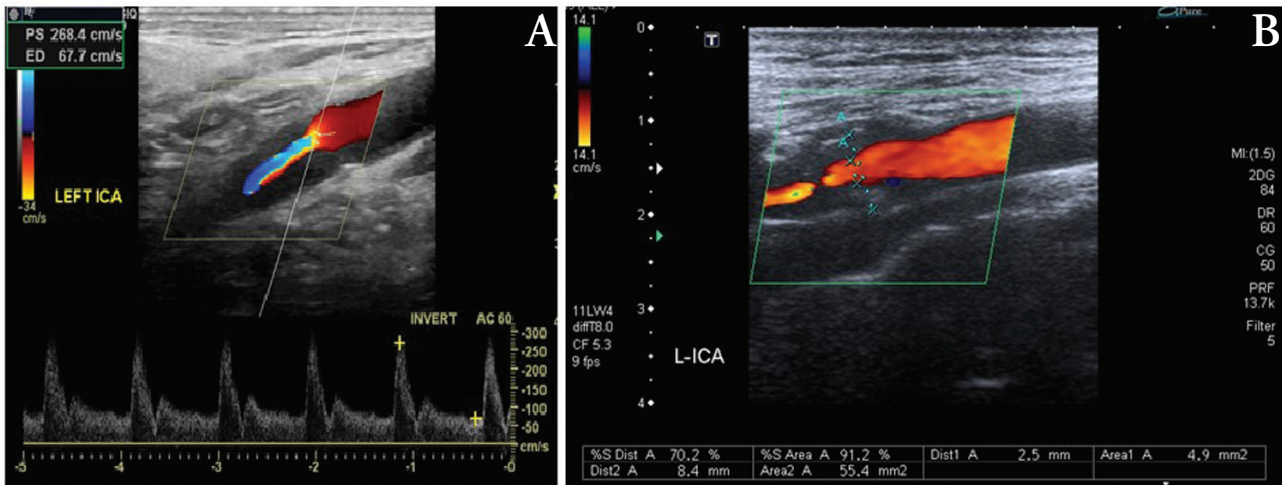


Figure 2 - Duplex and color doppler images of a patient showing A) significant internal carotid artery (ICA) stenosis by velocity and B) degree of luminal stenosis by the European Carotid Surgery Trial (ESCT) method.

Findings of moderate and severe/significant stenosis were confirmed on computed tomography (CT) angiography performed on a 128-slice CT scanner Siemens machine (SOMATOM Definition Flash, Munich, Germany). Distal stenosis along the intracranial (petrous, cavernous) segments were not seen in all of the selected cases. Imaging findings were interpreted by 2 experienced neuroradiologists. Minor discrepancies in doppler results were settled by mutually agreed decision between these 2 radiologists. No major discrepancies were observed.

Post-coronary artery bypass graft neurologic event was taken as positive if patients had any brain imaging (either CT or magnetic resonance imaging [MRI]) performed within the first week of surgery for neurologic complaints or deficits and showing evidence of acute ischemic insult. A clinically suspected transient ischemic attack (TIA) i.e., a mini stroke, mini-stroke lasting for less than 24 hours, was also considered positive, if brain imaging CT was seen negative and other causes like post-surgery delirium and confusion were excluded on neurologic/ psychiatric assessment.

The statistical analysis was carried out using Statistical Package for Social Sciences (SPSS), Version 22 (IBM Corp., Armonk, NY, USA). Chi-square test was used to determine association, and p -values < 0.05 were considered significant.

Results. Out of 178 patients who underwent duplex carotid sonography prior to CABG, 128 patients (72%) were having CAD, and the remaining patients were

having normal studies. Prevalence of significant carotid artery stenosis was measured as 6.2% (Table 1). Eight patients (4.5%) developed post-CABG neurologic complications (either TIA or stroke).

The mean age of the patients was 60 ± 8.9 years (42-77 years), 132 (74%) were males and 46 (25%) were females.

Seventy two patients (40.4%) were having advancing age (65 years and above), and the remaining (106 patients, 60%) were less than 65 years. Advancing age was found to be significantly associated with post-CABG neurologic event (p -value=0.0005), (Table 2). Out of 8 patients who developed post-CABG stroke, 7 were above 65 years of ages and one was under 65 years. Of the stroke patients, one had developed small ipsilateral cortical infarct, one with lacunar infarct along basal ganglia, 4 with ipsilateral frontal or parietal lobe infarcts (2 of these were having territorial infarcts), one with contralateral frontal, and last one with clinical suspicion of TIA/mini-stroke.

One hundred and one patients (56.7%) were smokers and the remaining 77 patients (43.3%) were non-smokers. Smoking was not seen associated with either ICA disease (p -value=0.58) or post-CABG event (p -value=0.29). Obesity was seen to be significantly associated with ICA disease (p -value=0.001) but not with post-CABG event (p -value=0.100). Combined risk factors (namely, combination of DM, HTN, and dyslipidemia) was seen significantly associated with ICA disease (p -value=0.0005) but not with post-CABG neurologic event (p -value=0.57), (Table 3). Multi-vessel

Table 1 - Distribution of duplex sonographic findings. N=178

Doppler findings	n	(%)
Normal	50	(28.1)
Mild	53	(29.8)
Mild-moderate	31	(17.4)
Moderate	33	(18.5)
Significant	11	(6.2)
Total	178	(100.0)

CAD was seen to be significantly associated with both ICA disease (p -value=0.03) and post-CABG event (p -value=0.0005), (Table 4 &5).

Discussion. Our study highlighted important aspects of carotid artery disease assessment by duplex sonography and its clinical implications. Carotid artery disease is considered a surrogate marker for the CAD, and therefore has been routinely investigated in patients prior to CABG surgery,^{18,19} as is practiced in our Hospital.^{18,19} European Society of Cardiology/European Association for Cardio-Thoracic Surgery (ESC/EACTS) Guidelines suggest considering doppler ultrasound screening before CABG in patients with multivessel disease, peripheral artery disease or age more than 70 years (Class IIa, Level C).²⁰ In our study, despite the fact that we had taken advancing age as 65 years and above, this was seen alone to have significant association with a post-CABG neurologic event. Also, we found that combined risk factors (DM, HTN and dyslipidemia) were associated to such events post-surgery. This is interesting because presence of combination of these risk factors was not considered in recommendations for justification of ultrasound screening before CABG surgery.¹⁶ However, we suggest that in patients with advanced age (>65 years) and presence of combined risk factors (DM, HTN and dyslipidemia), screening carotid doppler ultrasound is warranted to avoid or reduce risk of post-CABG neurologic events that could have been more aggravated in case of a concomitant significant carotid artery stenosis detected in these selected patients. Some consider carotid artery disease to be epiphenomenon serving as a marker for diffuse systemic atherosclerotic disease. Although many of risk factors have been associated with CAD like smoking, obesity, multi-vessel disease and family history of heart disease but we could find obesity and multi-vessel disease to be significantly associated with ICA disease.^{3,21} Multi-vessel disease was also found associated with a post-CABG neurologic event. A few studies have

reported carotid bruit, ischemic heart disease, previous history of stroke, atrial fibrillation and cardiomyopathy to be risk factors for stroke in the Saudi population but these were not found associated in our study.⁷ These differences in findings might be related to small sample size or variable regional characteristics.

We found in our study that one patient who developed post-CABG neurologic event was having mild carotid disease. This observation was important, highlighting the fact that there would have been other factors contributing to such events, both intra-operative and post-operative, that should not be over-looked. Various studies have indicated such factors that can lead to neurologic events post-CABG.¹⁹ Masabni et al,¹⁹ reviewed data of different studies and observed that prolonged aortic clamping could contribute towards source of emboli from a diseased aorta. Also, development of hypotension during surgery was also contributory towards stroke in these patients. They also observed that prolonged recovery time from anesthesia might also have contributed towards such events.¹⁹ We therefore suggest that modifying intra-operative techniques and strict post-operative care for hemodynamic stability need to be practiced to minimize such unfortunate events. We did not include patients who were having combined CABG with other cardiac surgery (namely, valve surgery) that could have limited true estimates of a post-surgery event, as reviewed by Masabni et al,¹⁹ showing increased incidence of strokes in patients with dual surgeries possibly resulting from prolonged aortic clamping of diseased aorta or dislodgments of vegetations from diseased valves.

We also observed that in a group of patients (n=91) for whom screening duplex was not used prior to CABG (in same study period), 2 patients developed post-CABG neurologic event (infarcts) and both of these were males, aged more than 65 years, and having DM and HTN. Of noteworthy is that the prevalence of post-CABG neurologic event was seen more (4.5%) in patients with screening than in non-screened group (2.1%) that also favors screening approach to predict strokes. The number of Doppler ultrasound scans can be reduced by restricting screening to certain recommendations criteria, as found in other studies like by Pinho-Gomes A.²⁰ Three patients in our screened group had carotid endarterectomies carried out (2 prior/staged and one concomitant) and did not develop any neurologic event after the surgery that may suggest benefit of prophylactic carotid revascularization prior to CABG to avoid peri-operative stroke.⁶ One patient with prior history of stroke in our study did not develop

Table 2 - Distribution of post-CABG neurologic event and ICA disease in patients aged 65 years and above.

Post-CABG stroke	ICA disease					Total
	Normal	Mild	Mild-moderate	Moderate	Significant	
No	15 (23.1)	17 (26.2)	10 (15.4)	19 (29.2)	4 (6.2)	65 (100.0)
Yes	0 (0.0)	1 (14.3)	0 (0.0)	0 (0.0)	6 (85.7)	7 (100.0)
Total	15 (20.8)	18 (25.0)	10 (13.9)	19 (26.4)	10 (13.9)	72 (100.0)

CABG - coronary artery bypass graft, ICA - internal carotid artery

Table 3 - Distribution of risk factors and ICA disease.

ICA disease	Risk profiling			Total
	Combined risk factors	No associated risk factors	Single or other risk factors	
No	41 (82.0)	8 (16.0)	1 (2.0)	50 (100.0)
Yes	71 (55.5)	7 (5.5)	50 (39.1)	128 (100.0)
Total	112 (62.9)	15 (8.4)	51 (28.7)	178 (100.0)

ICA - internal carotid artery

Table 4 - Distribution of coronary vessel disease and ICA disease.

ICA disease	Coronary Vessel Disease				Total
	1	2	3	Multi	
No	21 (42.0)	21 (42.0)	8 (16.0)	0 (0.0)	50 (100.0)
Yes	30 (23.4)	62 (48.4)	26 (20.3)	10 (7.8)	128 (100.0)
Total	51 (28.7)	83 (46.6)	34 (19.1)	10 (5.6)	178 (100.0)

ICA - internal carotid artery.

Table 5 - Distribution of coronary vessel disease and post-CABG event.

Post-CABG stroke	Coronary vessel disease				Total
	1	2	3	Multi	
No	51 (30.0)	81 (47.6)	31 (18.2)	7 (4.1)	170 (100.0)
Yes	0 (0.0)	2 (25.0)	3 (37.5)	3 (37.5)	8 (100.0)
Total	51 (28.7)	83 (46.6)	34 (19.1)	10 (5.6)	178 (100.0)

CABG - coronary artery bypass graft

any post-CABG events. It should be noted that most of the patients who developed post-operative strokes in our study were having either multi-vessel coronary disease or combined risk factors, highlighting that there could have been other factors in addition to significant ICA stenosis that might have contributed to such events. Naylor,²² demonstrated that 60% of territorial infarctions on CT/autopsy could not be attributed to carotid disease alone.

We mainly adopted NASCET method with velocity for grading carotid artery stenosis in our study, as it has

been shown to correlate well with the actual stenosis found on conventional or CT angiography.^{23,24} However, in cases where NASCET could not be employed due to non-visualization of distal non-diseased ICA lumen, ESCT method was employed by comparing the residual lumen in stenosis with diameter of artery at point of stenosis.²⁵ In such cases where ESCT was used, it was generally undertaken as an overestimation of stenosis, as various earlier trials that showed a stenosis of 70% ECST to be equivalent to a 50% NASCET.²⁴ Most of the patients in our study who were found to have significant ICA stenosis could only be evaluated by ECST. Although this might have an impact on true estimate of stenosis, but it still was not affecting the overall results as those were found to be significant by NASCET when converted (by using equation: ECST%= 0.6NASCET% +40%)²⁴ and even reconfirmed later by CT angiographies. However, further imaging with, further imaging with CT angiography in such patients (with significant stenosis on ESCT) is advocated to avoid any over-estimation that can be linked to such grading method.

We did not include intra-operative or post-operative findings that could have been related to a post-CABG neurologic event; these were considered important limitations in our study. Certain information like hypotension during cardiopulmonary bypass, pulmonary diastolic HTN after cardiopulmonary bypass, manipulation or duration of aortic clamping, atrial fibrillation, prolonged operative time and time of recovery from anesthesia, and hemodynamic parameters could have been considered and would be of interest for future studies particularly prospective

studies to foresee strokes against such parameters. Also, inclusion of combined CABG and other cardiac (valve) surgery patients might provide a useful information about post-surgery outcomes when compared with the CABG-alone surgeries.

The overall findings of our study suggest duplex internal carotid artery screening in patients undergoing CABG particularly for those with advancing age, multi-vessel CAD and certain combined risk factors. The Society of Thoracic Surgeons and the American College of Cardiology/American Heart Association recommend ultrasound screening for carotid artery stenosis only in selected patients (class IIA recommendation, level of evidence C).²⁶ This study supports the Choose Wisely Campaign from the Society of Thoracic Surgeons: 'Don't initiate routine evaluation of carotid artery disease prior to cardiac surgery in the absence of symptoms or other high-risk criteria'.²⁷ Based on our study results, we suggest clinical risk profiling to identify selected patients as a better approach instead of a non-selective duplex screening that seems more logical and cost-effective, avoiding unnecessary examinations. Although only minority of patients may develop stroke post-surgery, it still can have an impact on risk of developing stroke in vulnerable group that might benefit from a revascularization surgery either performed electively before the CABG or concomitantly with the CABG.

In conclusion, significant ICA stenosis on duplex screening in elderly patients with multi-vessel CAD or certain risk factors may predict post-CABG stroke.

Acknowledgements. *The authors gratefully acknowledge Dr. Faisal Al Zahrani for providing his assistance in reviewing the submitted figures for clarity and correctness.*

References

1. WHO. Research for universal health coverage: World health report 2013 [Internet]. World Health Organization; 2013 [8 Oct 2018]. Available from: <https://www.who.int/whr/2013/report/en/>
2. Benjamin EJ, Blaha MJ, Chiuve SE, Cushman M, Das SR, Deo R, et al. Heart Disease and Stroke Statistics-2017 Update: A Report From the American Heart Association. *Circulation* 2017; 135: e146-e603.
3. Al-Nozha MM, Arafah MR, Al-Mazrou YY, Al-Maatouq MA, Khan NB, Khalil MZ, et al. Coronary artery disease in Saudi Arabia. *Saudi Med J* 2004; 25: 1165-1171.
4. Aljefree N, Ahmed F. Prevalence of Cardiovascular Disease and Associated Risk Factors among Adult Population in the Gulf Region: A Systematic Review. *Advances in Public Health* 2015; 2015: 1-23.
5. Sanchis-Gomar F, Perez-Quilis C, Leischik R, Lucia A. Epidemiology of coronary heart disease and acute coronary syndrome. *Ann Transl Med* 2016; 4: 256.
6. Lazar HL, Menzoian JO. Coronary artery bypass grafting in patients with cerebrovascular disease. *Ann Thorac Surg* 1998; 66: 968-974.
7. Robert AA, Zamzami MM. Stroke in Saudi Arabia: a review of the recent literature. *Pan Afr Med J* 2014; 17: 14.
8. LeFevre ML. Screening for asymptomatic carotid artery stenosis: U.S. Preventive Services Task Force recommendation statement. *Ann Intern Med* 2014; 161: 356-362.
9. Högberg D, Dellagrammaticas D, Kragsterman B, Björck M, Wanhainen A. Simplified ultrasound protocol for the exclusion of clinically significant carotid artery stenosis. *Ups J Med Sci* 2016; 121: 165-169.
10. Benjamin EJ, Blaha MJ, Chiuve SE, Cushman M, Das SR, Deo R, et al. Heart disease and stroke statistics 2017 at-a-glance [Internet]. the American Heart Association; 2017 [Accessed 15 May 2017]. Available from: http://www.heart.org/idc/groups/ahamah-public/@wcm/@sop/@smd/documents/downloadable/ucm_491265.pdf
11. Cooper M, Arhuidese IJ, Obeid T, Hicks CW, Canner J, Malas MB. Perioperative and Long-term Outcomes After Carotid Endarterectomy in Hemodialysis Patients. *JAMA Surg* 2016; 151: 947-952.
12. Kernan WN, Ovbiagele B, Black HR, Bravata DM, Chimowitz MI, Ezekowitz MD, et al. Guidelines for the prevention of stroke in patients with stroke and transient ischemic attack: a guideline for healthcare professionals from the American Heart Association/American Stroke Association. *Stroke* 2014; 45: 2160-2236.
13. Högberg D, Kragsterman B, Björck M, Tjärnström J, Wanhainen A. Carotid artery atherosclerosis among 65-year-old Swedish men - a population-based screening study. *Eur J Vasc Endovasc Surg* 2014; 48: 5-10.
14. Henry JC, Kiser D, Satiani B. A Critical Evaluation of Carotid Duplex Scanning in the Diagnosis of Significant Carotid Artery Occlusive Disease. *Advances in Vascular Medicine* 2015; 6.
15. Bonati LH, Dobson J, Featherstone RL, Ederle J, van der Worp HB, de Borst GJ, et al. Long-term outcomes after stenting versus endarterectomy for treatment of symptomatic carotid stenosis: the International Carotid Stenting Study (ICSS) randomised trial. *Lancet* 2015; 385: 529-538.
16. Aboyans V, Ricco JB, Bartelink MEL, Björck M, Brodmann M, Cohnert T, et al. Editor's Choice - 2017 ESC Guidelines on the Diagnosis and Treatment of Peripheral Arterial Diseases, in collaboration with the European Society for Vascular Surgery (ESVS). *Eur J Vasc Endovasc Surg* 2018; 55: 305-368.
17. Grant EG, Benson CB, Moneta GL, Alexandrov AV, Baker JD, Bluth EI, et al. Carotid artery stenosis: grayscale and Doppler ultrasound diagnosis--Society of Radiologists in Ultrasound consensus conference. *Ultrasound Q* 2003; 19: 190-198.
18. Lin JC, Kabbani LS, Peterson EL, Masabni K, Morgan JA, Brooks S, et al. Clinical utility of carotid duplex ultrasound prior to cardiac surgery. *J Vasc Surg* 2016; 63: 710-714.
19. Masabni K, Raza S, Blackstone EH, Gornik HL, Sabik JF 3rd. Does preoperative carotid stenosis screening reduce perioperative stroke in patients undergoing coronary artery bypass grafting? *J Thorac Cardiovasc Surg* 2015; 149: 1253-1260.
20. Pinho-Gomes A, Sayeed R. Pre-operative Carotid artery screening in patients undergoing coronary artery bypass grafting. *J Cardiothorasc Sur* 2015; 10: A20.

21. Danaei G, Singh GM, Paciorek CJ, Lin JK, Cowan MJ, Finucane MM, et al. The global cardiovascular risk transition: associations of four metabolic risk factors with national income, urbanization, and Western diet in 1980 and 2008. *Circulation* 2013; 127: 1493-1502, e1-e8.
22. Naylor AR. Endarterectomy versus stenting for stroke prevention. *Stroke Vasc Neurol* 2018; 3: 101-106.
23. Barnett HJ, Taylor DW, Eliasziw M, Fox AJ, Ferguson GG, Haynes RB, et al. Benefit of carotid endarterectomy in patients with symptomatic moderate or severe stenosis. North American Symptomatic Carotid Endarterectomy Trial Collaborators. *N Engl J Med* 1998; 339: 1415-1425.
24. Oates CP, Naylor AR, Hartshorne T, Charles SM, Fail T, Humphries K, et al. Joint recommendations for reporting carotid ultrasound investigations in the United Kingdom. *Eur J Vasc Endovasc Surg* 2009; 37: 251-261.
25. Randomised trial of endarterectomy for recently symptomatic carotid stenosis: final results of the MRC European Carotid Surgery Trial (ECST). *Lancet* 1998; 351: 1379-1387.
26. Brott TG, Halperin JL, Abbara S, Bacharach JM, Barr JD, Bush RL, et al. 2011 ASA/ACCF/AHA/AANN/AANS/ACR/ASNR/CNS/SAIP/SCAI/SIR/SNIS/SVM/SVS guideline on the management of patients with extracranial carotid and vertebral artery disease: executive summary: a report of the American College of Cardiology Foundation/American Heart Association Task Force on Practice Guidelines, and the American Stroke Association, American Association of Neuroscience Nurses, American Association of Neurological Surgeons, American College of Radiology, American Society of Neuroradiology, Congress of Neurological Surgeons, Society of Atherosclerosis Imaging and Prevention, Society for Cardiovascular Angiography and Interventions, Society of Interventional Radiology, Society of NeuroInterventional Surgery, Society for Vascular Medicine, and Society for Vascular Surgery. Developed in collaboration with the American Academy of Neurology and Society of Cardiovascular Computed Tomography. *Catheter Cardiovasc Interv* 2013; 81: E76-E123.
27. STS. Five things physicians and patients should question [Internet]. ABIM Foundation; 2013 [Accessed 04 September 2013]. Available from: <http://www.choosingwisely.org/wp-content/uploads/2015/02/STS-Choosing-Wisely-List.pdf>

Illustrations, Figures, Photographs

All figures or photographs should be submitted in a high resolution (minimum 300 DPI) electronic version saved in jpeg or tiff format. Original hard copies of all figures may be requested when necessary. Photographs will be accepted at the discretion of the Editorial Board. All lettering, arrows, or other artwork must be done by an artist or draftsman. If arrows are used please ensure they appear in a different color to the background color, preferably black with a white border, or white with a black border. If arrows distinguish different items on the figure then different arrow styles should be used ie. long, short, wide, narrow. Written informed consent for publication must accompany any photograph in which the subject can be identified. Written copyright permission, from the publishers, must accompany any illustration that has been previously published.