

## Management of Lennox-Gastaut syndrome with deep brain stimulation: A systematic literature review

Rahaf F. Alanazi, MBBS, Ahmed M. Alkhani, MD, FRCS(C), IFAANS.

### ABSTRACT

**الأهداف:** مراجعة الأدبيات الحالية بشأن فعالية وسلامة التحفيز العميق للدماغ (DBS) في متلازمة لينوكس غاستو (LGS).

**المنهجية:** أجرى المؤلفون مراجعة منهجية لقواعد بيانات PubMed باستخدام الكلمات الرئيسية ذات صلة بهدف البحث. أجريت مراجعة للعناوين والمخلصات، واختيار الدراسات التي حققت معايير الاشتمال. أبلغنا عن النتائج وفقاً لإرشادات عناصر إعداد التقارير للمراجعات المنهجية والتحليلات التلوية (PRISMA).

**النتائج:** وجدنا 13 دراسة، و 3 دراسات فقط أفادت أن 50 مريضاً (تتراوح أعمارهم من 3 إلى 65 عاماً) حققت معايير اشتمال DBS لـ LGS. وصفنا نتائج التصوير الإشعاعي ونتائج الفسيولوجيا العصبية في جميع الدراسات. وجدنا نواة المهاد، وخاصة نواة المهاد المركزية (CMN)، لتكون نشطة للغاية في LGS. من خلال استهداف منطقة الدماغ هذه، أظهر المرضى نتائج إيجابية. بشكل عام، كان متوسط انخفاض النوبات أكثر من 50% في جميع المرضى (من بينهم 2 كانوا خاليين من النوبات) بمتوسط متابعة لمدة 15 (12-18) شهراً.

**الخلاصة:** وفقاً لهذه المراجعة المنهجية، أظهر DBS لـ LGS نتائج مرضية، مما يشير إلى أنه يجب اعتبار DBS خياراً علاجياً فعالاً. ومع ذلك، هناك حاجة إلى مزيد من الدراسات لضمان دور DBS في LGS من خلال تحديد استهداف دقيق لـ CMN عن طريق تحديد الدور الرئيسي المناسب والتصوير الإشعاعي، وتدخل DBS القياسي، والنتائج طويلة الأجل.

**Objectives:** To review the current literature regarding the efficacy and safety of deep brain stimulation (DBS) in Lennox-Gastaut syndrome (LGS).

**Methods:** The authors conducted a systematic review of PubMed databases using keywords relevant to the objective of this research. Titles and abstracts were reviewed, after which studies that met the inclusion criteria were selected. Findings were reported according to the Preferred Reporting Items for Systematic Reviews and Meta-Analyses (PRISMA) guidelines.

**Results:** Thirteen studies were identified, and only 3 studies that reported 50 patients (age range from 3 to 65 years) met the inclusion criteria of DBS for LGS. Radiological imaging findings and neurophysiological findings were described in all studies. The thalamus nuclei, particularly the centromedian thalamic nucleus (CMN), were found to be highly active in LGS. By

targeting this brain region, patients showed favorable outcomes. Overall, the mean seizure reduction was more than 50% in all patients (among whom 2 were seizure free) at a mean follow-up of 15 (12–18) months.

**Conclusion:** According to this systemic review, DBS for LGS showed satisfactory outcomes, indicating that DBS should be considered a valid treatment option. However, more studies are needed to ensure the role of DBS in LGS by establishing accurate targeting of the CMN using proper lead positioning and radiological imaging, a standard DBS intervention, and long-term outcomes.

*Neurosciences 2022; Vol. 27 (4): 216-220*  
*doi: 10.17712/nsj.2022.4.20220043*

*From the College of Medicine (Alanazi), King Saud Bin Abdulaziz University for Health Sciences, and from the Division of Neurosurgery (Alkhani), Department of Surgery, King Abdulaziz Medical City, Ministry of the National Guard-Health Affairs, Riyadh, Kingdom of Saudi Arabia.*

*Received 17th April 2022. Accepted 6th July 2022.*

*Address correspondence and reprint request to: Dr. Rahaf F. Alanazi, College of Medicine, King Saud Bin Abdulaziz University for Health Sciences, Riyadh, Kingdom of Saudi Arabia. E-mail: Alanazirfd@gmail.com ORCID ID: <https://orcid.org/0000-0003-0094-5453>*

Lennox-Gastaut syndrome (LGS) is a combination of seizure onset between 1 and 8 years of age and intellectual and behavioral disabilities. Electroencephalography (EEG) in LGS shows slow spike-and-wave discharges during the wake state and paroxysmal fast activity during sleep.<sup>1-4</sup> It has been proposed that LGS has several possible etiologies, yet it accounts for less than 2% of all forms of all epilepsies.<sup>5</sup> Seizure control in LGS is very challenging. Current literature has revealed resistance to anti-epileptic pharmacotherapy.<sup>6,7</sup> In this regard, other treatment options have been advocated.<sup>1,7,8</sup> To date, deep brain stimulation (DBS) has been an emerging treatment

option in many medication resistant epilepsy including LGS, with initial promising outcomes and reasonable complications.<sup>9</sup> The aim of this study is to review the current literature regarding the efficacy and safety of DBS in LGS.

**Methods. Search strategy.** A systematic review was conducted to investigate the efficacy and safety of DBS for LGS patients. The PubMed database was systematically searched for English-language studies from 2000 to 2022. The search terms encompassed the combination of “deep brain stimulation” and “Lennox-Gastaut syndrome”. The authors went through the results independently to assess the risk of bias. We reported the articles following the Preferred Reporting Items for Systematic Reviews and Meta-Analyses (PRISMA)<sup>10</sup> guidelines (Figure 1).

**Inclusion criteria.** The search was limited to randomized controlled trials and observational, retrospective, and follow-up studies involving only human cohorts. Studies that assessed the surgical approach, radiological findings, clinical outcomes, and quality of life of LGS patients following DBS were included. Articles of interest must report the number of patients, their demographic data, anatomical targets, and clinical outcomes.

**Exclusion criteria.** We excluded traditional review studies, articles that described other treatment modalities for the management of LGS; articles that described the use of DBS in other disorders; radiological studies that do not mention the impact of DBS in LGS patients; and studies that had replicated previous data.

**Results.** Following the search strategy detailed above, 16 articles were initially identified, and only 3 studies met our inclusion criteria with a total of 50 patients who were included in this systematic review (Table 1). Data presented from the study was done in 2007 by F. Volcano et al were reported to be from 13 selected patients even though they mentioned that their group consisted of 26 patients.<sup>11</sup> Figure 1 shows the flow diagram of the literature search process for selecting studies for the systematic review.

**Demographics, seizure onset, and EEG findings.** The prevalence of LGS was seen in 26% of female patient

(13 out of 50), male patients were 18% (9 out of 50), and the rest was not reported.<sup>11-13</sup> The mean age at presentation in the study that was done in Australia reported 25±6.3, in Korea 24.5±6.1, in Mexico only 13 out of 26 patients' data were reported in which the mean age was 13.15±5.65.<sup>11-13</sup> Seizure duration was reported in the Australian and Korean studies to have a mean of 18.70±9.74 while in the other study neither seizure onset nor duration were reported. Electroencephalography (EEG) findings from all studies reported slow spike waves (SSWs) in 70% of all patients (35/50), generalized epileptiform discharges (GEDS) accounts for 28% (24/50), 26% (13/50) were not reported.<sup>11-13</sup>

**MRI findings and seizure type.** Magnetic resonance imaging (MRI) findings showed normal brain anatomy in 34% (17/50) patients. 26% of the patients (13/50) had abnormal brain structure, 6% (3/50) had genetic abnormalities, 8% (4/50) had genetic and structural abnormalities, and 26% (13/50) were not reported.<sup>11-13</sup> Some of the reported pathologies were tuberous sclerosis, and the rest had right frontal dysgenesis, bitemporal areas of encephalomalacia, atrophy in the left hemisphere, and cerebral infarction, pachygyria, and cortical dysplasia.<sup>11-13</sup> Seizure type was reported to be 62% (31/50) Generalized tonic-clonic, 40% (20/50) tonic, 36% (18/50) atonic, 34% (17/50) atypical absence, 42% (21/50) others including focal impaired awareness seizures, myoclonic seizures, generalized tonic seizures, spasms, 26% (13/50) were not known.<sup>11-13</sup>

**Anatomical targeting and clinical outcomes.** Preoperative functional MRI (fMRI) and intraoperative EEG were used to locate the region of interest (ROI).<sup>11-13</sup> The thalamic regions showed positive connectivity for LGS Targeting the CMN in 50 patients. Seizure reduction was achieved in more than 50% in all patients among whom 2 patients were seizure free.<sup>11-13</sup> It was also reported that seizure reduction was achieved after stimulation of anterior, inferior, and lateral borders of the CMN.<sup>13</sup> In the study that was done in Australia, seizure outcomes after 3 months were measured using diaries (52% reduction), EEG (57% reduction), and diary-EEG (44% reduction), EEG and diary EEG were only reported in 17 out of 20 patients because 2 patients mandated lock-down due to COVID-19, while the other 2 studies reported long term follow up data only.<sup>11-13</sup>

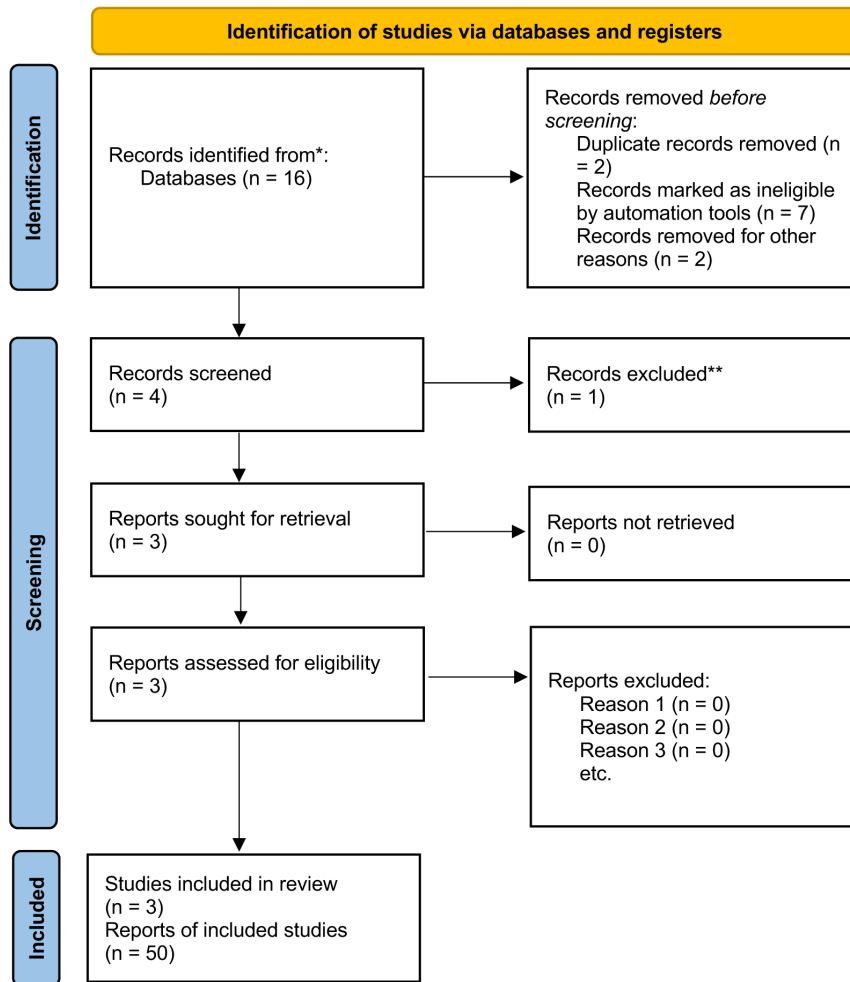
**Discussion.** Lennox-Gastaut syndrome refers to a rare and severe form of epilepsy in pediatrics. The syndrome name came after Dr. Henri Gastaut, who

**Disclosure.** Author have no conflict of interests, and the work was not supported or funded by any drug company.

**Table 1 -** Systematic literature review.

Author	Year	No. of LGS patients	Surgical approach	Outcome of interest	Reported adverse event	Seizure reduction
Aaron E.L. Warren	2022	20	Targeting CMN	Optimal target and connectivity for DBS in LGS	N=1 cerebral infection	>52%
Byung-chul Son	2016	4	Targeting CMN	Clinical outcomes and location of active contacts	N=1 Misplacement of bilateral DBS leads	30% -100%
F. Velasco	2007	26	Targeting CMN	Clinical outcomes and location of active contacts	None	53% - 100%

LGS -Lennox-Gastaut syndrome , CMN - centromedian thalamic nucleus, DBS - deep brain stimulation



**Figure 1 -** Flow diagram of the literature search process for selecting studies for the systematic review.

first described the condition in 1966 and Dr. William G. Lennox who described its electroencephalogram characteristics.<sup>14,15</sup> Approximately 75% of the cases have an underlying pathology, and for the remaining 25% no identified etiology has been known yet. Recently, genetic studies have pinpointed that mutations

in SCN1A, GABRB3, ALG13, and CHD2 genes might have a significant contribution in the disease development.<sup>16,17</sup>

In this systemic review, we extracted data from 3 separate studies that were performed in Australia, Korea, and Mexico. Overall, the main goal of the study was

determining seizure control in LGS. Although different treatment techniques are available for the management of LGS, none have been recommended as the treatment of choice due to various complications and poor outcomes.<sup>7,8</sup> In many studies including treatment of refractory epilepsy using DBS, there are limitations in data reporting the management of LGS.<sup>18</sup> Unlike in the data from the SANTE study,<sup>19</sup> patients with refractory epilepsy were not identified as classical LGS patients nor did they undergo DBS of the CMN.

The DBS is an emerging neurosurgical procedure for the treatment of different neurological disorders that affect the control of electrical impulses.<sup>20</sup> The DBS is achieved by inhibiting or decreasing nerve stimulation at the targeted sites.<sup>20</sup> The key element of DBS is to accurately target the anatomical region that is strongly associated with the pathological disorder, and through this, normal CNS networks can be adjusted.<sup>11-13</sup> To achieve this, accurate targeting of ROIs and lead placement are necessary.

Electroradiological studies were conducted to observe the activated brain regions in LGS.<sup>11-13</sup> As a result, thalamic nuclei have shown a significant association between the pathological pattern and abnormal activity of the brain.<sup>12</sup> In our systemic review, bilateral activation of CMN was increased in LGS.<sup>11-13</sup> According to the radiological findings, epilepsy is characterized by network abnormalities rather than by specific lesion or non-lesion causes.<sup>11-13</sup> In our study, 17 out of 50 had normal brain anatomy and 20 had underlying pathological diseases, and genetic mutations.<sup>11-13</sup>

Furthermore, several lines of evidence have observed that CMN plays a major role in LGS. MRI findings showed hyperintensity in regions corresponding to the landmarks of CMN during epileptic fits in LGS.<sup>11-13</sup> Additionally, recent electrophysiological studies verified widespread and diffuse electrical discharges that were generated following the activation of the CMN.<sup>11-13</sup> By targeting this area, a considerable number of positive outcomes, in terms of clinical outcome, radiological findings and QOL for LGS were found. In one of the studies, data showed 73% (19 of 26) re-incorporated into school or work.<sup>11</sup> Moreover, long term follow up was consistent with seizure reduction for more than 50%. Factors that are predictive of good outcomes were also notably similar among the patients. All groups underwent bilateral stimulation of CMN. All patients with different pathologies or who have normal brain structure had the same results.<sup>11-13</sup>

The efficacy and safety of the procedure were measured by the clinical outcomes and complications. What makes DBS a valid treatment option is that no

serious complications or worsening of the symptoms have been reported. All the patients clinically, mentally and socially improved. Even in cases with brain abnormalities, the seizure frequency was remarkably reduced.<sup>11-13</sup> Overall, these data indicate the high reliability of DBS in targeting the CMN in LGS. Identifying the CMN anatomy is crucial in predicting LGS outcomes. Further investigations in the future are important to identify the role of DBS in the management of LGS.

**Limitations.** Researches that investigate the efficacy of DBS in LGS patients are scarce. Although we identified 3 studies on the management of LGS by DBS with total of 50 cases, more studies are required before we can generalize these results. All the studies included used radiological imaging to correlate the structural connectivity with LGS in which seizure activity was noted in different parts of the brain, however in all these studies bilateral targeting of CMN showed seizure reduction more than 50%. The maximum seizure reduction was noted in inferolateral and ventrolateral of CMN, yet further studies are needed to determine the accuracy of the targeted ROI and reasons behind it. Most of the clinical outcomes were assessed by the caregiver or patient himself through diaries. More efficacious objective ways should be addressed to study the precise seizure control and long-term outcomes following DBS in LGS. Different etiologies have been described in the literature as a cause for the development of LGS. However, data from our study only reported the final outcome regardless of the underlying condition. It is important to assess the role of management of DBS in all LGS subtypes in order to achieve accurate results. This review may serve as a guide for future variable inclusion. Although nearly all the patients were presented in adulthood, the management of DBS in all age groups must be studied and reported which may highlight the importance of DBS targeting CMN as a valid option for all ages and pathologies.

**Conclusion.** This study provides evidence that DBS continues to show remarkable seizure reduction, quality of life improvement, and electrical impulse control in LGS. All patients from our literature review underwent fMRI and EEG to determine the active seizure areas, in which it was highly correlated with CMN. Patients' outcomes after DBS of CMN were satisfactory in terms of seizure reduction and clinical outcomes. DBS of all patients who had normal or abnormal brain anatomy had seizure reduction more than 50%. No life threatening complications were encountered in the follow up period of more than 2 years in most of the cases making DBS in LGS a relatively safe procedure. In order to achieve this, accurate positioning of the electrodes and visualization

of the CMN intraoperatively must be achieved. The key message is that DBS targeting CMN in LGS must be appropriately adapted to the clinical context, as it can provide the best clinical outcomes and QOL.

## References

- Asadi-Pooya A. Lennox-Gastaut syndrome: a comprehensive review. *Neurol Sci* 2017; 39: 403-414.
- Bourgeois B, Douglass L, Sankar R. Lennox-Gastaut syndrome: A consensus approach to differential diagnosis. *Epilepsia* 2014; 55: 4-9.
- Mastrangelo M. Lennox-Gastaut Syndrome: A State of the Art Review. *Neuropediatrics* 2017; 48: 143-151.
- Camfield PR. Definition and natural history of Lennox-Gastaut syndrome. *Epilepsia* 2011; 52: 3-9.
- Heiskala H. Community-Based Study of Lennox-Gastaut Syndrome. *Epilepsia* 1997; 38: 526-531.
- Verrotti A, Striano P, Iapadre G, Zagaroli L, Bonanni P, Coppola G, et al. The pharmacological management of Lennox-Gastaut syndrome and critical literature review. *Seizure* 2018; 63: 17-25.
- Jahngir M, Ahmad M, Jahangir M. Lennox-Gastaut Syndrome: In a Nutshell. *Cureus* 2018; 10: e3134.
- Rijckevorsel K. Treatment of Lennox-Gastaut syndrome: overview and recent findings. *Neuropsychiatr Dis Treat* 2008; 4: 1001-1019.
- Miocinovic S, Somayajula S, Chitnis S, Vitek J. History, Applications, and Mechanisms of Deep Brain Stimulation. *JAMA Neurol* 2013; 70: 163.
- Page MJ, McKenzie JE, Bossuyt PM, Boutron I, Hoffmann TC, Mulrow CD, et al. The PRISMA 2020 statement: an updated guideline for reporting systematic reviews. *Rev Esp Cardiol (Engl Ed)*. 2021; 74: 790-799. Erratum in: *Rev Esp Cardiol (Engl Ed)* 2022; 75: 192. PMID: 34446261.
- Velasco F, Velasco A, Velasco M, Jiménez F, Carrillo-Ruiz J, Castro G. Deep brain stimulation for treatment of the epilepsies: the centromedian thalamic target. *Acta Neurochir Suppl* 2007; 97: 337-342.
- Son B, Shon Y, Choi J, Kim J, Ha S, Kim S, et al. Clinical Outcome of Patients with Deep Brain Stimulation of the Centromedian Thalamic Nucleus for Refractory Epilepsy and Location of the Active Contacts. *Stereotact Funct Neurosurg* 2016; 94: 187-197.
- Warren AEL, Dalic LJ, Bulluss KJ, BAppSci AR, Thevathasan W, Archer JS. The Optimal Target and Connectivity for Deep Brain Stimulation in Lennox-Gastaut Syndrome. *Ann Neurol* 2022; 92: 61-74.
- Gastaut H, Tassinari CA, Roger J, Soulayrol R, Saint Jean M, Regis H, et al. [Epileptic encephalopathy in children with slow diffuse spike-waves (or petit mal variant) or Lennox syndrome]. *Recenti Prog Med* 1968; 45: 117-146. Italian
- Lennox WG, Davis JP. Clinical correlates of the fast and the slow spike-wave electroencephalogram. *Pediatrics* 1950; 5: 626-644.
- Epi4K Consortium. Epilepsy Phenome/Genome Project; Allen AS, Berkovic SF, Cossette P, Delanty N, Dlugos D, Eichler EE, et al. De novo mutations in epileptic encephalopathies. *Nature* 2013; 501: 217-221
- Lund C, Brodtkorb E, Øye AM, Røsby O, Selmer KK. CHD2 mutations in Lennox-Gastaut syndrome. *Epilepsy Behav* 2014; 33: 18-21.
- Aum DJ, Tierney T. Deep brain stimulation foundations and future trends. *Frontiers in Bioscience* 2018; 23: 162-182.
- Fisher R, Salanova V, Witt T, Worth R, Henry T, Gross R, et al; SANTE Study Group. Electrical stimulation of the anterior nucleus of thalamus for treatment of refractory epilepsy. *Epilepsia* 2010; 51: 899-908.
- Thirunavu V, Du R, Wu JY, Berg AT, Lam SK. The role of surgery in the management of Lennox-Gastaut syndrome: A systematic review and meta-analysis of the clinical evidence. *Epilepsia* 2021; 62: 888-907.