

## Non-convulsive status epilepticus in children *A report of 12 cases*

Roshan Koul, MD, DM.

---

### ABSTRACT

**Objective:** To look for pattern of non-convulsive status epilepticus in children with epilepsy at the Sultan Qaboos University Hospital, Sultanate of Oman.

**Methods:** Twelve children (6 male and 6 female) with non-convulsive status epilepticus were seen at Sultan Qaboos University Hospital from December 1992 until December 1997. The diagnosis was suspected in children with previous history of seizures who had recent change in behavior, memory, automatism or ataxia, or children presenting with unexplained ataxia, speech loss and prolonged inattention for the first time. All the patients were observed in the hospital. Electroencephalogram correlation with the above clinical presentation, of at least 30 minutes was used to confirm the diagnosis.

**Results:** Complex partial seizures status and Lennox-

Gastaut syndrome status constituted the majority (7 cases). Intravenous midazolam and phenytoin sodium were used to control status in 9 cases. On follow-up, 5 were adequately controlled, while 6 had recurrence. One patient was lost to follow-up.

**Conclusion:** Non-convulsive status epilepticus should be suspected in children with recent onset change in speech, memory, school performance, unexplained ataxia and particularly in children with epilepsy who undergo an otherwise inexplicable change in behavior.

**Keywords:** Status epilepticus, non-convulsive, children, midazolam, follow-up.

Neurosciences 2000; Vol. 5 (1): 13-17

---

Status epilepticus is "a condition characterised by an epileptic seizure" that is so frequently repeated or so prolonged, as to create a fixed and lasting condition.<sup>1</sup> A more substantive definition is continuous seizures lasting for 30 minutes or longer or recurrent seizures occurring with impairment of consciousness between seizure activity.<sup>2</sup> Status epilepticus may be of convulsive or non-convulsive type. The former is obvious, while the latter is usually missed. There are only few reports of non-convulsive status epilepticus (NCSE) in children. An estimated 25 % of patients who experience status epilepticus have NCSE.<sup>3</sup> The actual proportion may be much higher because of patients not being identified.<sup>4,5</sup>

Methods. Twelve children with NCSE seen at Sultan Qaboos University Hospital from December 1992 until December 1997 formed the subjects of this prospective study. The diagnosis was suspected in children with a previous history of seizures who had recent change in behavior, memory, automatism or ataxia. Also included, were children presenting with unexplained ataxia, speech loss and prolonged inattention for the first time. All the patients were observed in the hospital. Electroencephalogram (EEG) correlation with the above clinical presentation, of at least 30 minutes was used to confirm the diagnosis. Electroencephalogram features of prolonged synchronous 3Hz spike and

---

From the Department of Child Health, Sultan Qaboos University Hospital, Al Khod, Sultanate of Oman.

Received 23rd November 1998. Accepted for publication in final form 25th May 1999.

Address correspondence and reprint request to: Dr. Roshan Koul, Consultant Pediatric Neurologist, Department of Child Health, PO Box 38, Al Khod 123, Sultanate of Oman. Tel. 00 968 515 745. Fax. 00 968 513 009.

Table 1 - Showing details of non-convulsive status epilepticus patients.

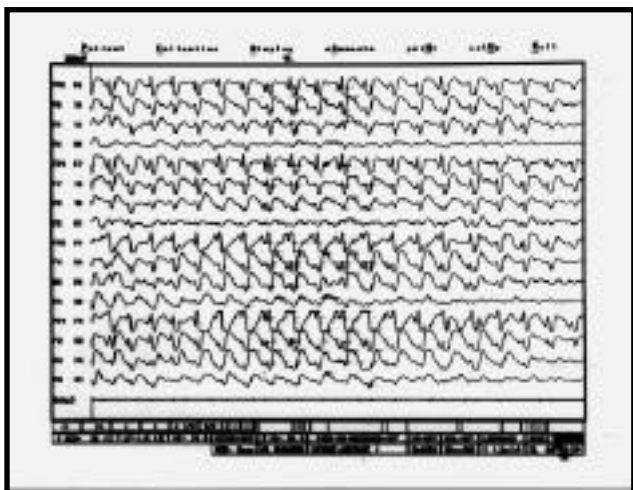
Number	1	2	3	4	5	6	7	8	9	10	11	12
Sex	F	M	M	F	F	M	M	M	F	F	M	F
Age in years/months (m)	9	8	4	6	3, 9m	8	9	3, 4m	7	11	2, 8m	6
Age of onset of seizures	2	10m	2	3	4m	3	8	2	5	3	1, 6m	3, 6m
Type of seizure before NCSE	CPS	GTC TC SE	TC Myoclonic	-	TC	-	-	TC Myoclonus TC SE	Myoclonic TC	TC CPS	TC MA	TC Myoclonic
Associated symptoms/deficit	-	-	M Regression	Ataxia	MR LH	Delayed milestone	PSP	Ataxia	MR	Aphasia	Ataxia Aphasia	Ataxia Aphasia
CT/MRI	N/N	N/-	CA/-	N/-	Arachnoid- do-cyst (R)	MCH	N/N	N/-	N/-	N/-	N/N	N/N
EEG	CPSE	CPSE	LGSE	Absence status	ESES	CPSE	CPSE	MAE	LGSE	LK	BS (LGSE)	MAE
Other investigations	Met -ve	Met -ve	Met -ve	-	-	-	-	Met -ve	GSD	-	Met -ve	Met -ve
Status controlled	MDZ DPH	DPH	MDZ DPH	MDZ	VPA	VPA	VPA	MDZ DPH	MDZ DPH	MDZ DPH	MDZ DPH	MDZ DPH
Outcome	Good	Poor	Poor	Good	No-follow up	Good	Good	Good	Poor	Poor	Poor	Poor
AEDs	LTG	VPA+ DPH+ PHB	DPH+ VPA+ CLZ	VPA	VPA	VPA	VPA	VPA+ LTG+ ACTH	LTG DPH CLZ	VPA CBZ	VGB LTG VPA	LTG VPA

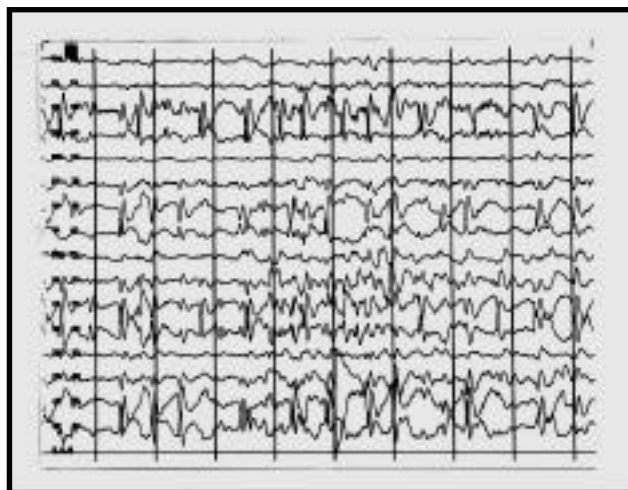CPS = complex partial seizures	DPH = phenytoin sodium
TC = tonic clonic	VPA = valproate sodium
GTC = generalized tonic clonic	PHB = phenobarbitone
M = mental	CLZ = clonazepam
N = normal	LTG = lamotrigine
AEDs = anti-epileptic drugs	CBZ = carbamazepine
SE = status epilepticus	MDZ = midazolam
Met = metabolic	PSP = poor school performance
MCH = mild communicating hydrocephalus	GSD = glycogen storage disease
LK = Landau Kleffner	BS = burst suppression
MA = myoclonic astatic	CA = cerebellar atrophy
LH = left hemiparesis	R = retardation

slow wave, predominant in anterior head regions confirmed absence status.<sup>3</sup> In complex partial status epilepticus (CPSE), the ictal changes included continuous spike and slow wave complexes, irregular sharp or slow waves or polyspike discharges on single or both temporal regions. Such features over extra-temporal regions have also been reported.<sup>3,6</sup> In Lennox-Gastaut syndrome (LGS) status, EEG changes of continuous or asynchronous 1.5 - 2 Hz spike and slow wave discharges with background slowing were used to settle the diagnosis. The continuous generalised spike and wave discharges during entire slow sleep established electrical status epilepticus of sleep (ESES). Continuous 2 -3 Hz spike and wave, polyspike complexes in altered mental state and head myoclonus were diagnostic of myoclonic astatic epilepsy of Doose.<sup>7</sup> Diffuse and multifocal spike and wave discharges during the entire EEG recording period of 30 minutes in a previously diagnosed case of Landau-Kleffner

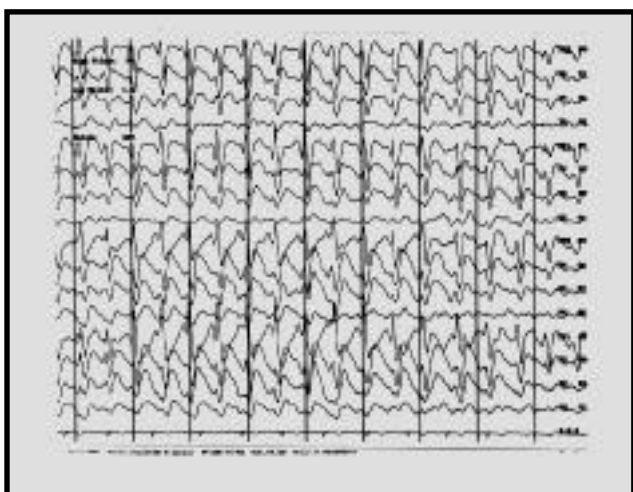
syndrome (LKS), proved the diagnosis of LKS status. A complete hematological profile, liver and renal functions, metabolic screening for lipids, carbohydrates and amino acid abnormalities were done in all cases. Computer tomography (CT) scan of the brain was done in all children while four had magnetic resonance imaging (MRI) scans also. Liver biopsy was done in another child with hepatomegaly who presented with tonic-clonic and myoclonic seizures along with hypoglycemia. This child was subsequently confirmed to have glycogen storage disease Type IA. The patients were randomly picked up for different modes of therapy. Intravenous midazolam (MDZ) and phenytoin sodium (DPH) were used to control NCSE in nine cases. Seven had simultaneous infusion of both, while one each was given DPH and MDZ alone, in addition to other oral anti-epileptic drugs (AEDs). Midazolam was used following excellent recent reports of its efficacy in status epilepticus.<sup>8-11</sup> It also has a short half-life



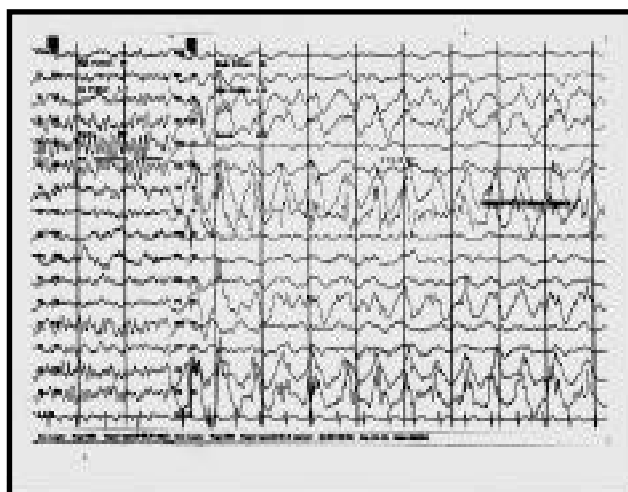
**Figure 1** - Showing features of absence status in the form of continuous 3Hz spike and waves, predominant in anterior leads.



**Figure 2** - Showing spikes and spike wave discharges over temporal and parietal regions in CPSE



**Figure 3** - Showing continuous generalized slow spike wave discharges in a child with Lennox-Gastaut status.



**Figure 4** - A child with ESES, showing normal awake EEG on left and continuous bilateral synchronous spike and wave complexes in sleep.

resulting in less sedation and the child becoming active within hours of cessation of the drug. The remaining three cases were given oral AEDs. Intravenous MDZ was given as bolus 0.15 mg/kg followed by increments of 1-5 mcg/kg/minute twice hourly till cessation of seizures for 24 hrs. Then it was reduced twice hourly, decreasing by 0.25 mcg/kg/minute. Phenobarbitone (PHB) and paraldehyde were not used in any case. The patients were maintained on different AEDs (single or combination) according to the type of seizures (Table 1). All these children were followed up regularly in the pediatric neurology clinic. A seizure free period of 6 months was considered adequate control.

**Results.** Twelve children (6 males and 6 females) with NCSE were seen in the last 5 years at the University Hospital. Age at presentation ranged from 2 years to 11 years with a mean age of 7 years 3

months. The age, at onset of seizures was 4 months to 8 years with a mean of 2 years 10 months. Seven cases had different types of seizures before presenting as NCSE and two of these had previous episodes of tonic-clonic status. Three cases presented as only NCSE for the first time. Case 4 had ataxia, urinary incontinence, poor speech and infrequent blinking. Case 5 had delayed development. Case 7 had poor school performance and forgetfulness of recent onset. Intravenous MDZ and DPH were used to control NCSE in nine cases while in the remaining, oral sodium valproate was used. Intravenous MDZ was used alone in the patient with absence status epilepticus with oral sodium valproate. It was given for 24 hrs and tapered subsequently. In 2 cases of CPSE, 3 of Lennox Gastaut status epilepticus (LGSE) and one patient of myoclonic astatic epilepsy of Doose, MDZ was given when DPH infusion failed to control

fragmentary seizures like automatism, abnormal behaviour and myoclonic jerks. Phenytoin sodium alone, controlled CPSE in one case. In most of the patients, MDZ was used for about 24 hours, however in two patients, it was given for about one week. When dose reduction of MDZ was attempted after 24 hours and 72 hours, fragmentary seizures recurred in those two cases. Computerized tomography and MRI were abnormal in only three cases. Five children had recurrent NCSE, in three, it was controlled subsequently. One child was lost to follow up and two had recurrent cluster of brief seizures.

**Discussion.** Non-convulsive status epilepticus is uncommon in pediatric age group with the majority of the cases reported to be over 10 years of age.<sup>6,12,13</sup> About 25 % of cases of status epilepticus (SE) are NCSE.<sup>3,4</sup> Most of the reports show a predominance of absence SE.<sup>4,13</sup> Only one patient with absence SE was seen in this report. This patient presented with absence status at onset with features of staring, urinary incontinence and loss of speech (Figure 1). Absence status is seen mostly in patients with primary or secondarily generalised seizure disorder<sup>2</sup> and occurs in 3 % of all patients who have absence seizures.<sup>12</sup> It was seen in 6% of cases in a series by Stores.<sup>5</sup> Absence status was first observed by Lennox-Gastaut.<sup>14</sup> Other different names have been used for this condition like spike wave stupor, petit mal status, prolonged petit mal automatism and *epilepsia minoris continua*. The hallmark of this disorder is a prolonged confusional state of variable duration associated with EEG changes. Patients may continue to function normally during absence SE except that they would be less alert with lack of coordination. Rhythmic blinking, staring, clonic twitching, automatisms, occasional myoclonic jerks of limbs and paucity of speech may also be evident. The duration of seizure activity may last from thirty minutes to two days.<sup>15</sup> Electroencephalogram establishes the diagnosis in the form of 3 Hz spike and slow wave complexes, synchronous and maximal in anterior head regions. The first case of CPSE was described by Gastaut and Roger in 1956.<sup>16</sup> Other terms that have been used to describe this include temporal SE and psychomotor SE. The characteristic manifestations are automatism, mild motor phenomena, bizarre behavior, aphasia, ictal paresis, amnesia and variable responsiveness. The EEG changes include spike and slow wave complexes, polyspike discharges, irregular sharp or slow waves or rhythmical slowing. These changes may be localised or generalised. Two types of CPSE are recognised. Type I is recurrent CPS with focal EEG changes,<sup>15</sup> and Type II is a continuous CPS activity with partial or secondarily generalised ictal EEG abnormality. In most cases, CPSE develops in a patient with partial seizure disorder without an obvious precipitating factor or a potential precipitating factor like infection, drug withdrawal or

inadequate AED levels. Patients may also develop CPSE *denovo* without antecedent history of seizures. This occurs mostly in adults with cerebral infarction and herpes simplex encephalitis. Ictal behaviour of CPSE may be difficult to differentiate from absence SE. Focal EEG changes, previous history of seizures and the clinical setting will help in differentiating the two. Complex partial status epilepticus is usually reported in adults but can occur at any age.<sup>6</sup> Other conditions which need to be differentiated are metabolic encephalopathies, periodic lateralised epileptiform discharges, migraine, psychosis and somatiform disorders. There are only few reports of CPSE in children, the condition being commoner in the adult population. About 15% of cases of chronic complex partial seizures have CPSE. Four children had CPSE in this study (Figure 2). All of them presented around 9 years of age. Two of the cases had onset of seizures under 2 years of age. One child had poor school performance and forgetfulness at the time of presentation, while the other had delayed development. Lennox-Gastaut syndrome status is a common form of NCSE seen in children. It constituted 36% of cases in the largest reported series.<sup>5</sup> This type of NCSE occurs in age group 1-5 years. There are myoclonic, tonic, tonic-clonic and absence seizures in various permutations and combinations. Altered mentation and twitchings of the face may be present. These children are usually mentally retarded. Electroencephalogram shows high amplitude 2-3 Hz slow spike wave complexes which are irregular and generalised. Three patients with LGSE were seen in our series (Figure 3). Myoclonic-astatic epilepsy status of Doose was seen in two cases, though reported to be another major group of NCSE in children.<sup>5,7</sup> This develops in the age group 1-5 years in neurologically normal children. These children experience myoclonic-astatic attacks, tonic fits and ataxia. Adequate seizure control in one patient was achieved with ACTH and lamotrigine and Lamotrigine and sodium valproate in another. Landau-Kleffner disease is characterised by seizures (partial or generalised), aphasia and multifocal seizure discharges on EEG, the usual age group being 3-15 years.<sup>17</sup> The seizures may subside by 10-15 years of age. This status was seen in an already diagnosed case who showed frequent partial seizures, gait ataxia and confusional state for several hours. One child presented with delayed development. The EEG revealed ESES (Figure 4). This syndrome was first observed by Patry et al in 1971.<sup>18</sup> It is characterised by seizures, continuous nocturnal generalised spike and wave complexes and progressive neurocognitive decline beginning in childhood, usual age group being 8 months to 11 years. The seizures are partial motor, atypical absences or generalised tonic clonic. Electroencephalogram is characteristic in such cases. There are continuous bilaterally synchronous spike and wave complexes that occupied at least 85% of

slow sleep. During rapid eye movement sleep and awake state, focal epileptiform discharges or fragmented generalised discharges are seen. Tassinari et al<sup>19</sup> described in detail the clinical course of 18 patients with this disorder. Non-convulsive status epilepticus usually develops in patients, previously diagnosed as epilepsy.<sup>5</sup> Seven of our patients had the diagnosis of epilepsy and were on AEDs. Trauma, infection and tumors were not associated in any case. Neurometabolic disorder may be in some cases (one case of glycogen storage disease was seen in this report). Two patients had NCSE following drug withdrawal. Four children had mental retardation. Gait ataxia is an uncommon mode of presentation.<sup>20</sup> Two cases presented with gait ataxia as the dominant feature of NCSE; one of them had absence SE and the other myoclonic astatic SE. There are different views on management of NCSE.<sup>4,6</sup> Oral or intravenous AEDs are recommended in absence SE depending upon the clinical severity and the location of treatment. Absence SE however is not a life threatening disorder and the potential of neurological morbidity is not known.<sup>2</sup> Aggressive management of CPSE is recommended to terminate clinical & EEG seizure activity.<sup>4,5</sup> Evidence of brain damage by continuous seizure activity in CPSE has been reported.<sup>21-22</sup> Nine of our cases received IV medication. Seven had simultaneous intravenous MDZ and DPH. One case received intravenous MDZ and oral sodium valproate while another had intravenous DPH in addition to oral valproate sodium (VPA) and PHB. Several recent reports have shown intravenous MDZ as highly effective in controlling status epilepticus in children who remained in status despite adequate doses of diazepam, DPH & PHB.<sup>8-11</sup> Eleven cases were followed up in this hospital over the last 5 years. Five had adequate control while in six the control was poor. They were admitted with recurrent NCSE. It is not uncommon to see such patients with recurrent attacks.<sup>5</sup> (One was lost to follow up). Non-convulsive status epilepticus is uncommon in children under 10 years of age. This should be suspected in children with recent onset change in speech, memory, school performance, unexplained ataxia and particularly in children with epilepsy who undergo an otherwise inexplicable change in behaviour.<sup>5</sup> The decision to treat aggressively (intravenous medication) or oral AEDs should be individualised, though clinical and experimental evidence suggests memory and behavioural alteration following NCSE.

**Acknowledgement.** The author acknowledges Mr Gerald Joshua, EEG Technologist for his help, Department of Photograpy and Ms Ruth Tamisen Mujal for the secretarial work.

## References

1. Gastaut H. Classification of status epilepticus in : Delgado-Escueta AV, Wasterlain CG, Treiman DM, Porter RJ eds. Status epilepticus. New York: Raven Press. Advances in Neurology 1983; 34: 15-35.
2. Engel JE Jr. Status Epilepticus in : Engel JE Jr. ed Seizures & epilepsy. Philadelphia: FA Davis, 1989: 256-80.
3. Celesia CG. Modern concepts of status epilepticus. JAMA 1976; 235: 1571-4.
4. Cascino GD. Non convulsive status epilepticus in adults and children. Epilepsia 1993; 34 (Suppl) 1: 521-28.
5. Stores G, Zaiwalla Z, Styles E, Hoshika A. Non-convulsive status epilepticus. Arch Dis Child 1995; 73: 106-111.
6. Cockerell OC, Walker MC, Sander JW AS, Shorovon SD. Complex partial status epilepticus a recurrent problem. J Neurol Neurosurg Psychiatry 1994; 57: 835-837.
7. Doose H. Myoclonic astatic epilepsy of early childhood. In Roger J, Dravet C, Bureau M, Dreifuss FE, Wolf P eds. Epileptic syndromes in infancy, childhood and adolescence. London: Libbey 1985; 78-88.
8. Kumar A, Bleck TP. Intravenous midazolam for the treatment of refractory status epilepticus. Crit Care Med 1992; 20: 483-488.
9. Bleck PT. Advances in the management of refractory status epilepticus. Crit Care Med 1993; 21(7): 955-957.
10. Rivera R, Segnini M, Baltodano A, Perez V. Midazolam in the treatment of status epilepticus in children. Crit Care Med 1993; 21(7): 991-994.
11. Koul RL, Aithala GR, Chacko A, Joshi R, Elbualy MS. Continuous midazolam infusion as treatment of status epilepticus. Arch Dis Child 1997; 76: 445-448.
12. Hauser WA. Status epilepticus: frequency, etiology and neurological sequelae. in: Delgado-Escueta AV, Wasterlain CG, Treiman DM, Porter RJ eds. Status epilepticus New York: Raven Press. Advances in Neurology 1983; 34: 3-14.
13. Porter RJ, Penry JK. Petitmal status in : Delgado-Escueta AV, Wasterlain CG, Treiman DM, Porter RJ eds. Status epilepticus, New York, Raven Press. Advances in Neurology 1983; 34: 61-7.
14. Lennox WG. The petit mal epilepsies - their treatment with tridione. JAMA 1945 b; 129: 1069-1073.
15. Andermann F, Robb JP. Absence status. A reappraisal following review of 38 patients. Epilepsia 1972; 13: 177-187.
16. Gastaut H, Roger A. Sur de mal temporal. Rev Neurol. 1956; 94: 298-301.
17. Ballaban Gil K. Language disorders and epilepsy. in: Recent advances in Epilepsy. No 6 Edit. TA Pedley & B.S Meldrum, Churchill Livingstone 1995: 205-220.
18. Patry G, Lyagonbi S, Tassinari CA. Subclinical electrical status epilepticus induced by sleep in children. Arch Neurol 1971; 24: 242--52.
19. Tassinari CA, Bureau M, Dravet C, Dalla Bernadina B, Roger J. Epilepsy with continuous spikes & waves during slow sleep. In Roger J, Dravet C, Bureau M, Freefussa FE, Wolf P eds. Epileptic syndromes in infancy, childhood and adolescence. London; Libbey 1985: 194-204.
20. Fenichel GM. In clinical pediatric neurology. A sign and symptoms approach. WB Saunders company. Harcourt Brace, Javanovich, Inc. Philadelphia, 1994 2nd edition chapter 10: 223-247.
21. Treiman DM, Delgado-Escueta AV. Impairment of memory following prolonged complex partial status epilepticus. Neurology 1981; 31:109.
22. Engel JE Jr, Ludwig BI, Fetell M. Prolonged partial complex status epilepticus. EEG & behavioural observation. Neurology 1978; 28: 863-9.